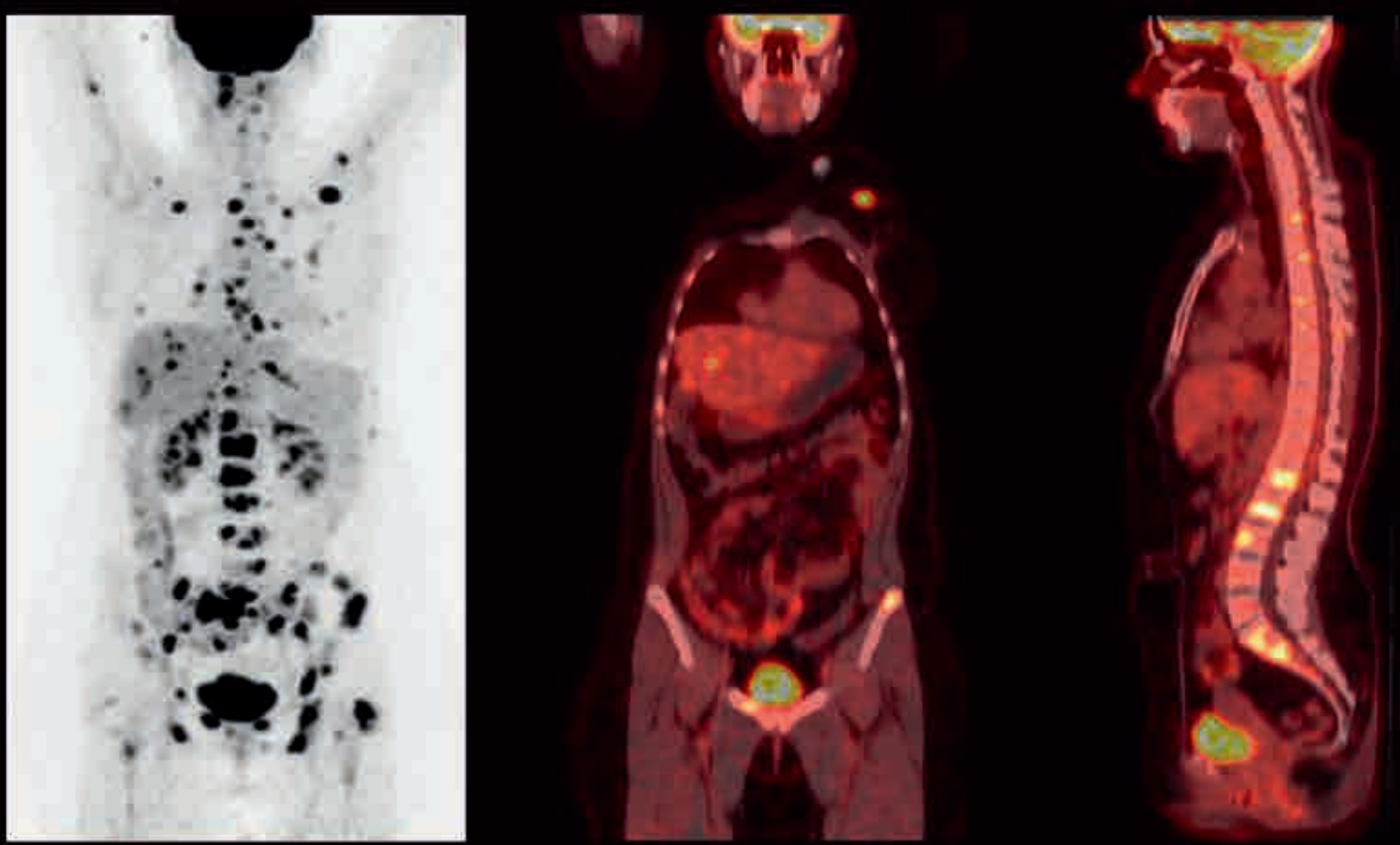

IAEA HUMAN HEALTH SERIES

No. 32

Clinical PET/CT Atlas: A Casebook of Imaging in Oncology



IAEA

International Atomic Energy Agency

IAEA HUMAN HEALTH SERIES PUBLICATIONS

The mandate of the IAEA human health programme originates from Article II of its Statute, which states that the “Agency shall seek to accelerate and enlarge the contribution of atomic energy to peace, health and prosperity throughout the world”. The main objective of the human health programme is to enhance the capabilities of IAEA Member States in addressing issues related to the prevention, diagnosis and treatment of health problems through the development and application of nuclear techniques, within a framework of quality assurance.

Publications in the IAEA Human Health Series provide information in the areas of: radiation medicine, including diagnostic radiology, diagnostic and therapeutic nuclear medicine, and radiation therapy; dosimetry and medical radiation physics; and stable isotope techniques and other nuclear applications in nutrition. The publications have a broad readership and are aimed at medical practitioners, researchers and other professionals. International experts assist the IAEA Secretariat in drafting and reviewing these publications. Some of the publications in this series may also be endorsed or co-sponsored by international organizations and professional societies active in the relevant fields.

There are two categories of publications in this series:

IAEA HUMAN HEALTH SERIES

Publications in this category present analyses or provide information of an advisory nature, for example guidelines, codes and standards of practice, and quality assurance manuals. Monographs and high level educational material, such as graduate texts, are also published in this series.

IAEA HUMAN HEALTH REPORTS

Human Health Reports complement information published in the IAEA Human Health Series in areas of radiation medicine, dosimetry and medical radiation physics, and nutrition. These publications include reports of technical meetings, the results of IAEA coordinated research projects, interim reports on IAEA projects, and educational material compiled for IAEA training courses dealing with human health related subjects. In some cases, these reports may provide supporting material relating to publications issued in the IAEA Human Health Series.

All of these publications can be downloaded cost free from the IAEA web site:

<http://www.iaea.org/Publications/index.html>

Further information is available from:

Marketing and Sales Unit
International Atomic Energy Agency
Vienna International Centre
PO Box 100
1400 Vienna, Austria

Readers are invited to provide their impressions on these publications. Information may be provided via the IAEA web site, by mail at the address given above, or by email to:

Official.Mail@iaea.org.

CLINICAL PET/CT ATLAS:
A CASEBOOK OF IMAGING
IN ONCOLOGY

The following States are Members of the International Atomic Energy Agency:

AFGHANISTAN	GERMANY	OMAN
ALBANIA	GHANA	PAKISTAN
ALGERIA	GREECE	PALAU
ANGOLA	GUATEMALA	PANAMA
ARGENTINA	GUYANA	PAPUA NEW GUINEA
ARMENIA	HAITI	PARAGUAY
AUSTRALIA	HOLY SEE	PERU
AUSTRIA	HONDURAS	PHILIPPINES
AZERBAIJAN	HUNGARY	POLAND
BAHAMAS	ICELAND	PORTUGAL
BAHRAIN	INDIA	QATAR
BANGLADESH	INDONESIA	REPUBLIC OF MOLDOVA
BELARUS	IRAN, ISLAMIC REPUBLIC OF	ROMANIA
BELGIUM	IRAQ	RUSSIAN FEDERATION
BELIZE	IRELAND	RWANDA
BENIN	ISRAEL	SAN MARINO
BOLIVIA, PLURINATIONAL STATE OF	ITALY	SAUDI ARABIA
BOSNIA AND HERZEGOVINA	JAMAICA	SENEGAL
BOTSWANA	JAPAN	SERBIA
BRAZIL	JORDAN	SEYCHELLES
BRUNEI DARUSSALAM	KAZAKHSTAN	SIERRA LEONE
BULGARIA	KENYA	SINGAPORE
BURKINA FASO	KOREA, REPUBLIC OF	SLOVAKIA
BURUNDI	KUWAIT	SLOVENIA
CAMBODIA	KYRGYZSTAN	SOUTH AFRICA
CAMEROON	LAO PEOPLE'S DEMOCRATIC REPUBLIC	SPAIN
CANADA	LATVIA	SRI LANKA
CENTRAL AFRICAN REPUBLIC	LEBANON	SUDAN
CHAD	LESOTHO	SWAZILAND
CHILE	LIBERIA	SWEDEN
CHINA	LIBYA	SWITZERLAND
COLOMBIA	LIECHTENSTEIN	SYRIAN ARAB REPUBLIC
CONGO	LITHUANIA	TAJIKISTAN
COSTA RICA	LUXEMBOURG	THAILAND
CÔTE D'IVOIRE	MADAGASCAR	THE FORMER YUGOSLAV REPUBLIC OF MACEDONIA
CROATIA	MALAWI	TOGO
CUBA	MALAYSIA	TRINIDAD AND TOBAGO
CYPRUS	MALI	TUNISIA
CZECH REPUBLIC	MALTA	TURKEY
DEMOCRATIC REPUBLIC OF THE CONGO	MARSHALL ISLANDS	UGANDA
DENMARK	MAURITANIA	UKRAINE
DJIBOUTI	MAURITIUS	UNITED ARAB EMIRATES
DOMINICA	MEXICO	UNITED KINGDOM OF GREAT BRITAIN AND NORTHERN IRELAND
DOMINICAN REPUBLIC	MONACO	UNITED REPUBLIC OF TANZANIA
ECUADOR	MONGOLIA	UNITED STATES OF AMERICA
EGYPT	MONTENEGRO	URUGUAY
EL SALVADOR	MOROCCO	UZBEKISTAN
ERITREA	MOZAMBIQUE	VENEZUELA, BOLIVARIAN REPUBLIC OF
ESTONIA	MYANMAR	VIET NAM
ETHIOPIA	NAMIBIA	YEMEN
FIJI	NEPAL	ZAMBIA
FINLAND	NETHERLANDS	ZIMBABWE
FRANCE	NEW ZEALAND	
GABON	NICARAGUA	
GEORGIA	NIGER	
	NIGERIA	
	NORWAY	

The Agency's Statute was approved on 23 October 1956 by the Conference on the Statute of the IAEA held at United Nations Headquarters, New York; it entered into force on 29 July 1957. The Headquarters of the Agency are situated in Vienna. Its principal objective is "to accelerate and enlarge the contribution of atomic energy to peace, health and prosperity throughout the world".

IAEA HUMAN HEALTH SERIES No. 32

CLINICAL PET/CT ATLAS:
A CASEBOOK OF IMAGING
IN ONCOLOGY

INTERNATIONAL ATOMIC ENERGY AGENCY
VIENNA, 2015

COPYRIGHT NOTICE

All IAEA scientific and technical publications are protected by the terms of the Universal Copyright Convention as adopted in 1952 (Berne) and as revised in 1972 (Paris). The copyright has since been extended by the World Intellectual Property Organization (Geneva) to include electronic and virtual intellectual property. Permission to use whole or parts of texts contained in IAEA publications in printed or electronic form must be obtained and is usually subject to royalty agreements. Proposals for non-commercial reproductions and translations are welcomed and considered on a case-by-case basis. Enquiries should be addressed to the IAEA Publishing Section at:

Marketing and Sales Unit, Publishing Section
International Atomic Energy Agency
Vienna International Centre
PO Box 100
1400 Vienna, Austria
fax: +43 1 2600 29302
tel.: +43 1 2600 22417
email: sales.publications@iaea.org
<http://www.iaea.org/books>

© IAEA, 2015

Printed by the IAEA in Austria

June 2015

STI/PUB/1680

IAEA Library Cataloguing in Publication Data

Clinical PET/CT atlas : a casebook of imaging in oncology. — Vienna : International Atomic Energy Agency, 2015.

p. ; 30 cm. — (IAEA human health series, ISSN 2075-3772 ; no. 32)

STI/PUB/1680

ISBN 978-92-0-101115-2

Includes bibliographical references.

1. Tomography, Emission — Atlases. 2. Tomography — Atlases. 3. Cancer — Radionuclide imaging. I. International Atomic Energy Agency. II. Series.

IAEAL

15-00963

FOREWORD

Integrated positron emission tomography and computed tomography (PET/CT) has evolved since its introduction into the commercial market in 2001 into a major imaging procedure, particularly in oncological imaging. In clinical routine service, PET/CT has shown a significant impact on diagnosis, staging, treatment planning and the monitoring of treatment response, and has played an important role in the care of cancer patients. The unique characteristics that combine the high sensitivity from the PET component and the specificity of the CT component make PET/CT one of the fastest growing imaging modalities even 14 years after its clinical introduction.

The main tracer currently used is still ^{18}F -fluorodeoxyglucose (FDG), which has been used since 1976 in PET only imaging prior to the introduction of PET/CT. Although a rather unspecific tracer concerning the uptake mechanism, there is an increasing amount of literature that supports the importance, accuracy and reliability of the tracer for various oncological indications. Improved accuracy in primary diagnosis, staging and restaging, and impact on patient management has been documented for a variety of cancers, including head and neck, thyroid, lung, breast, oesophageal, colorectal, lymphoma, sarcoma, gastrointestinal stromal tumour, liver and gallbladder tumours, pancreatic cancer, cancer of unknown primary and melanoma. In those studies, the improvement of PET/CT over conventional staging is in the range of 5–25%, depending on the primary cancer entity.

For cancers which do not have tracer uptake mechanisms suitable for FDG imaging, more specific tracers have been recently introduced clinically. Such examples include ^{18}F -choline (^{11}C -choline is also an option) for recurrent prostate cancer as well as ^{18}F -DOPA and ^{68}Ga -DOTA (TOC/NOC/TATE) for neuroendocrine tumours, to name a few. There is also an ever increasing body of research tracers discussed in scientific literature.

This PET/CT atlas combines nearly one hundred comprehensive cases covering all major indications of FDG–PET/CT as well as some cases of clinically relevant special tracers. The cases provide an overview of what the specific disease can look like in PET/CT, the typical pattern of the disease's spread, as well as common pitfalls and teaching points.

Previous publications in the IAEA Human Health Series have provided information on the appropriate use of FDG–PET/CT, standard operating procedures for PET/CT and how to establish a PET centre, as well as different quality assurance programmes and diagnostic imaging topics with other imaging modalities. This PET/CT atlas will be of help to all professionals working with and interested in PET/CT imaging. It contains a variety of oncological images and provides clinically relevant teaching files on the effectiveness and diagnostic quality of FDG–PET/CT imaging in routine applications. The IAEA officers responsible for this publication were D. Paez and R. Nuñez Miller of the Division of Human Health.

EDITORIAL NOTE

This publication has been edited by the editorial staff of the IAEA to the extent considered necessary for the reader's assistance. It does not address questions of responsibility, legal or otherwise, for acts or omissions on the part of any person.

Although great care has been taken to maintain the accuracy of information contained in this publication, neither the IAEA nor its Member States assume any responsibility for consequences which may arise from its use.

The use of particular designations of countries or territories does not imply any judgement by the publisher, the IAEA, as to the legal status of such countries or territories, of their authorities and institutions or of the delimitation of their boundaries.

The mention of names of specific companies or products (whether or not indicated as registered) does not imply any intention to infringe proprietary rights, nor should it be construed as an endorsement or recommendation on the part of the IAEA.

The IAEA has no responsibility for the persistence or accuracy of URLs for external or third party Internet web sites referred to in this publication and does not guarantee that any content on such web sites is, or will remain, accurate or appropriate.

CONTENTS

1.	INTRODUCTION	1
1.1.	Background	1
1.2.	Scope	1
1.3.	Objective	1
1.4.	Structure	1
2.	HEAD AND NECK	2
2.1.	Case No. H&N 1	2
2.2.	Case No. H&N 2	4
2.3.	Case No. H&N 3	6
2.4.	Case No. H&N 4	8
2.5.	Case No. H&N 5	10
2.6.	Case No. H&N 6	12
2.7.	Case No. H&N 7	14
3.	HEAD AND NECK: THYROID	16
3.1.	Case No. H&N THY 1	16
3.2.	Case No. H&N THY 2	18
4.	CANCER OF UNKNOWN PRIMARY	20
4.1.	Case No. CUP 1	20
4.2.	Case No. CUP 2	22
4.3.	Case No. CUP 3	24
5.	THORAX: BREAST	26
5.1.	Case No. TH BR 1	26
5.2.	Case No. TH BR 2	28
5.3.	Case No. TH BR 3	30
5.4.	Case No. TH BR 4	32
5.5.	Case No. TH BR 5	34
5.6.	Case No. TH BR 6	36
5.7.	Case No. TH BR 7	38
5.8.	Case No. TH BR 8	40
5.9.	Case No. TH BR 9	42
5.10.	Case No. TH BR 10	44
6.	THORAX: LUNG	46
6.1.	Case No. TH LU 1	46
6.2.	Case No. TH LU 2	48
6.3.	Case No. TH LU 3	50
6.4.	Case No. TH LU 4	52
6.5.	Case No. TH LU 5	54
6.6.	Case No. TH LU 6	56
6.7.	Case No. TH LU 7	58

6.8. Case No. TH LU 8.....	60
6.9. Case No. TH LU 9.....	62
6.10. Case No. TH LU 10.....	64
7. THORAX: MESOTHELIOMA.....	66
7.1. Case No. TH MES 1.....	66
7.2. Case No. TH MES 2.....	68
8. GASTROINTESTINAL TRACT: OESOPHAGUS.....	70
8.1. Case No. GI OES 1.....	70
8.2. Case No. GI OES 2.....	72
8.3. Case No. GI OES 3.....	74
8.4. Case No. GI OES 4.....	76
9. GASTROINTESTINAL TRACT: LIVER.....	78
9.1. Case No. GI LIV 1.....	78
9.2. Case No. GI LIV 2.....	80
9.3. Case No. GI LIV 3.....	82
10. GASTROINTESTINAL TRACT: PANCREAS.....	84
10.1. Case No. GI PANC 1.....	84
10.2. Case No. GI PANC 2.....	86
10.3. Case No. GI PANC 3.....	88
11. GASTROINTESTINAL TRACT: COLON.....	90
11.1. Case No. GI CO 1.....	90
11.2. Case No. GI CO 2.....	92
11.3. Case No. GI CO 3.....	94
11.4. Case No. GI CO 4.....	96
11.5. Case No. GI CO 5.....	98
11.6. Case No. GI CO 6.....	100
11.7. Case No. GI CO 7.....	102
11.8. Case No. GI CO 8.....	104
11.9. Case No. GI CO 9.....	106
12. GASTROINTESTINAL TRACT: GASTROINTESTINAL STROMAL TUMOUR.....	108
12.1. Case No. GI GIST 1.....	108
13. PELVIS: OVARY.....	110
13.1. Case No. PE OV 1.....	110
13.2. Case No. PE OV 2.....	112

14.	PELVIS: CERVIX	114
14.1.	Case No. PE CV 1	114
14.2.	Case No. PE CV 2	116
14.3.	Case No. PE CV 3	118
14.4.	Case No. PE CV 4	120
15.	LYMPHOMA	122
15.1.	Case No. LY 1	122
15.2.	Case No. LY 2	124
15.3.	Case No. LY 3	126
15.4.	Case No. LY 4	128
15.5.	Case No. LY 5	130
15.6.	Case No. LY 6	132
15.7.	Case No. LY 7	134
15.8.	Case No. LY 8	136
15.9.	Case No. LY 9	138
15.10.	Case No. LY 10	140
15.11.	Case No. LY 11	142
16.	MELANOMA	144
16.1.	Case No. ME 1	144
16.2.	Case No. ME 2	146
16.3.	Case No. ME 3	148
16.4.	Case No. ME 4	150
16.5.	Case No. ME 5	152
16.6.	Case No. ME 6	154
17.	MISCELLANEOUS: PROSTATE	156
17.1.	Case No. MISC PROST 1	156
17.2.	Case No. MISC PROST 2	158
17.3.	Case No. MISC PROST 3	160
17.4.	Case No. MISC PROST 4	162
18.	MISCELLANEOUS: BRAIN	164
18.1.	Case No. MISC BRAIN 1	164
18.2.	Case No. MISC BRAIN 2	166
19.	MISCELLANEOUS: NEUROENDOCRINE TUMOUR (DOPA AND DOTA)	168
19.1.	Case No. MISC NET 1	168
19.2.	Case No. MISC NET 2	170
20.	MISCELLANEOUS: IODINE-124	172
20.1.	Case No. MISC I-124 1	172
20.2.	Case No. MISC I-124 2	174

21. PAEDIATRICS	176
21.1. Case No. PAED 1	176
21.2. Case No. PAED 2	178
21.3. Case No. PAED 3	180
21.4. Case No. PAED 4	182
21.5. Case No. PAED 5	184
21.6. Case No. PAED 6	186
21.7. Case No. PAED 7	188
21.8. Case No. PAED 8	190
21.9. Case No. PAED 9	192
21.10. Case No. PAED 10	194
21.11. Case No. PAED 11	196
ABBREVIATIONS	199
CONTRIBUTORS TO DRAFTING AND REVIEW	201

1. INTRODUCTION

1.1. BACKGROUND

Integrated positron emission tomography and computed tomography (PET/CT) continues to be one of the fastest growing types of imaging modality in medicine and is becoming more widely available in many Member States, including low and middle income countries. PET/CT is considered to be an indispensable imaging technique in the modern management of cancer patients. Owing to this and to the increasing number of PET/CT systems being installed worldwide, there is a pressing need for expert training in this modern and technologically advanced diagnostic technique. Although PET/CT has many applications, including neurology, cardiology, and more recently inflammation and infection, by far the most widely used application is in oncology.

The professional and accurate interpretation of the image is as important as performing the PET/CT scan itself. Although PET/CT is not an old imaging technique, there are many publications on the proper interpretation of images, the most popular ones being atlases. These are particularly useful in providing an easy to read and convenient, practical approach for learning and further developing the skills for image interpretation.

1.2. SCOPE

This atlas serves as a teaching file of PET/CT applications in the clinical routine of cancer patients. It combines nearly one hundred comprehensive cases covering all current major indications of FDG–PET/CT imaging, including some paediatric cases, and others using several different non-FDG–PET radiopharmaceuticals.

1.3. OBJECTIVE

The cases provide an overview of how the specific oncologic disease can appear in PET/CT imaging, the typical pattern of the disease's spread, as well as typical pitfalls and teaching points. This publication is not intended to be a very comprehensive clinical atlas or a full review of the usefulness or indications — there are other more general publications available that cover these points. This atlas provides a quick, easy to read overview on the major types of cancer that can be successfully imaged through this powerful technique.

1.4. STRUCTURE

The structure of this atlas is adapted to follow the main anatomical areas, with different cases covering all major cancer entities. Each of the cases covers one of the main indications for PET/CT imaging in that particular type of cancer. For each of the cases, the reader will find a short description of the imaging protocol, brief clinical history and main relevant imaging findings, including the immediate impact on the clinical course based on the imaging findings. A list of the abbreviations used in the case studies can be found on p.199.

2. HEAD AND NECK

2.1. CASE NO. H&N 1

Study type:	Oncology	Clinical indication:	Oropharyngeal cancer
Clinical indication for PET/CT:	Initial staging		
Keywords:	ENT Multiple metastases		
PET/CT system:	Philips TF64	Tracer:	FDG
Uptake:	55 min	Dose:	311 MBq
Range:	WB	Blood glucose:	6.3 mmol/L
No. beds:	9	Min/bed:	1
Tube loading:	100 mAs	Tube voltage:	120 kVp

Short clinical history

A 55 year old female patient with large soft tissue mass in the left neck region. Cytology proved poorly differentiated ACC. CECT demonstrated widening oropharynx and necrotic soft tissue mass in the left neck.

PET/CT findings

Intense FDG uptake within the left neck region corresponding to the known cervical mass. Abnormal FDG uptake in the left oropharyngeal region with thickened wall on the CT images. Multiple pulmonary nodules with increased FDG uptake are also detected representing pulmonary metastases. There are multiple, foci of increased FDG uptake in the liver and through several bones (left scapula, sacrum and left radius).

Impression: Primary oropharyngeal tumour with metastatic LNs in both sides of the neck, with multiple pulmonary, hepatic and osseous metastases.

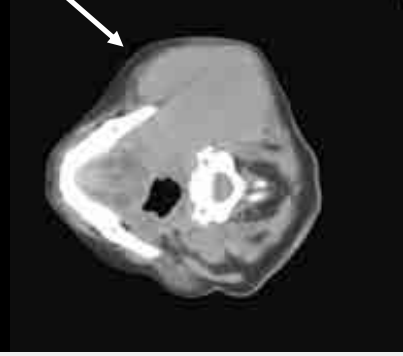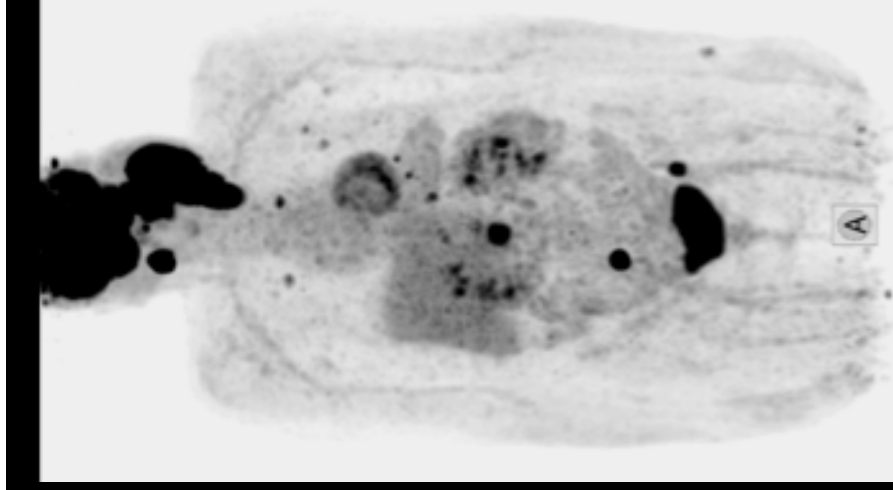
Follow-up

Tissue biopsy.

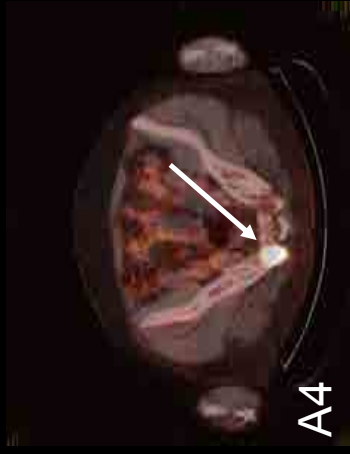
Treatment: Palliative ChTx.

Consequences of the current PET/CT examination reported here

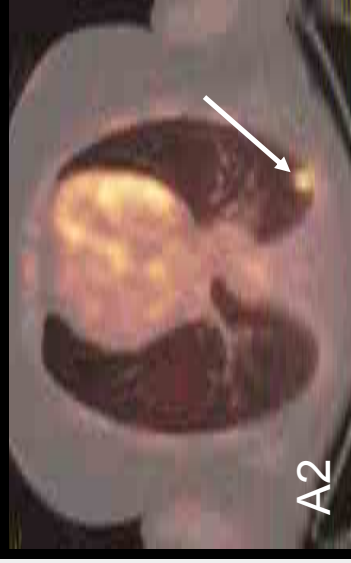Upstage of disease and change in treatment plan.



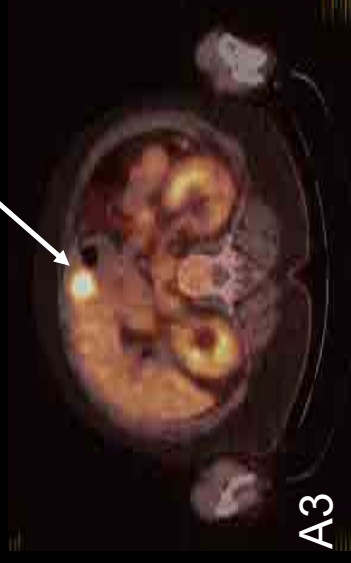A1



A4



A2



A3

Oropharyngeal cancer

55 y/o F patient with left neck mass. FDG-PET/CT requested for initial staging.

Abnormal oropharyngeal and left neck soft tissue mass (A1). Contralateral submandibular metastatic LN. Multiple pulmonary (A2), hepatic (A3) and bone metastases (A4): cT4 cN3 cM1.

2.2. CASE NO. H&N 2

Study type:	Oncology	Clinical indication:	Nasopharyngeal cancer
Clinical indication for PET/CT:	Suspected recurrence		
Keywords:	ENT Locoregional metastases		
PET/CT system:	Philips TF64	Tracer:	FDG
Uptake:	55 min	Dose:	253 MBq
Range:	WB	Blood glucose:	4.2 mmol/L
No. beds:	10	Min/bed:	1
Tube loading:	100 mAs	Tube voltage:	120 kVp

Short clinical history

A 37 year old female patient with nasopharyngeal carcinoma diagnosed and treated (with surgical resection and ChTx) in 2009. Follow-up CT scan in 2011 was negative. Ultrasound guided biopsy from a left neck LN was positive for SCC. The patient refused the recommended treatment (radical neck dissection).

PET/CT findings

Head and neck: In the nasopharynx, a 30 × 20 mm mass with intense FDG uptake is detected. At the level of the left mandibular angle, in the parajugular region a 17 mm LN with intense uptake can be seen.

Lung: In the right upper lobe, an FDG avid 10 mm nodule is present.

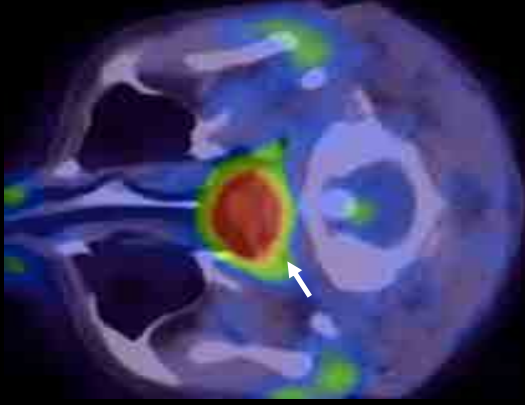
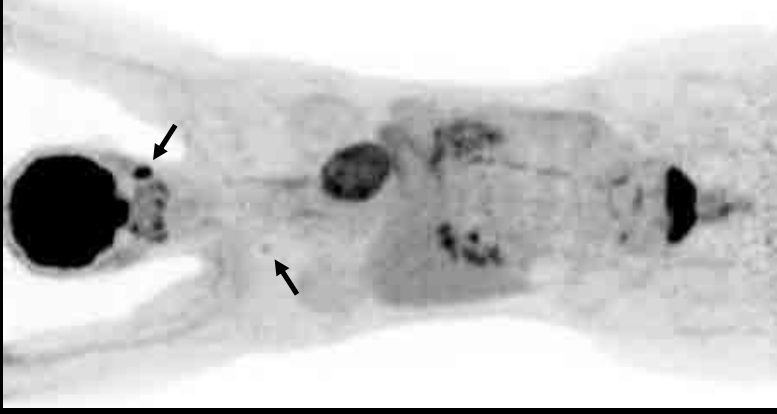
Impression: Tumour recurrence in the nasopharynx with additional LN metastasis in the left parajugular region, including a 10 mm solitary lung metastasis in the right upper lung.

Follow-up

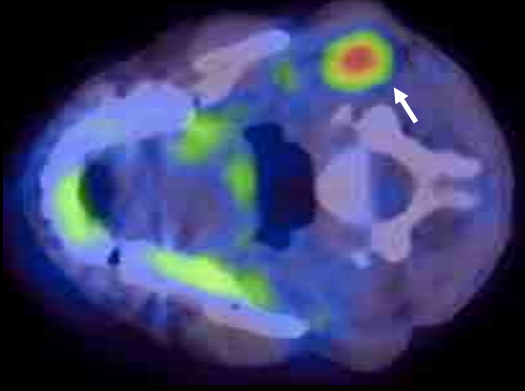
Treatment: Patient refused the recommended treatment.

Consequences of the current PET/CT examination reported here

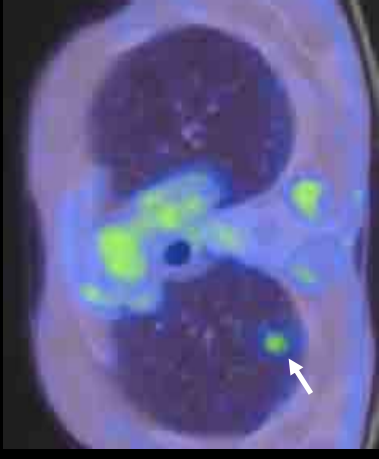
Upstage of disease and change in treatment plan.



A1



A2



A3

Nasopharyngeal cancer

37 y/o F patient with nasopharyngeal cancer diagnosed in 2009 and s/p resection. ChTxRT. Ultrasound guided biopsy was positive. Patient refused radical neck dissection (recommended treatment). FDG-PET/CT requested for restaging.

Recurrence (30 x 20 mm) in nasopharynx (A1) and additional 17 mm hypermetabolic LN in left parajugular region (A2) and 10 mm lesion (A3) in right upper lung.

2.3. CASE NO. H&N 3

Study type:	Oncology	Clinical indication:	Laryngopharyngeal cancer
Clinical indication for PET/CT:	Initial staging		
Keywords:	ENT Locoregional metastases		
PET/CT system:	Philips TF64	Tracer:	FDG
Uptake:	55 min	Dose:	411 MBq
Range:	WB	Blood glucose:	4.7 mmol/L
No. beds:	11	Min/bed:	1
Tube loading:	50 mAs	Tube voltage:	120 kVp

Short clinical history

A 60 year old male patient with a history of enlarged LNs on the left side of the neck. Laryngoscopy found the primary tumour located in the piriform recess.

Histology: SCC.

MRI demonstrated stage IV-B (T3 N3 Mx) disease.

PET/CT findings

Focal uptake can be seen in the left piriform recess. Multiple enlarged and active LNs on the left side of the neck in the parajugular and supraclavicular region.

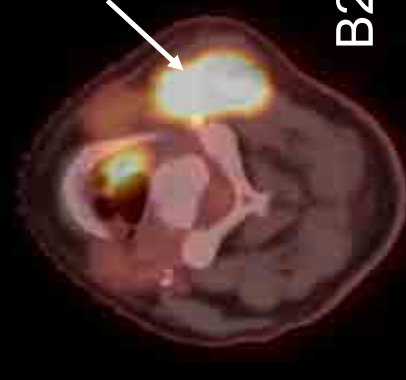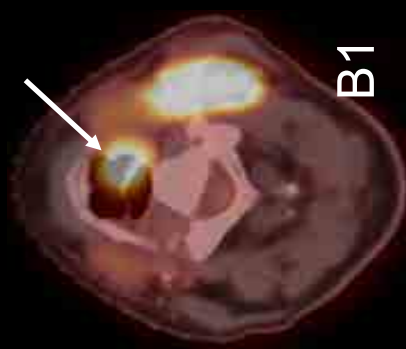
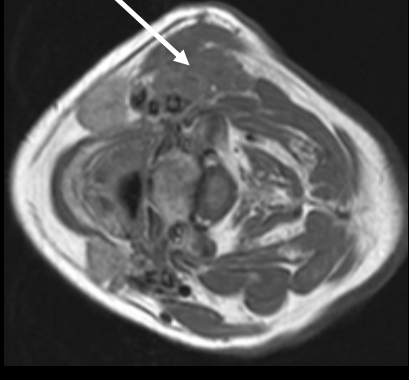
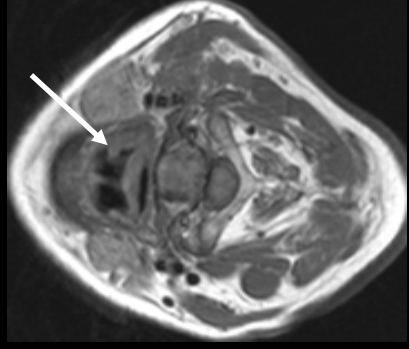
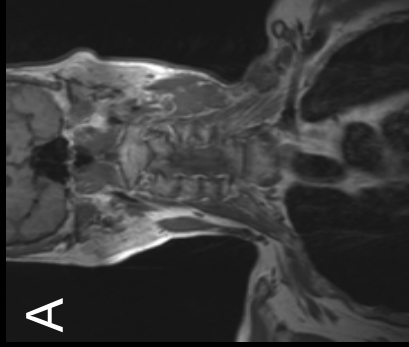
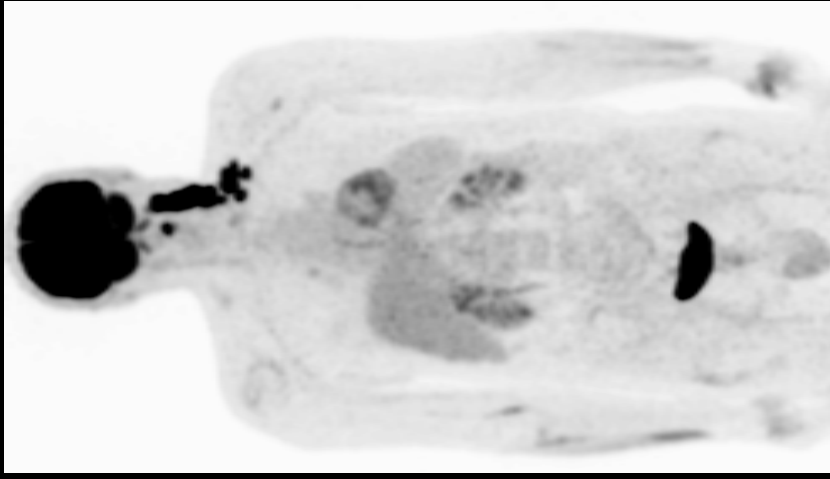
Impression: Primary tumour in the left piriform recess with widespread LN metastases on the left side of the neck.

Follow-up

Treatment: ChTxRT.

Consequences of the current PET/CT examination reported here

No change in treatment plan.



Laryngopharyngeal cancer

60 y/o M patient with histologically proven hypopharyngeal cancer. MRI showed stage IV-B (T3 N3 Mx) disease (A). FDG-PET/CT requested (B) for staging.

FDG uptake corresponding to the primary tumour on the piriform recess (B1) and in the left parajugular (B2) and supraclavicular LN region.

Treated with ChTxRT.

2.4. CASE NO. H&N 4

Study type:	Oncology	Clinical indication:	Nasopharyngeal cancer
Clinical indication for PET/CT:	Restaging		
Keywords:	ENT LN metastases		
PET/CT system:	Philips TF64	Tracer:	FDG
Uptake:	61 min	Dose:	411 MBq
Range:	WB	Blood glucose:	5.8 mmol/L
No. beds:	11	Min/bed:	1.5
Tube loading:	150 mAs	Tube voltage:	120 kVp

Short clinical history

A 64 year old male patient with a history of nasopharyngeal tumour. S/p ChTxRT 2 years ago. During clinical follow-up, a single palpable nodule appeared in the left side of the neck. FDG-PET/CT was recommended for restaging.

PET/CT findings

PET/CT for restaging shows small parajugular LN with moderate FDG uptake in the left side of the neck.

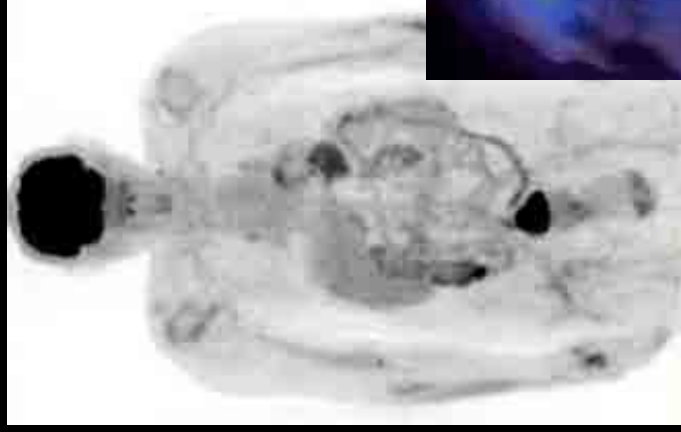Impression: Recurrent metastatic LNs in the left cervical region with evidence of progressive disease in the follow-up study.

Follow-up

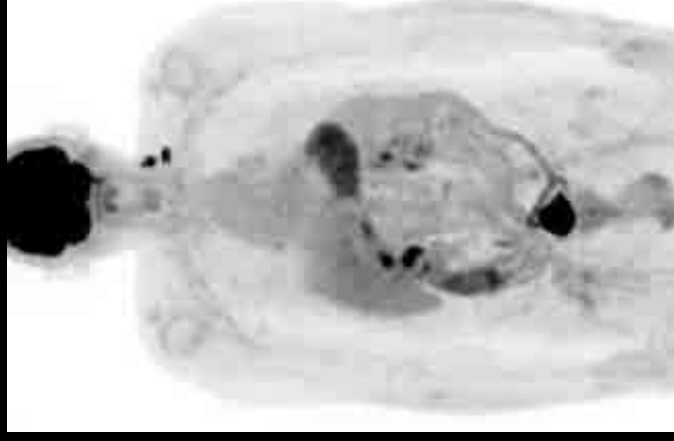
Treatment: Palliative ChTxRT.

Consequences of the current PET/CT examination reported here

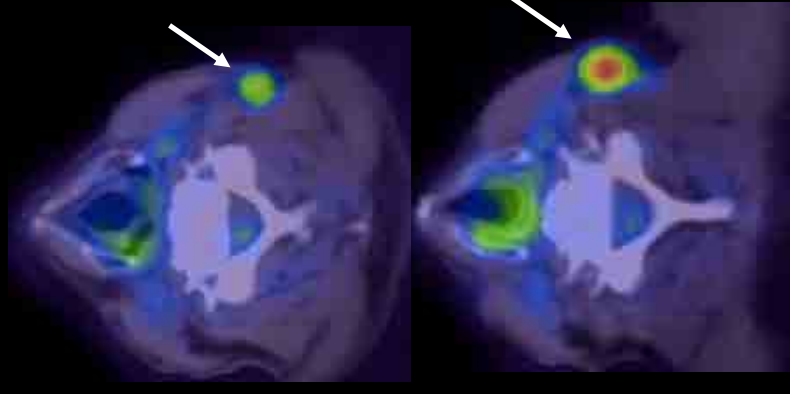
Upstage of disease and change in treatment plan.



A



B



Nasopharyngeal cancer

64 y/o M patient with a history of nasopharyngeal tumour. S/p ChTxRT 2 years ago. During clinical follow-up, a single palpable nodule was detected in the left side of the neck.

(A) FDG-PET/CT requested for restaging shows a small parajugular LN with moderate FDG uptake in the left side of the neck. ChTxRT.

(B) FDG-PET/CT requested for follow-up shows progressive disease.

2.5. CASE NO. H&N 5

Study type:	Oncology	Clinical indication:	Oropharyngeal cancer
Clinical indication for PET/CT:	Recurrence		
Keywords:	ENT Secondary cancer		
PET/CT system:	Philips TF64	Tracer:	FDG
Uptake:	62 min	Dose:	352 MBq
Range:	WB	Blood glucose:	4.8 mmol/L
No. beds:	10	Min/bed:	1
Tube loading:	52 mAs	Tube voltage:	120 kVp

Short clinical history

A 54 year old male patient with tonsillar and base of the tongue SCC, with initial stage III.

Treatment: Surgery and RTx. FDG–PET/CT scan was requested for restaging.

PET/CT findings

Head and neck: Posterior to the right mandibular angle, there is a 2 cm LN with moderate intense FDG uptake. On the right side of the base of the tongue, there is 1.8 cm intense FDG uptake without corresponding soft tissue mass on the CT.

Lungs: In the right middle lobe of the lung, there is a diffuse infiltration with mildly increased FDG uptake.

Oesophagus: In the middle third of the oesophagus, there is 1.7 cm focally intense FDG uptake.

Impression: Locoregional recurrence in the right base of the tongue. LN metastasis in right mandibular angle. Intense focal FDG uptake in the oesophagus, which is likely a second primary tumour. The FDG uptake pattern in the right lung is consistent with an inflammatory process.

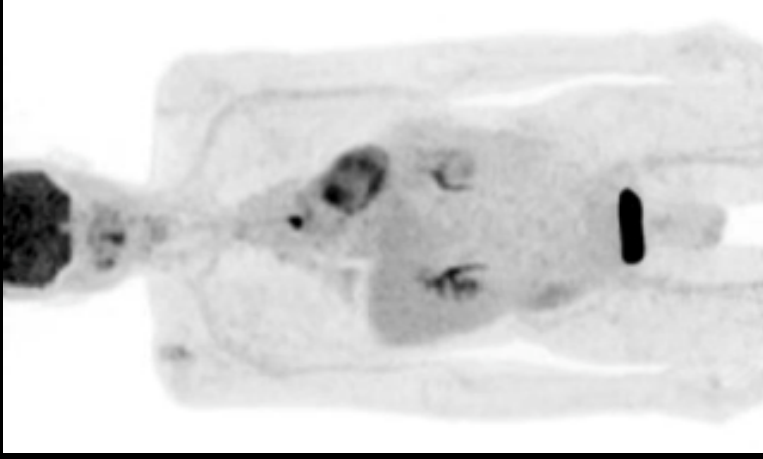Follow-up

Additional CT imaging follow-up of the right lung lesions.

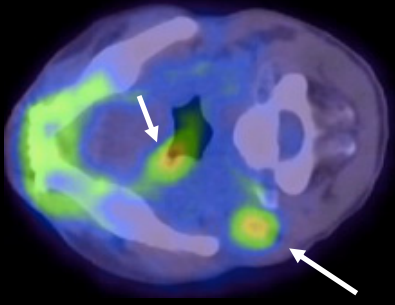
Tissue biopsy: Oesophagus.

Consequences of the current PET/CT examination reported here

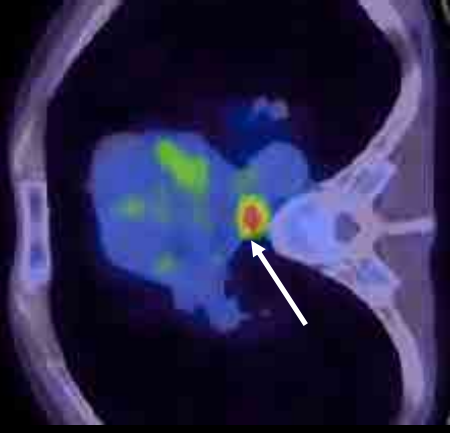
Upstage of disease and change in treatment plan.



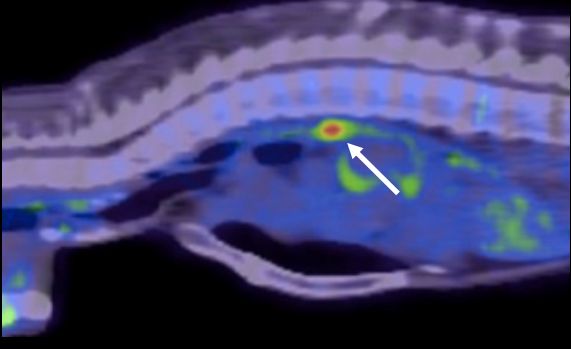
A1



A2



A3



Oropharyngeal cancer

54 y/o M patient with tonsillar and base of the tongue SCC, stage III before treatment. S/p 1 year after surgery and RTx. FDG-PET/CT requested for restaging.

Metastatic recurrence in the right base of the tongue and right cervical LN metastasis (A1). Intense focal FDG avid uptake in the oesophagus (A2) suspicious for second primary tumour (A3).

2.6. CASE NO. H&N 6

Study type:	Oncology	Clinical indication:	Oropharyngeal cancer
Clinical indication for PET/CT:	Initial staging		
Keywords:	ENT LN metastases		
PET/CT system:	Philips TF64	Tracer:	FDG
Uptake:	64 min	Dose:	317 MBq
Range:	WB	Blood glucose:	6.5 mmol/L
No. beds:	8	Min/bed:	2
Tube loading:	140 mAs	Tube voltage:	80 kVp

Short clinical history

A 61 year old male patient post-surgery of a left-sided tonsillar cancer 4 weeks ago. Patient had a neck MRI prior to surgery demonstrating LN metastases on the left side of the neck. FDG–PET/CT was requested for WB staging in order to rule out residual tumour in the tonsillar bed and plan further therapy.

PET/CT findings

FDG–PET/CT showed increased tracer uptake in the left oropharynx without a morphological correlate on CECT — probably reactive post-surgery. However, small residual tumour cannot be excluded.

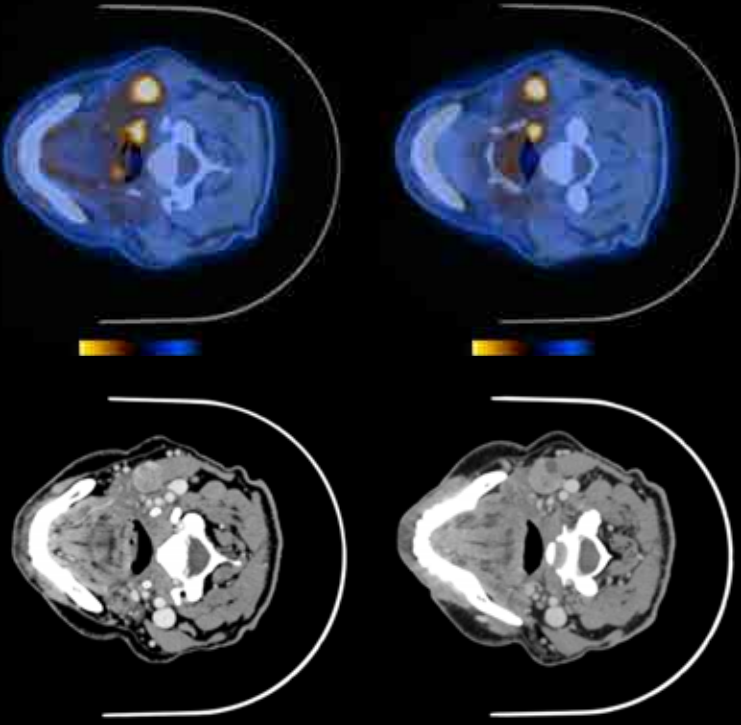
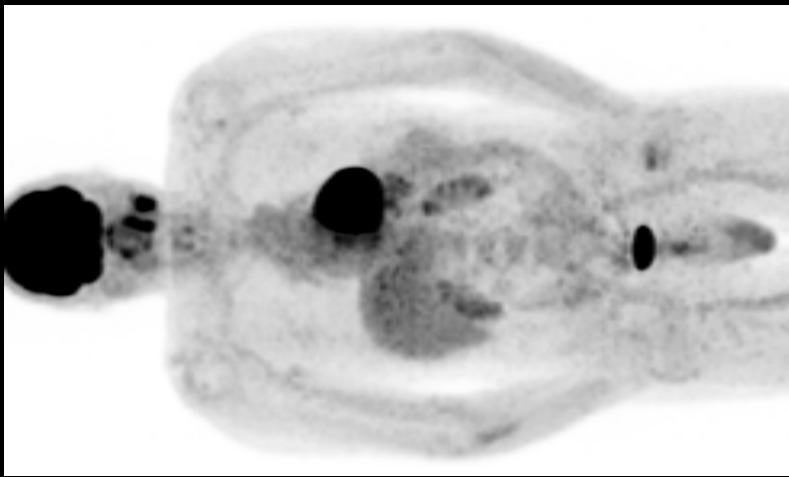
Large and partially cystic LN metastases in the left cervical region, indicating residual oropharyngeal cancer.

Follow-up

Curative treatment: Surgery (neck dissection).

Consequences of the current PET/CT examination reported here

No change in treatment plan (neck dissection was planned prior to primary surgery).



Oropharyngeal cancer

61 y/o M patient s/p surgery of a left-sided tonsillar cancer 4 weeks ago.

FDG-PET/CT requested for initial staging showed increased FDG uptake in the left oropharynx without a morphological correlate on CECT. Large and partly cystic LN metastases left cervically, indicating oropharyngeal cancer.

2.7. CASE NO. H&N 7

Study type:	Oncology	Clinical indication:	Tonsillar carcinoma
Clinical indication for PET/CT:	Restaging		
Keywords:	ENT Multiple metastases		
PET/CT system:	GE Discovery	Tracer:	FDG
Uptake:	76 min	Dose:	163 MBq
Range:	WB	Blood glucose:	5.5 mmol/L
No. beds:	7	Min/bed:	3
Tube loading:	100 mAs	Tube voltage:	120 kVp

Short clinical history

A 58 year old female patient with a history of tonsillar carcinoma. Complete regression after ChTxRT. Six years later, she developed cardiac symptoms. CECT shows cardiac tumour involvement with multiple pulmonary metastases.

PET/CT findings

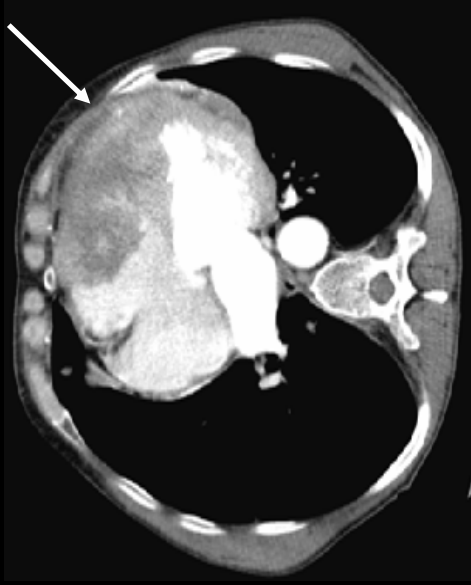
Metastatic spread to the heart and lungs.

Follow-up

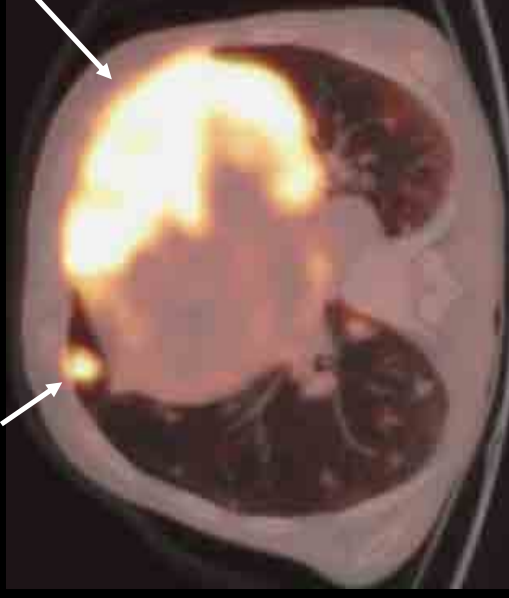
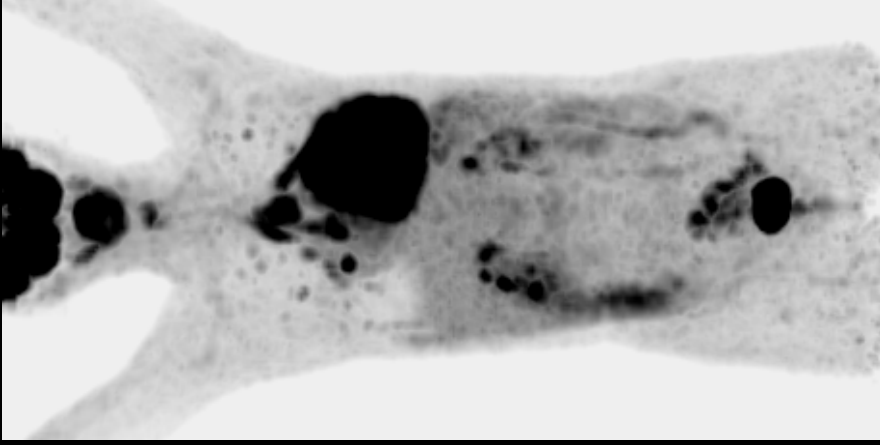
Treatment: ChTx with palliative intent.

Consequences of the current PET/CT examination reported here

Upstage of disease and change in treatment plan.



CECT



PET/CT

Tonsillar carcinoma

58 y/o F patient with tonsillar carcinoma. Complete regression after ChTxRT. 6 years later cardiac symptoms. CECT: cardiac and multiple pulmonary metastases. FDG-PET/CT requested for staging.

PET/CT confirmed cardiac and metastatic disease to the lungs.

3. HEAD AND NECK: THYROID

3.1. CASE NO. H&N THY 1

Study type:	Oncology	Clinical indication:	DTC
Clinical indication for PET/CT:	Restaging		
Keywords:	DTC Multiple metastases LN metastasis		
PET/CT system:	Siemens Biograph Duo	Tracer:	FDG
Uptake:	56 min	Dose:	298 MBq
Range:	WB	Blood glucose:	6.3 mmol/L
No. beds:	8	Min/bed:	2
Tube loading:	154 mAs	Tube voltage:	80 kVp

Short clinical history

A 61 year old male patient with DTC (pT4 pN1 M0) s/p total thyroidectomy and treatment with ¹³¹I. The patient was lost in follow-up for 5 years, subsequently presenting with dyspnoea and a cervical mass suspicious for recurrent disease.

PET/CT findings

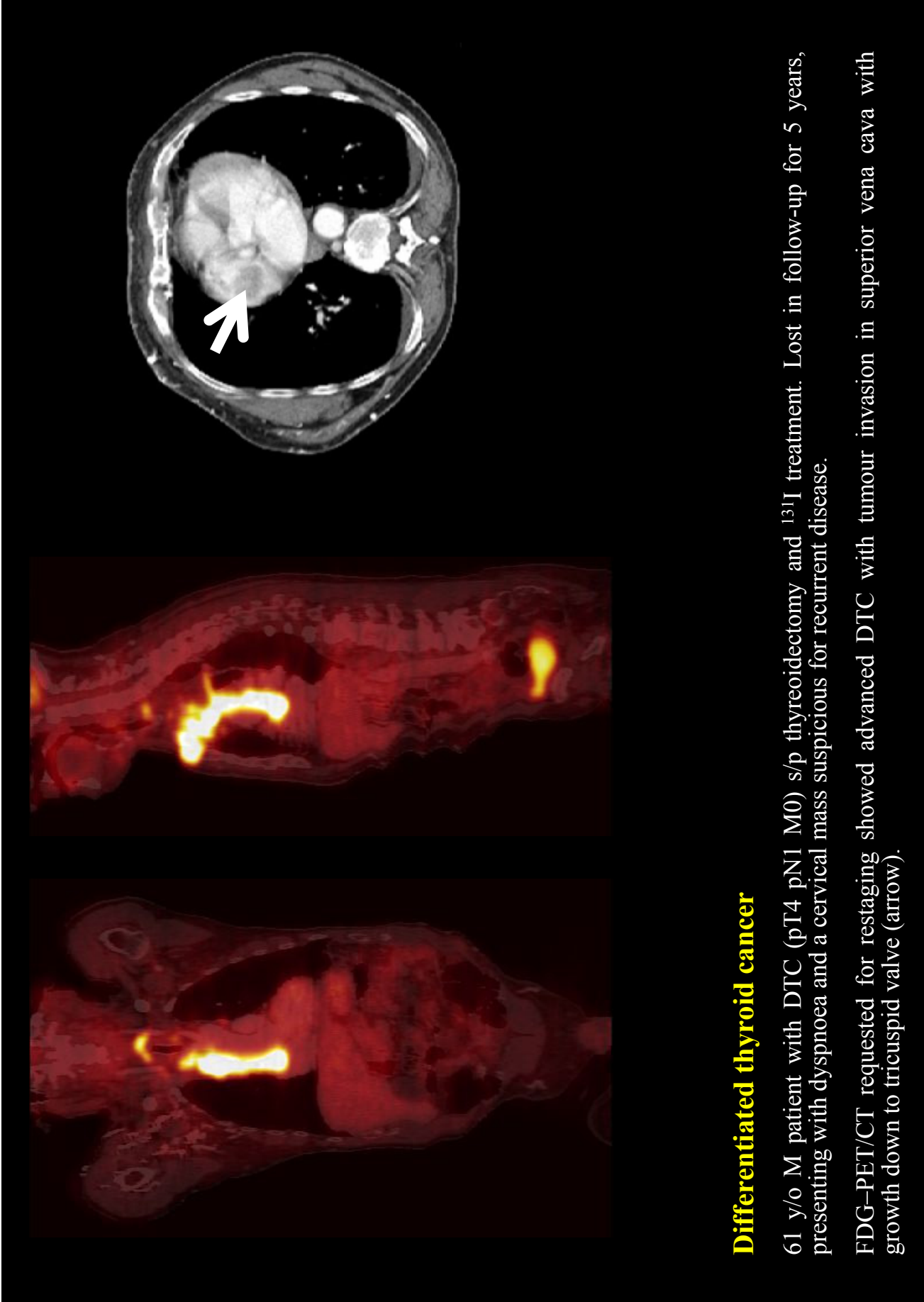
FDG–PET/CT requested for restaging showed advanced DTC with tumour invasion of the superior vena cava, which is growing down to tricuspid valve (arrow).

Follow-up

Treatment: Palliative tumour debulking and ChTx.

Consequences of the current PET/CT examination reported here

Change in treatment plan.



Differentiated thyroid cancer

61 y/o M patient with DTC (pT4 pN1 M0) s/p thyroidectomy and ^{131}I treatment. Lost in follow-up for 5 years, presenting with dyspnoea and a cervical mass suspicious for recurrent disease.

FDG-PET/CT requested for restaging showed advanced DTC with tumour invasion in superior vena cava with growth down to tricuspid valve (arrow).

3.2. CASE NO. H&N THY 2

Study type:	Oncology	Clinical indication:	DTC
Clinical indication for PET/CT:	Restaging		
Keywords:	Multiple metastases LN metastases Osseous metastases		
PET/CT system:	Siemens Biograph Duo	Tracer:	FDG
Uptake:	56 min	Dose:	250 MBq
Range:	WB	Blood glucose:	6.1 mmol/L
No. beds:	8	Min/bed:	2
Tube loading:	140 mAs	Tube voltage:	80 kVp

Short clinical history

A 69 year old male patient with DTC (pT4 pN1 M1) s/p thyroidectomy and ¹³¹I (total cumulative activity of 16 GBq ¹³¹I) with PR (decrease of Tg from 1200 ng/mL to 14 ng/mL). However, after 1 year increasing Tg to 89 ng/mL.

PET/CT findings

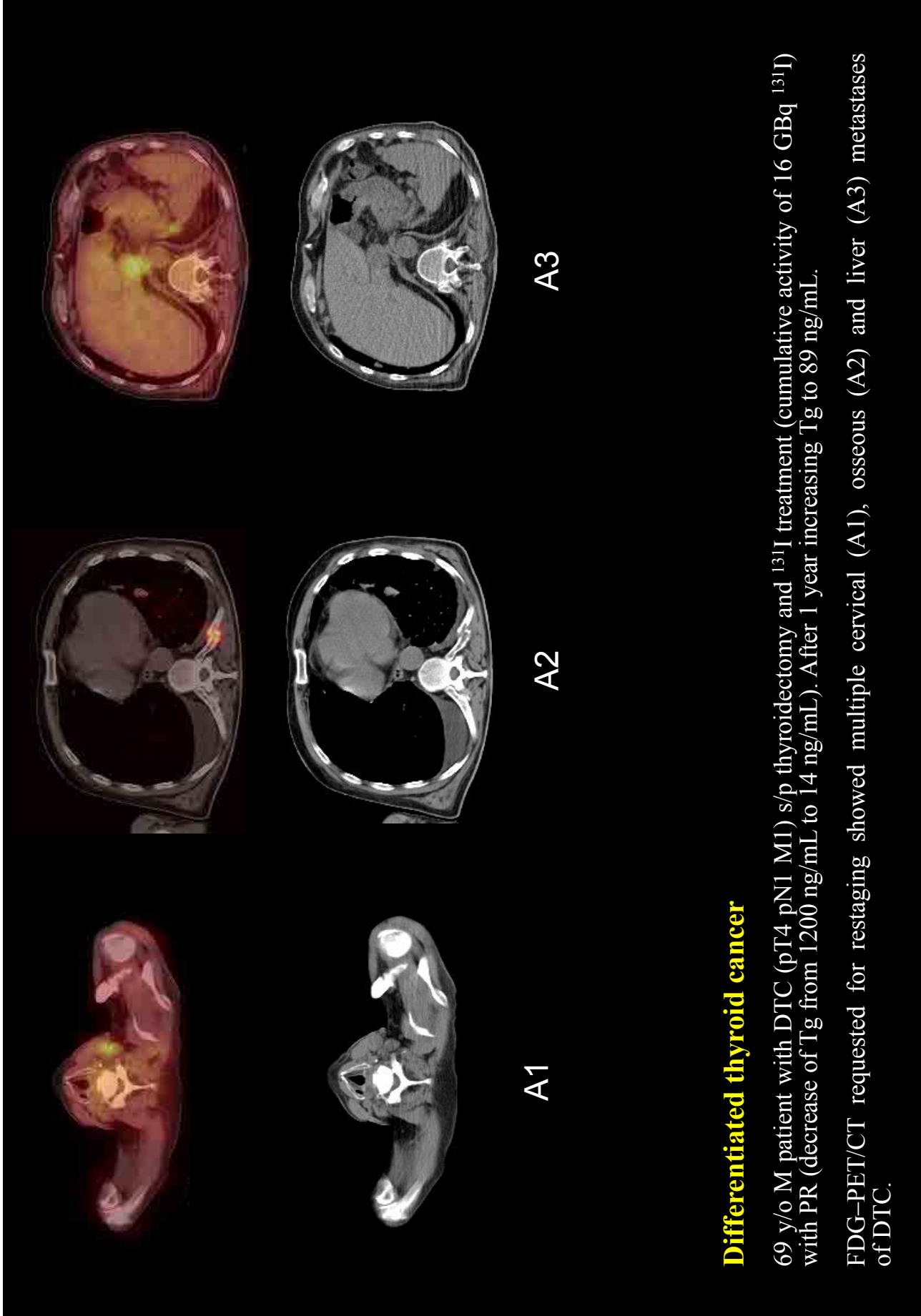
FDG–PET/CT requested for restaging purposes showed several cervical (A1), osseous (A2) and liver (A3) metastases from DTC.

Follow-up

Treatment: Observation followed by palliative ChTx after 8 months.

Consequences of the current PET/CT examination reported here

Change in treatment plan.



Differentiated thyroid cancer

69 y/o M patient with DTC (pT4 pN1 M1) s/p thyroidectomy and ¹³¹I treatment (cumulative activity of 16 GBq ¹³¹I) with PR (decrease of Tg from 1200 ng/mL to 14 ng/mL). After 1 year increasing Tg to 89 ng/mL.

FDG–PET/CT requested for restaging showed multiple cervical (A1), osseous (A2) and liver (A3) metastases of DTC.

4. CANCER OF UNKNOWN PRIMARY

4.1. CASE NO. CUP 1

Study type:	Oncology	Clinical indication:	CUP
Clinical indication for PET/CT:	Initial staging		
Keywords:	CUP ENT Pitfall		
PET/CT system:	Siemens Biograph Duo	Tracer:	FDG
Uptake:	63 min	Dose:	298 MBq
Range:	WB	Blood glucose:	5.0 mmol/L
No. beds:	8	Min/bed:	3
Tube loading:	100 mAs	Tube voltage:	120 kVp

Short clinical history

A 64 year old male patient with cervical mass. Biopsy proved malignancy. Endoscopy, CT and sonography to detect primary were negative. FDG–PET/CT scan was performed to detect primary.

PET/CT findings

FDG–PET/CT was not able to detect the primary tumour. PET/CT shows FDG avid LN metastases in the neck and diaphragmatic elevation likely secondary to phrenic nerve paresis. The presence of increased FDG uptake in the right vocal cord with absent uptake in the left is most likely due to paralysis of the recurrent laryngeal nerve.

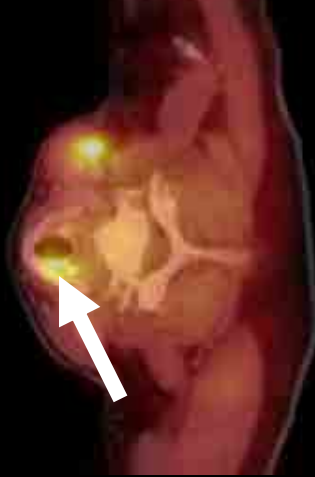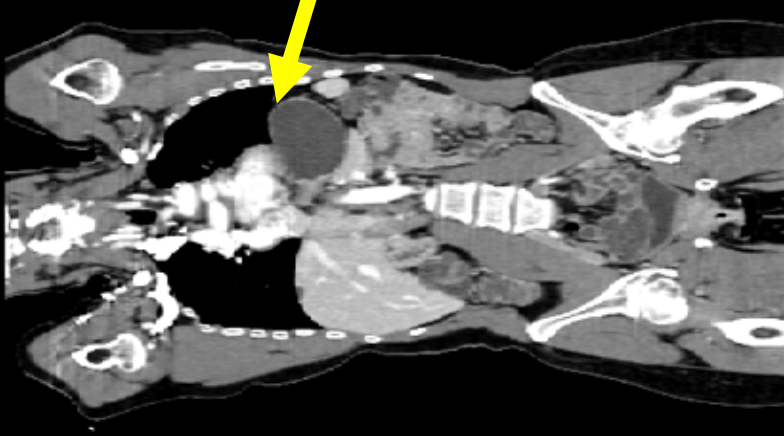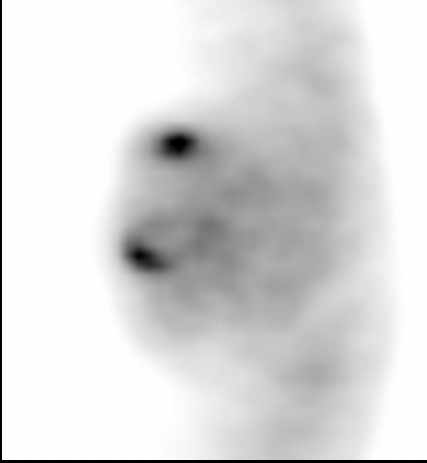Note: Tracer accumulation in the right vocal cord was interpreted as false positive in FDG–PET alone.

Follow-up

Combined ChTxRT with curative intent.

Consequences of the current PET/CT examination reported here

No change in treatment plan.



Cancer of unknown primary

64 y/o M patient with cervical metastasis. CUP. CT was negative.

FDG-PET/CT: FDG avid neck LN metastases and paresis of left phrenic nerve with diaphragmatic elevation (yellow arrow) and absent FDG uptake by the left vocal cord, with normal uptake by the right vocal cord (white arrow).

Note: Tracer accumulation in the right vocal cord was interpreted as false positive in FDG-PET alone.

4.2. CASE NO. CUP 2

Study type:	Oncology	Clinical indication:	CUP
Clinical indication for PET/CT:	Initial staging		
Keywords:	CUP ENT		
PET/CT system:	Siemens Biograph Duo	Tracer:	FDG
Uptake:	60 min	Dose:	312 MBq
Range:	WB	Blood glucose:	4.9 mmol/L
No. beds:	8	Min/bed:	3
Tube loading:	100 mAs	Tube voltage:	120 kVp

Short clinical history

A 60 year old male patient with cervical mass. Biopsy proved malignancy. Endoscopy, CT and sonography to detect primary were negative.

FDG–PET/CT scan was performed to detect primary.

PET/CT findings

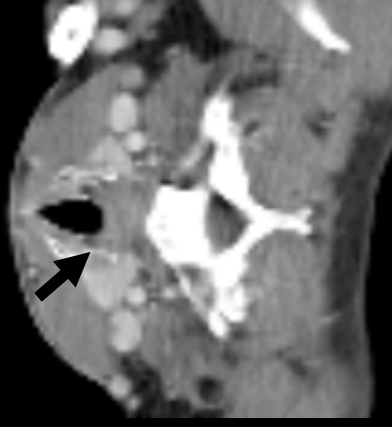
FDG–PET/CT scan detected laryngopharyngeal carcinoma and avid LN metastases in the neck. No distant metastases were detected.

Follow-up

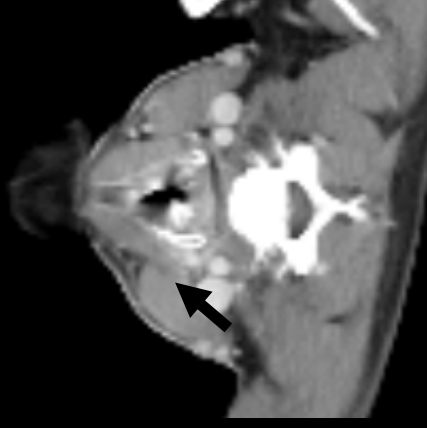Surgery and adjuvant combined ChTxRT with curative intent.

Consequences of the current PET/CT examination reported here

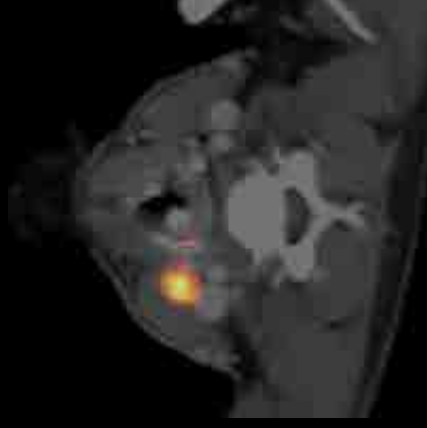
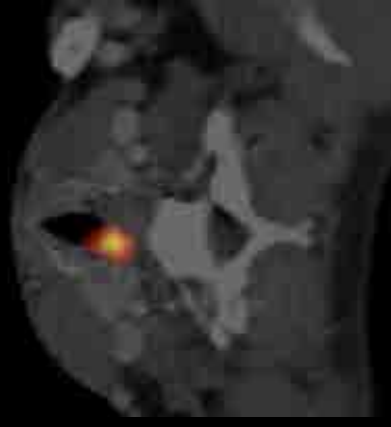
Change in treatment plan.



A1



A2



Cancer of unknown primary

60 y/o M patient with cervical metastasis. CUP. CT was negative.

FDG-PET/CT requested for initial staging: Laryngopharyngeal carcinoma (A1) and neck LN metastases (A2).

4.3. CASE NO. CUP 3

Study type:	Oncology	Clinical indication:	CUP
Clinical indication for PET/CT:	Initial staging		
Keywords:	CUP ENT		
PET/CT system:	GE Discovery VCT	Tracer:	FDG
Uptake:	63 min	Dose:	360 MBq
Range:	WB	Blood glucose:	5.0 mmol/L
No. beds:	8	Min/bed:	3
Tube loading:	120 mAs	Tube voltage:	80 kVp

Short clinical history

A 57 year old male patient with histologically proven LN metastasis of a squamous cell carcinoma. The primary tumour was not discoverable despite clinical ENT examination. Primary tumour therefore unknown at the time of the FDG–PET/CT scan.

PET/CT findings

FDG–PET/CT shows large LNs with elevated glucose metabolism in the left cervical region. In addition, a focally elevated spot of glucose metabolism in the posterior wall of the left-sided piriform sinus is detected, suspicious of being the primary tumour.

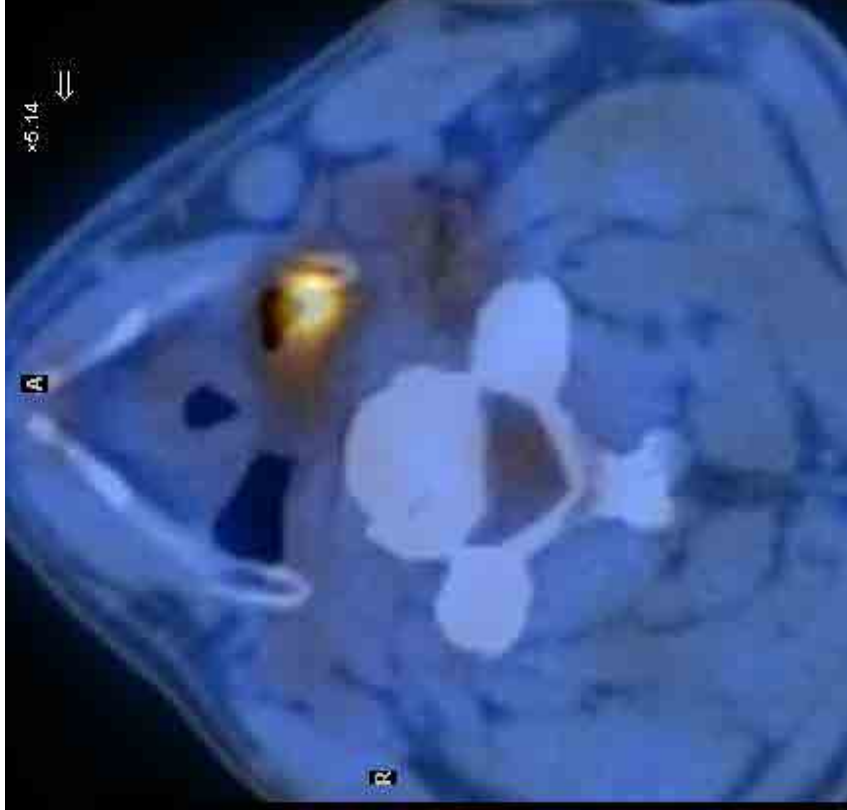
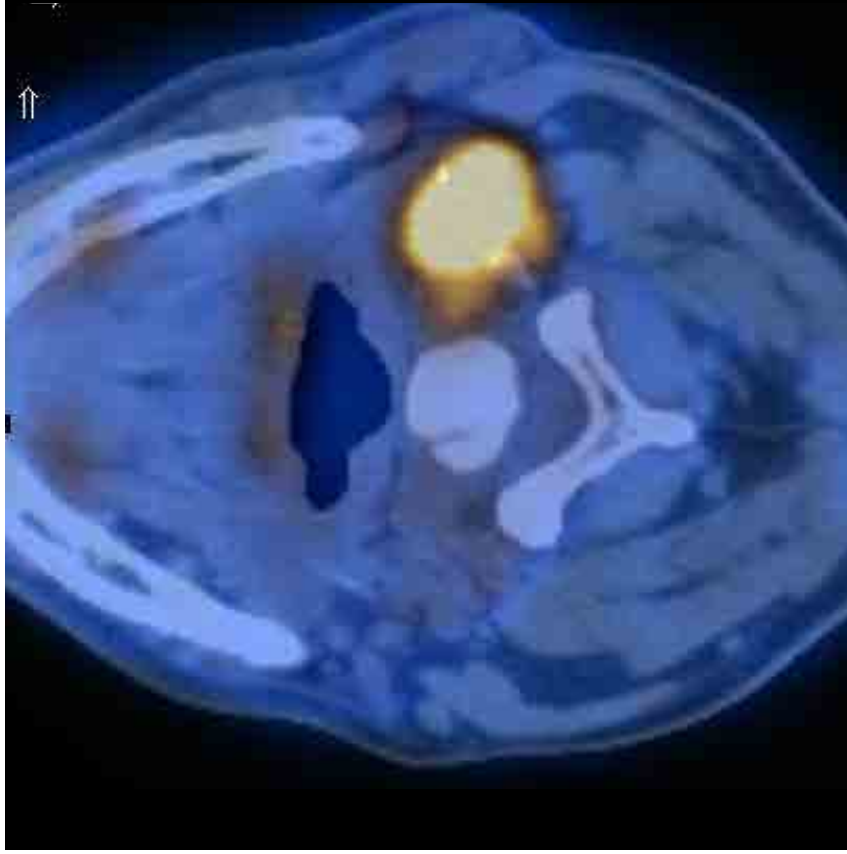
‘Second look’ clinical examination at the ENT department confirmed the PET/CT diagnosis.

Follow-up

Surgery with curative intent.

Consequences of the current PET/CT examination reported here

Upstage of disease and change in treatment plan.



Cancer of unknown primary

57 y/o M patient with histologically proven LN metastasis. The primary tumour was, despite ENT examination, unknown at the time of the FDG-PET/CT.

FDG-PET/CT shows a focally elevated spot of glucose metabolism in the posterior wall of the left-sided piriform sinus.

5. THORAX: BREAST

5.1. CASE NO. TH BR 1

Study type:	Oncology	Clinical indication:	Breast cancer
Clinical indication for PET/CT:	Initial staging		
Keywords:	Breast cancer Pitfall		
PET/CT system:	Philips TF64	Tracer:	FDG
Uptake:	64 min	Dose:	306 MBq
Range:	WB	Blood glucose:	5.5 mmol/L
No. beds:	9	Min/bed:	1
Tube loading:	55 mAs	Tube voltage:	120 kVp

Short clinical history

A 41 year old female patient with history of breast cancer treated with lumpectomy and ALND.

Histology: IDC G3 pT1 pN1 (3/6) HER2 +++. Referred to FDG–PET/CT for initial staging after surgery of high risk cancer. Follow-up PET/CT was conducted after 3 months without additional therapy.

PET/CT findings

First PET/CT (A): Suspicion of right axillary LN metastasis. Additional FDG avid uptake in the right deltoid region owing to recent vaccination.

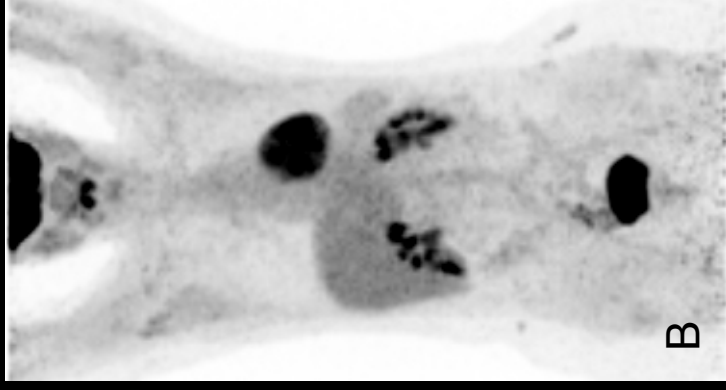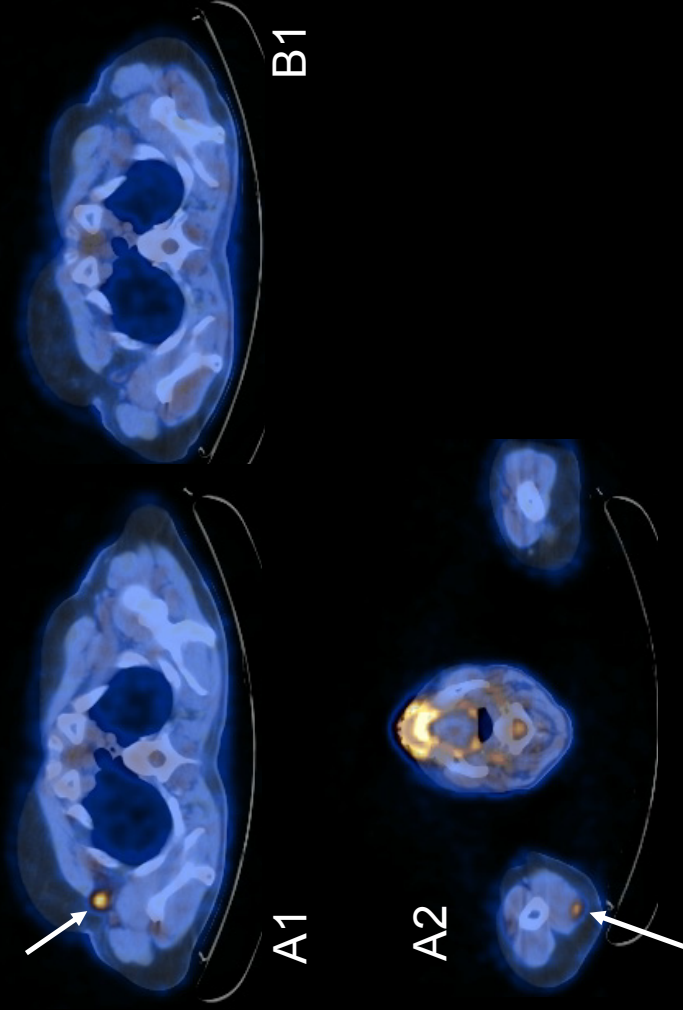
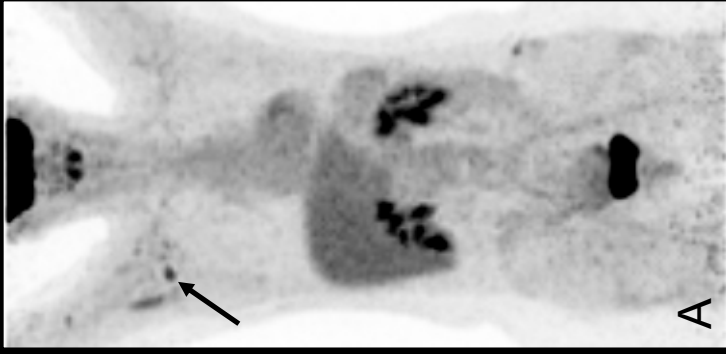
Second PET/CT (B): No uptake in the axillary region, confirming reactive LN due to vaccination. No metastatic disease.

Follow-up

Observation.

Consequences of the current PET/CT examination reported here

Downstage of disease and change in treatment plan.



Breast cancer

41 y/o F patient with history of metastatic breast cancer in CMR for several years.

(A) FDG-PET/CT requested for initial staging shows FDG-avid right axillary LN (A1). Note the site of a recent vaccination in the right deltoid region (A2).

(B) Subsequent PET/CT (B1) is negative.

5.2. CASE NO. TH BR 2

Study type:	Oncology	Clinical indication:	Breast cancer
Clinical indication for PET/CT:	Initial staging		
Keywords:	Breast cancer LN metastasis Osseous metastasis		
PET/CT system:	Philips TF64	Tracer:	FDG
Uptake:	56 min	Dose:	400 MBq
Range:	WB	Blood glucose:	5.5 mmol/L
No. beds:	9	Min/bed:	1.5
Tube loading:	150 mAs	Tube voltage:	120 kVp

Short clinical history

A 50 year old female patient had a mammography which demonstrated a suspicious nodule behind the left breast tissue. Breast ultrasound also demonstrated pathologic axillary LNs.

FNAC: Malignant histology, core biopsy. Invasive ductal breast cancer.

PET/CT findings

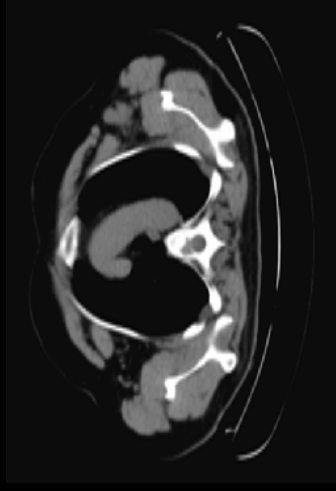
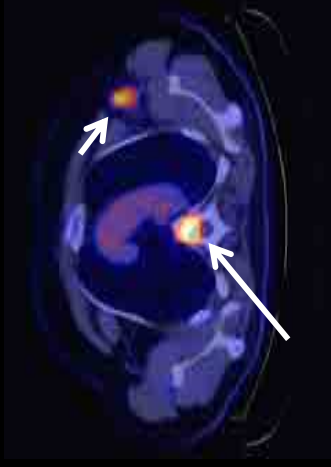
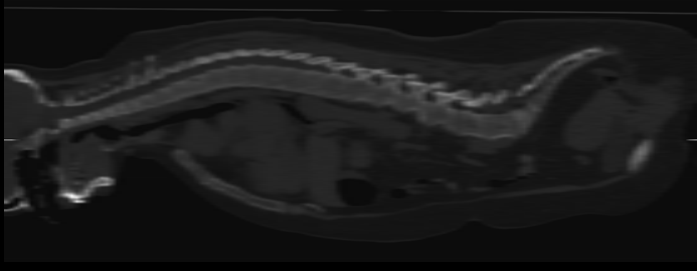
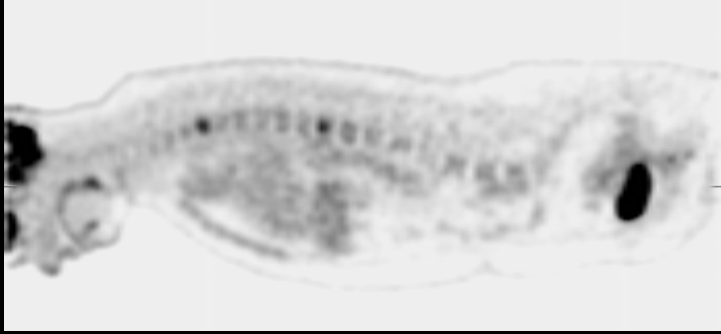
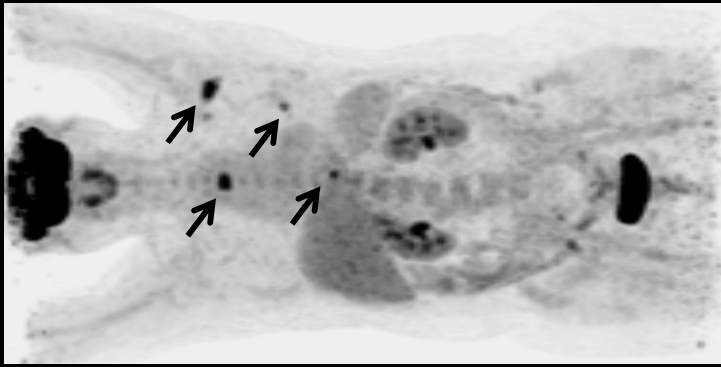
There is a 15 mm FDG avid left breast nodule with multiple FDG avid left axillary LNs and several osseous metastatic lesions: Th4, Th10 vertebra and right iliac bone.

Follow-up

Treatment: Palliative ChTx.

Consequences of the current PET/CT examination reported here

Upstage of disease from T2 N1 M0 to T2 N1 M1 and change in treatment plan.



Breast cancer

50 y/o F patient with DCIS. FDG-PET/CT requested for staging.

Metastatic disease with 15 mm retromamillar nodule, axillary LN (11 mm and 17 mm) and 17 mm osseous lesion in Th4 vertebra corresponding to lytic lesion on CT.

5.3. CASE NO. TH BR 3

Study type:	Oncology	Clinical indication:	Breast cancer
Clinical indication for PET/CT:	Restaging		
Keywords:	Breast cancer Multiple metastases		
PET/CT system:	Philips TF64	Tracer:	FDG
Uptake:	62 min	Dose:	309 MBq
Range:	WB	Blood glucose:	4.6 mmol/L
No. beds:	9	Min/bed:	1
Tube loading:	100 mAs	Tube voltage:	120 kVp

Short clinical history

A 40 year old female patient with right breast carcinoma diagnosed 6 years ago, treated with mastectomy and ChTxRT.

Histology: Mixed intra-/ductal invasive carcinoma; 4 years ago a secondary in situ ductal left breast cancer was also diagnosed. RTx of bone metastases 3 years ago including ChTxRT for neck metastasis diagnosed 3 years ago.

PET/CT findings

On the current FDG–PET/CT, multiple metastatic lesions are demonstrated mainly in the bone with additional LN in the neck and liver metastasis.

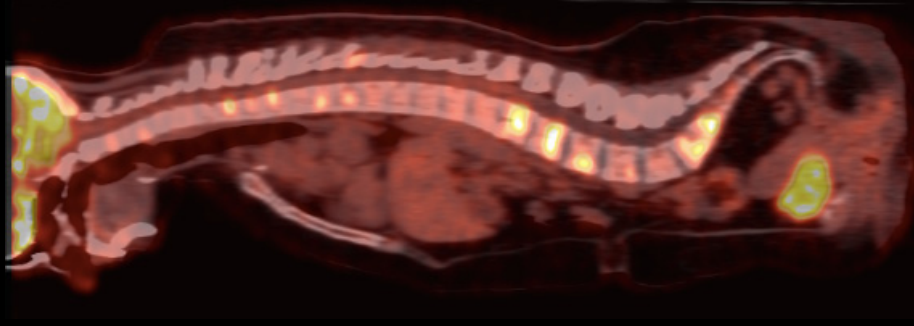
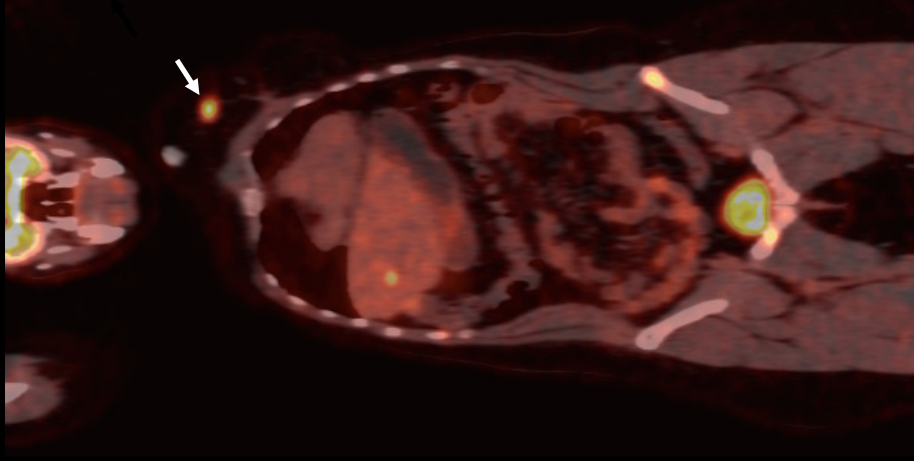
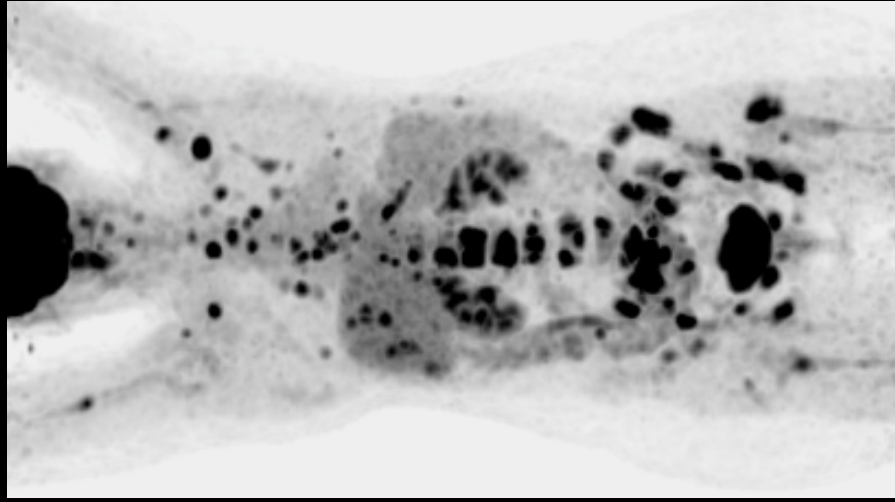
Impression: Recurrence with left breast and extensive disseminated metastatic disease.

Follow-up

Treatment: Palliative ChTx.

Consequences of the current PET/CT examination reported here

Upstage of disease and change in treatment plan.



Breast cancer

40 y/o F patient with right breast cancer diagnosed 6 years ago. S/p mastectomy and ChTxRT. FDG-PET/CT requested for restaging.

PET/CT shows recurrence in left breast (arrow) and extensive disseminated disease.

5.4. CASE NO. TH BR 4

Study type:	Oncology	Clinical indication:	Breast cancer
Clinical indication for PET/CT:	Initial staging		
Keywords:	Breast cancer LN metastases Osseous metastases Pitfall		
PET/CT system:	Philips TF64	Tracer:	FDG
Uptake:	65 min	Dose:	290 MBq
Range:	WB	Blood glucose:	5.3 mmol/L
No. beds:	7	Min/bed:	1
Tube loading:	100 mAs	Tube voltage:	120 kVp

Short clinical history

A 44 year old female patient diagnosed with metastatic breast cancer with axillary LN involvement.
Histology: DCIS. FDG–PET/CT requested for initial staging.

PET/CT findings

(A) FDG–PET/CT for initial staging shows a large inhomogeneous, FDG avid soft tissue mass in the right breast. In addition, there are numerous FDG avid LNs in the ipsilateral axillary region. An additional single osseous metastatic lesion is detected in the sacrum.

Impression: Recurrence with left breast and extensive disseminated metastatic disease.

(B) FDG–PET/CT requested for restaging after ChTx (Taxol-Avastin) shows CMR.

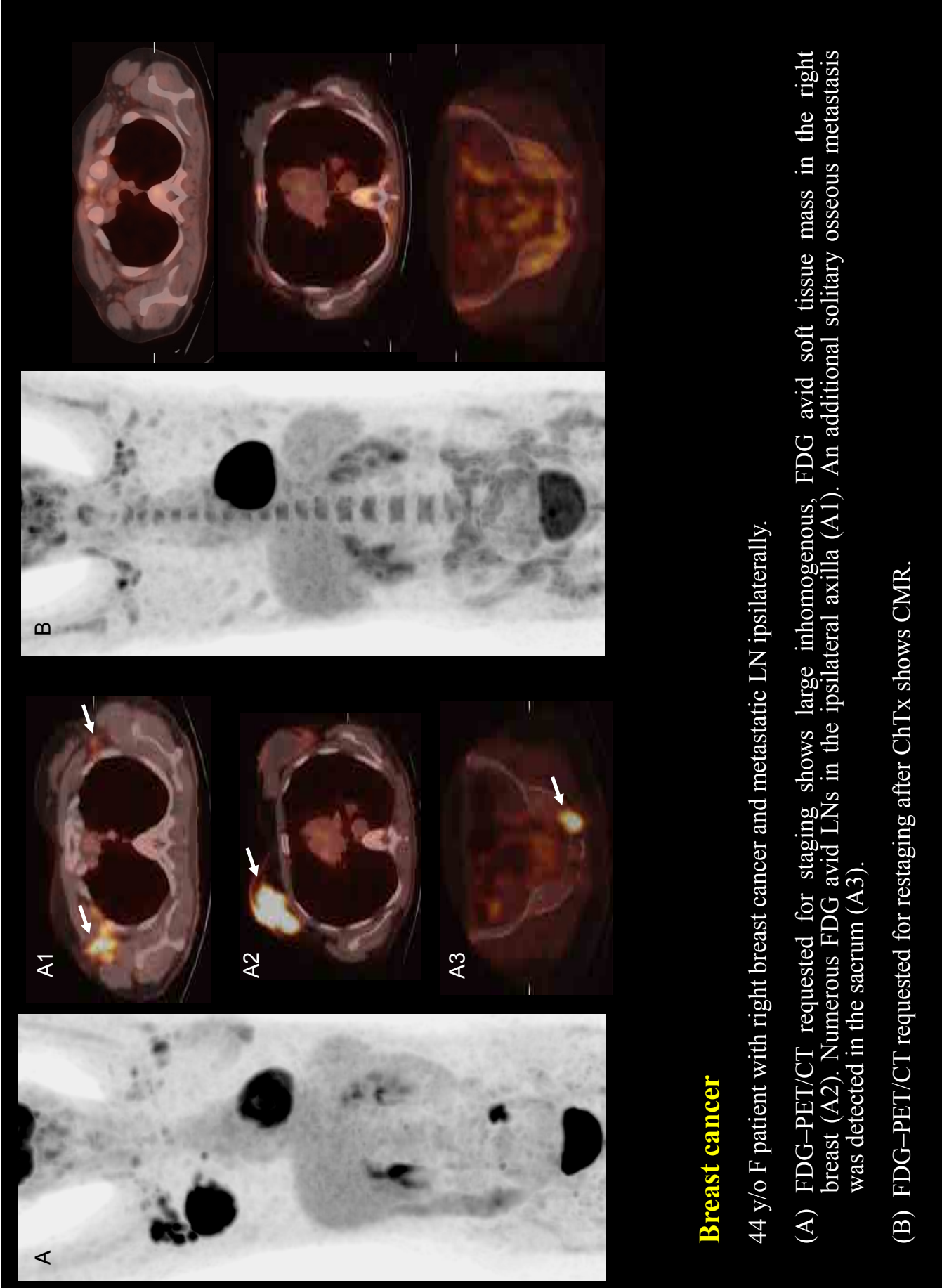
Additional findings: Brown tissue activity. Diffusely increased bone marrow activity, which is presumably the result of reactive changes post-therapy.

Follow-up

Treatment: ChTx.

Consequences of the current PET/CT examination reported here

Upstage of disease.



Breast cancer

44 y/o F patient with right breast cancer and metastatic LN ipsilaterally.

(A) FDG–PET/CT requested for staging shows large inhomogenous, FDG avid soft tissue mass in the right breast (A2). Numerous FDG avid LNs in the ipsilateral axilla (A1). An additional solitary osseous metastasis was detected in the sacrum (A3).

(B) FDG–PET/CT requested for restaging after ChTx shows CMR.

5.5. CASE NO. TH BR 5

Study type:	Oncology	Clinical indication:	Breast cancer
Clinical indication for PET/CT:	Restaging and monitoring therapy response		
Keywords:	Breast cancer Multiple metastases Therapy response		
PET/CT system:	Philips TF64	Tracer:	FDG
Uptake:	60 min	Dose:	303 MBq
Range:	WB	Blood glucose:	5.5 mmol/L
No. beds:	8	Min/bed:	1
Tube loading:	100 mAs	Tube voltage:	120 kVp

Short clinical history

A 62 year old female patient with metastatic (left axilla and infraclavicular region) breast cancer diagnosed 1 year ago. S/p surgery and ChTx.

PET/CT findings

FDG–PET/CT requested for restaging (A) shows recurrent disease with multiple LN and osseous metastasis. Subsequently, she was treated with ChTx.

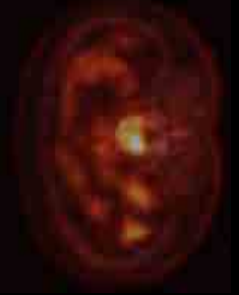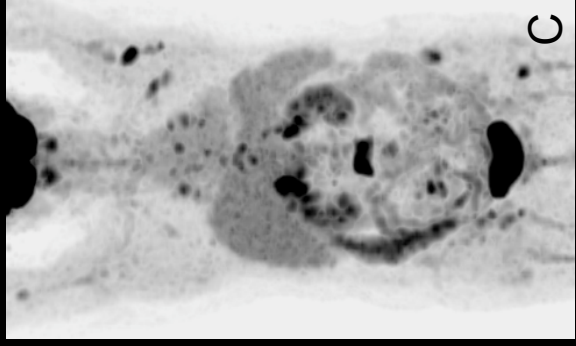
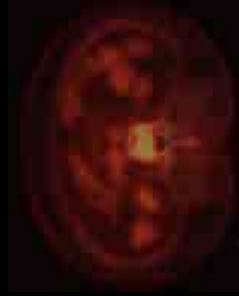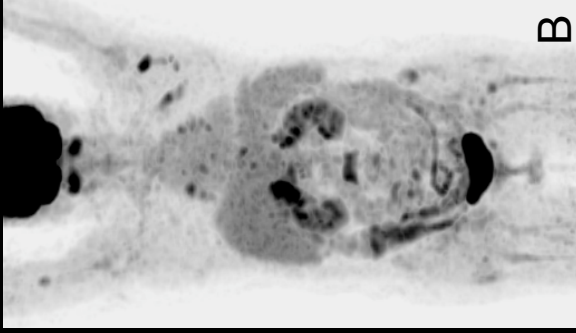
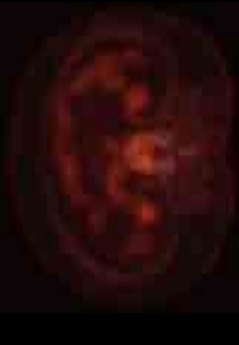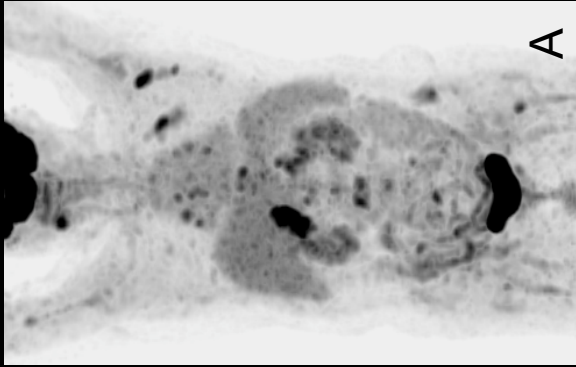
Follow-up FDG–PET/CT for treatment control (B and C) demonstrates progressive disease with new metastatic lesions (e.g. new LN in peritoneum).

Follow-up

Observation.

Consequences of the current PET/CT examination reported here

Change in treatment plan.



Breast cancer

62 y/o F patient with metastatic breast cancer diagnosed 1 year ago. S/p surgery and ChTx.

- (A) FDG-PET/CT requested for restaging shows recurrent disease.
- (B) FDG-PET/CT requested for therapy follow-up shows moderate progression.
- (C) FDG-PET/CT requested for therapy follow-up shows further progression.

5.6. CASE NO. TH BR 6

Study type:	Oncology	Clinical indication:	Breast cancer
Clinical indication for PET/CT:	Restaging		
Keywords:	Breast cancer Secondary cancer		
PET/CT system:	Philips TF64	Tracer:	FDG
Uptake:	70 min	Dose:	363 MBq
Range:	WB	Blood glucose:	5.0 mmol/L
No. beds:	8	Min/bed:	1.5
Tube loading:	150 mAs	Tube voltage:	120 kVp

Short clinical history

A 60 year old female patient who, after trauma, was found to have a nodule in the right breast. She was treated surgically followed by RTx. She underwent a second operation 5 years later owing to local recurrence of disease. This was followed 3 years later by a second recurrence, which was treated with a mastectomy and RTx. FDG–PET/CT scan was requested for restaging 3 years after the mastectomy and RTx.

PET/CT findings

Focal intense FDG uptake can be seen in a soft tissue mass located in the sigmoid colon. An additional small focus of increased FDG uptake can be seen in the right parotid gland.

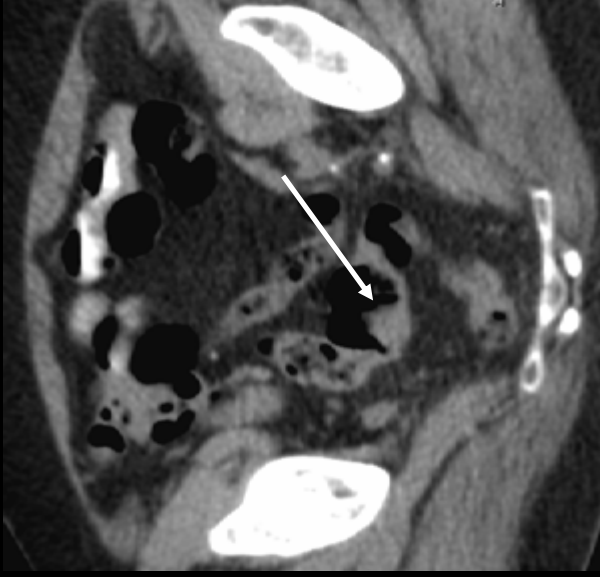
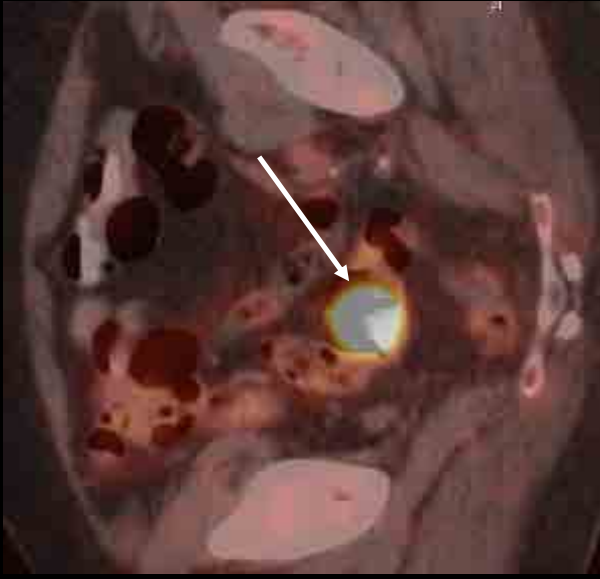
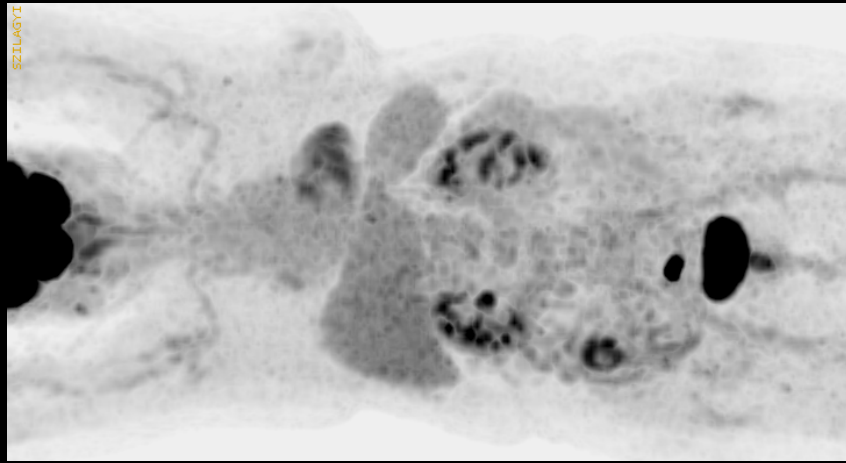
Impression: Second primary tumour in the sigmoid colon. The parotid gland lesion is likely a Warthin's tumour. However, there is no breast cancer recurrence.

Follow-up

Tissue biopsy followed by curative surgery.

Consequences of the current PET/CT examination reported here

Change in treatment plan.



Breast cancer

60 y/o F patient with right breast cancer s/p resection and RTx 12 years ago. Re-operation 8 years ago and mastectomy 2 years ago.

FDG-PET/CT requested for follow-up demonstrates intense uptake in soft tissue mass in the sigmoid.

5.7. CASE NO. TH BR 7

Study type:	Oncology	Clinical indication:	Breast cancer
Clinical indication for PET/CT:	Restaging		
Keywords:	Breast cancer Multiple metastases Therapy response		
PET/CT system:	Philips TF64	Tracer:	FDG
Uptake:	60 min	Dose:	370 MBq
Range:	WB	Blood glucose:	7.0 mmol/L
No. beds:	9	Min/bed:	1.5
Tube loading:	150 mAs	Tube voltage:	120 kVp

Short clinical history

A 56 year old female patient with infiltrating ductal breast cancer diagnosed 3 years ago and treated with ChTxRT. FDG–PET/CT was requested for restaging.

PET/CT findings

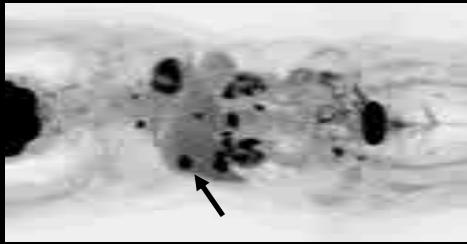
- (A) FDG–PET/CT shows multiple metastatic foci. Subsequently, the patient was treated with 8 cycles of Avastin-Taxol.
- (B) FDG–PET/CT requested for evaluation of response to therapy shows CMR.

Follow-up

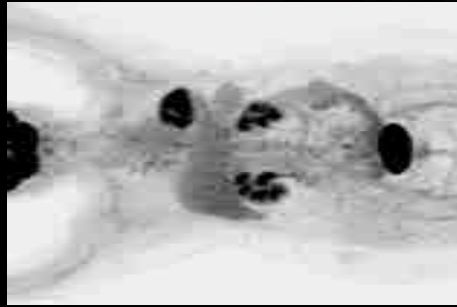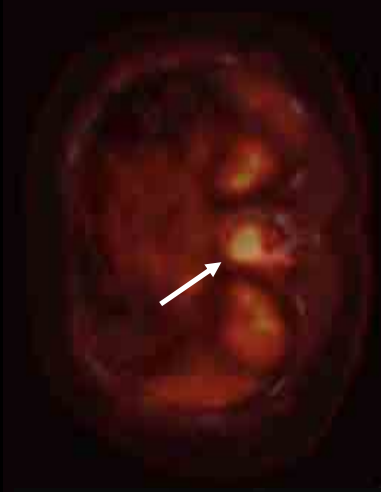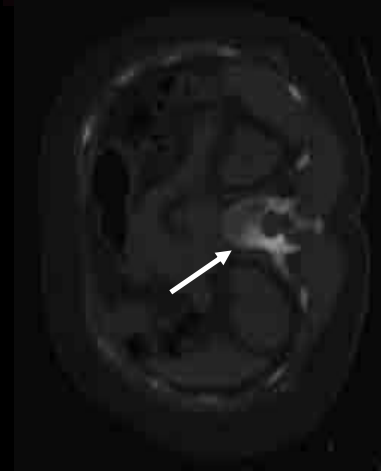
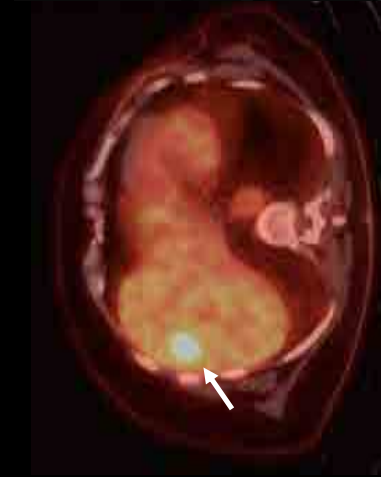Observation.

Consequences of the current PET/CT examination reported here

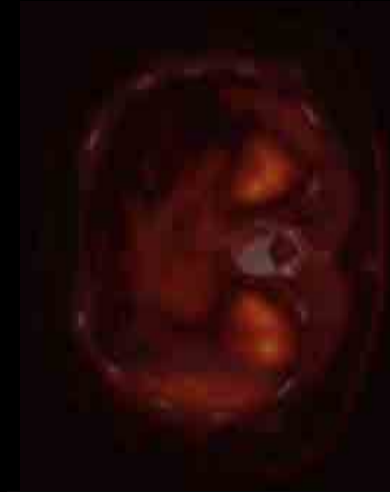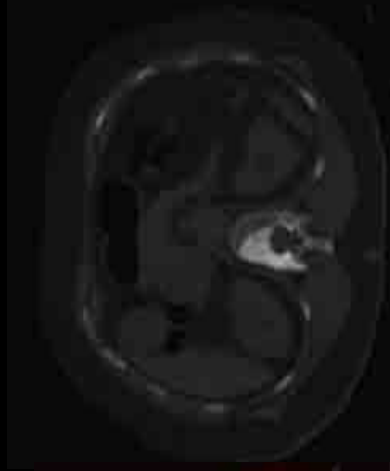
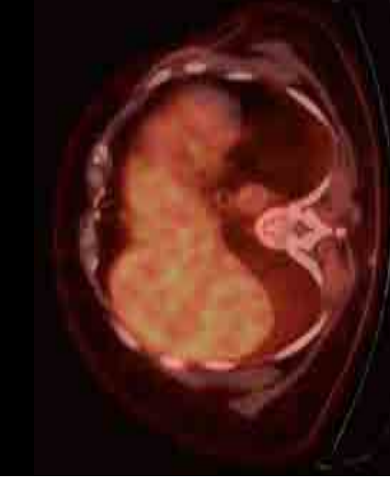No change in treatment plan.



A



B



Breast cancer

56 y/o F patient with DCIS diagnosed 3 years ago. S/p ChTxRT.

(A) FDG-PET/CT for restaging shows several hepatic, osseous and LN metastasis.

(B) FDG-PET/CT for therapy follow-up show CMR and morphological response.

5.8. CASE NO. TH BR 8

Study type:	Oncology	Clinical indication:	Breast cancer
Clinical indication for PET/CT:	Initial staging and monitoring therapy response		
Keywords:	Breast cancer Osseous metastases Therapy response		
PET/CT system:	Philips TF64	Tracer:	FDG
Uptake:	64 min	Dose:	306 MBq
Range:	WB	Blood glucose:	5.5 mmol/L
No. beds:	9	Min/bed:	1
Tube loading:	120 mAs	Tube voltage:	120 kVp

Short clinical history

A 41 year old female patient with history of breast cancer treated with lumpectomy and ALND. FDG–PET/CT requested after surgery owing to high risk of metastatic disease.

PET/CT findings

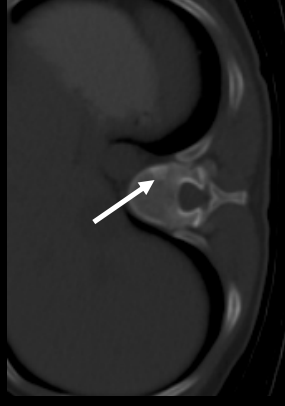
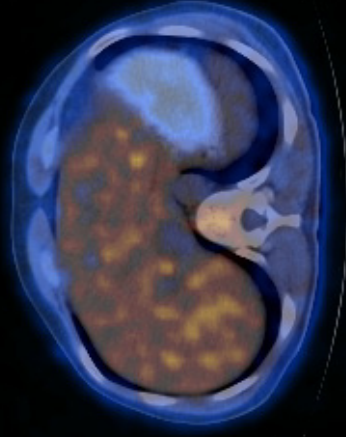
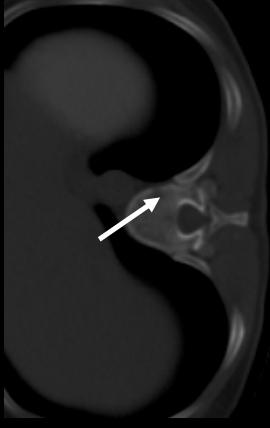
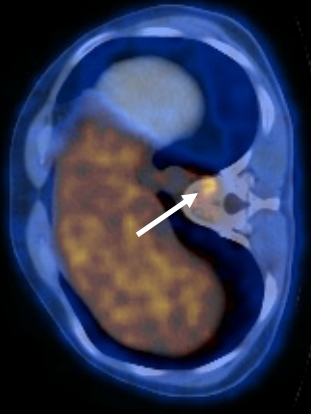
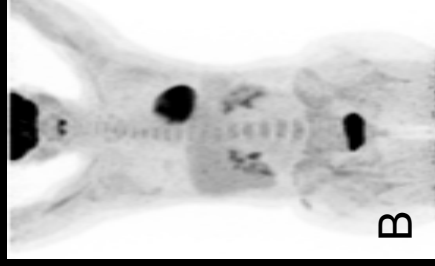
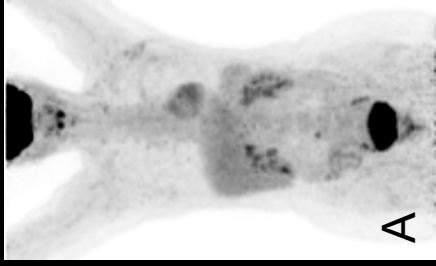
- (A) FDG–PET/CT for initial staging shows small FDG avid lytic lesions in the Th11 and L5 vertebra. MRI confirmed osseous metastasis, which was treated with ChTx (Taxotere-Herceptine).
- (B) FDG–PET/CT for restaging indicates CMR and progressive sclerosis of the osseous metastasis, indicating healing with morphological response.

Follow-up

Additional imaging and ChTx with curative intent.

Consequences of the current PET/CT examination reported here

No change in treatment plan.



Breast cancer

41 y/o F patient diagnosed with breast cancer s/p lumpectomy and ALND.

(A) FDG-PET/CT requested for initial staging shows two small FDG avid lytic vertebral lesions.

(B) FDG-PET/CT (post-ChTx) requested for restaging indicates CMR and sclerosis of the osseous metastasis.

5.9. CASE NO. TH BR 9

Study type:	Oncology	Clinical indication:	Breast cancer
Clinical indication for PET/CT:	Restaging		
Keywords:	Breast cancer Pitfall		
PET/CT system:	Philips TF64	Tracer:	FDG
Uptake:	55 min	Dose:	368 MBq
Range:	WB	Blood glucose:	5.2 mmol/L
No. beds:	9	Min/bed:	1
Tube loading:	50 mAs	Tube voltage:	120 kVp

Short clinical history

A 31 year old female patient with history of left-sided breast cancer. The patient was treated with lumpectomy and ALND in high grade DCIS located in the lower inner quadrant of the left breast.

Histology: G3, triple negative, pT1c pN0 pMx. The patient was treated with adjuvant ChTxRT.

Subsequent self-examination revealed a small nodule just medial to lumpectomy scar.

PET/CT findings

Moderate focal FDG uptake in a 15 mm irregular shaped soft tissue lesion in the lower presternal region. No evidence of other LN or organ metastasis.

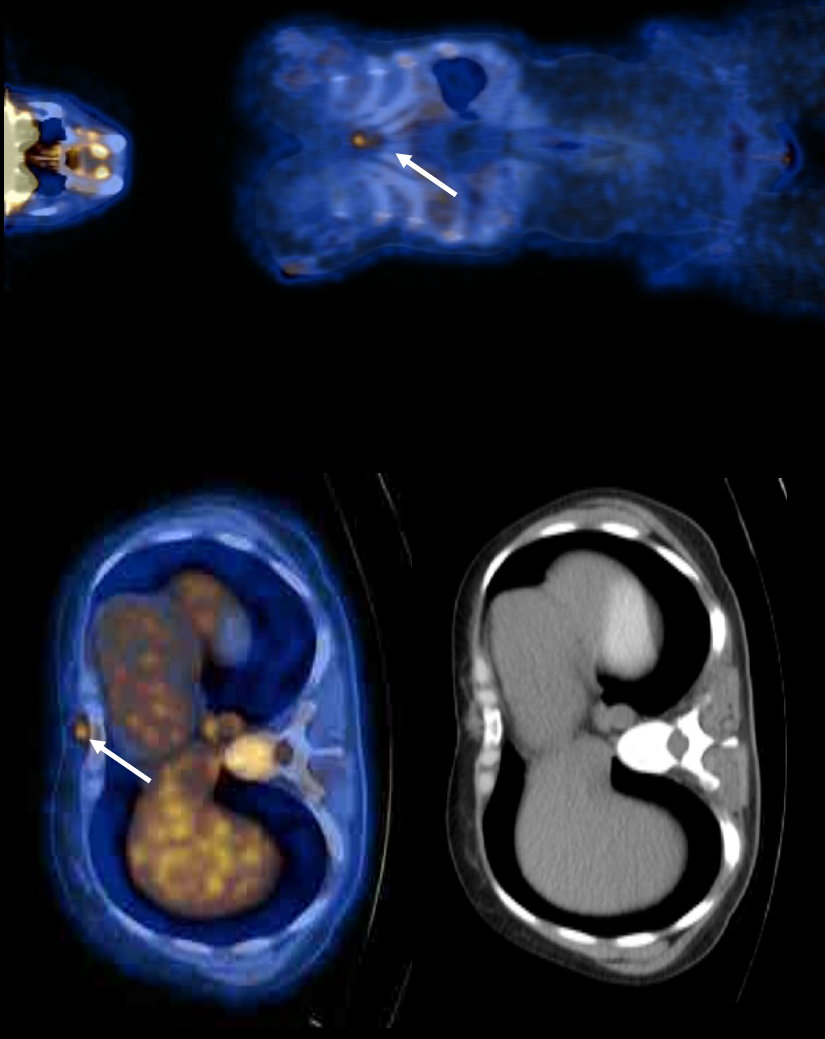
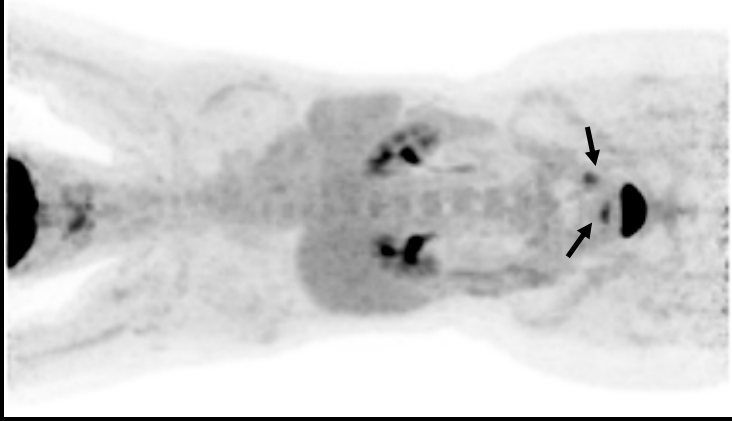
Pitfall: Focal left ovarian and endometrial uptake related to menstrual cycle (arrows in the 3-D image).

Follow-up

Treatment: Surgery plus ChTxRT with curative intent.

Consequences of the current PET/CT examination reported here

Change in treatment plan.



Breast cancer

31 y/o F patient with history of left breast cancer treated with lumpectomy, ALND and adjuvant ChTxRT 3 years ago.

FDG-PET/CT requested for restaging shows FDG avid prestermal soft tissue lesion.

Pitfall (black arrows): Physiological left ovarian and uterine uptake.

5.10. CASE NO. TH BR 10

Study type:	Oncology	Clinical indication:	Breast cancer
Clinical indication for PET/CT:	Restaging		
Keywords:	Breast cancer Second primary cancer		
PET/CT system:	Philips TF64	Tracer:	FDG
Uptake:	56 min	Dose:	419 MBq
Range:	WB	Blood glucose:	5.4 mmol/L
No. beds:	9	Min/bed:	1.5
Tube loading:	150 mAs	Tube voltage:	120 kVp

Short clinical history

A 61 year old female patient with breast cancer diagnosed 3 years ago was treated with ALND.

Histology: Invasive carcinomatosis of breast cancer. Treated with ChTx. FDG–PET/CT is requested for restaging.

PET/CT findings

(A) FDG–PET/CT demonstrates a large FDG avid lung lesion in the right lower lobe.

She was treated surgically, demonstrating adenosquamous carcinoma (second primary tumour).

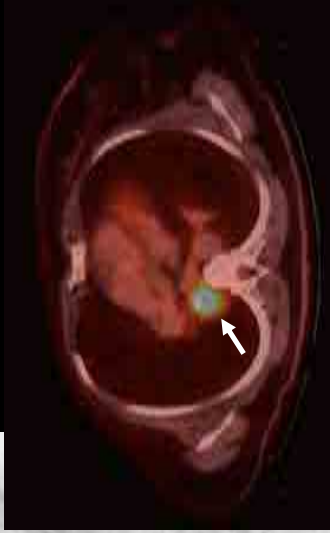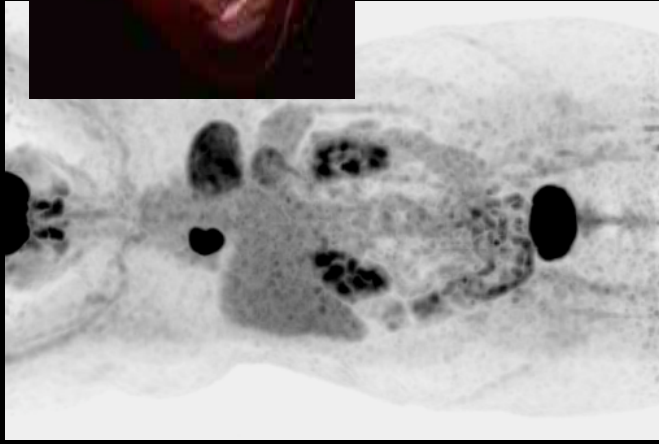
(B) FDG–PET/CT requested for follow-up shows moderately increased focal uptake at the surgical resection site without morphological correlate. A 3 month follow-up was recommended to exclude recurrence.

Follow-up

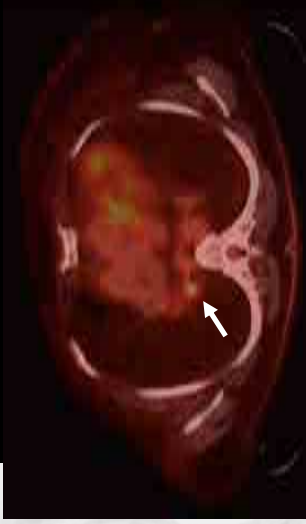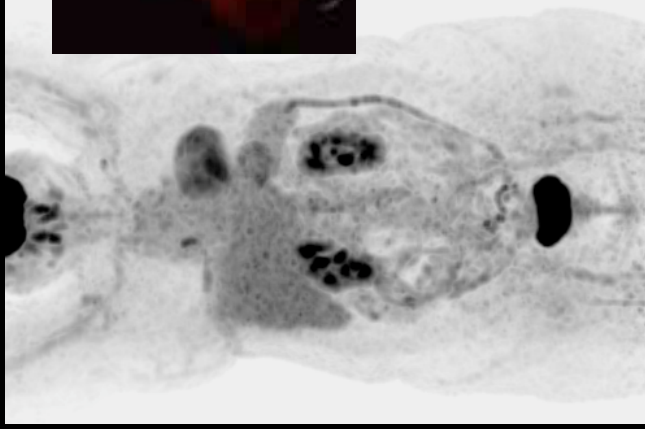
Observation.

Consequences of the current PET/CT examination reported here

No change in treatment plan.



A



B

Breast cancer

61 y/o F patient with breast cancer diagnosed 3 years ago. S/p ALND 2 years ago. FDG-PET/CT requested for restaging.

(A) FDG-PET/CT requested for restaging shows right lung FDG avid lesion.

(B) FDG-PET/CT requested for follow-up post resection of secondary lung cancer shows mildly increased focal uptake in surgical resection area.

6. THORAX: LUNG

6.1. CASE NO. TH LU 1

Study type:	Oncology	Clinical indication:	SPN
Clinical indication for PET/CT:	Initial staging		
Keywords:	SPN Lung cancer		
PET/CT system:	Philips TF 64	Tracer:	FDG
Uptake:	58 min	Dose:	296 MBq
Range:	WB	Blood glucose:	5.4 mmol/L
No. beds:	9	Min/bed:	1
Tube loading:	120 mAs	Tube voltage:	100 kVp

Short clinical history

A 56 year old male patient presented with chronic cough. A CT scan of the chest demonstrated 30 × 21 mm lesion in the right upper lobe and a 14 mm LN in the right hilum. Subsequently, the bronchoscopy was negative. TLB and TBB were non-diagnostic. The lung mass was resected and histology confirmed it to be bronchoalveolar cancer.

Note: Iatrogenic PTX on the right.

PET/CT findings

Moderately increased FDG uptake in the right upper lobe mass corresponding to the bronchoalveolar cancer. However, there is no evidence of nodal involvement or distant metastasis.

Note: Iatrogenic PTX on the right.

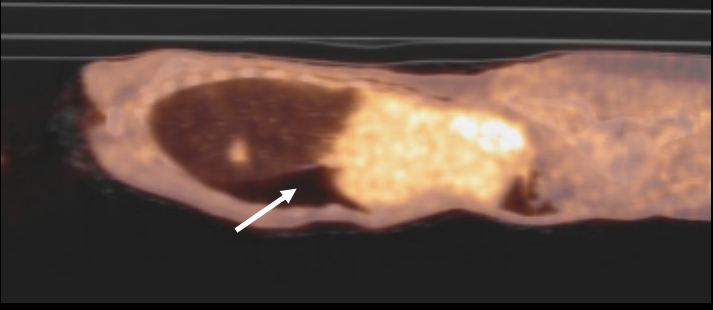
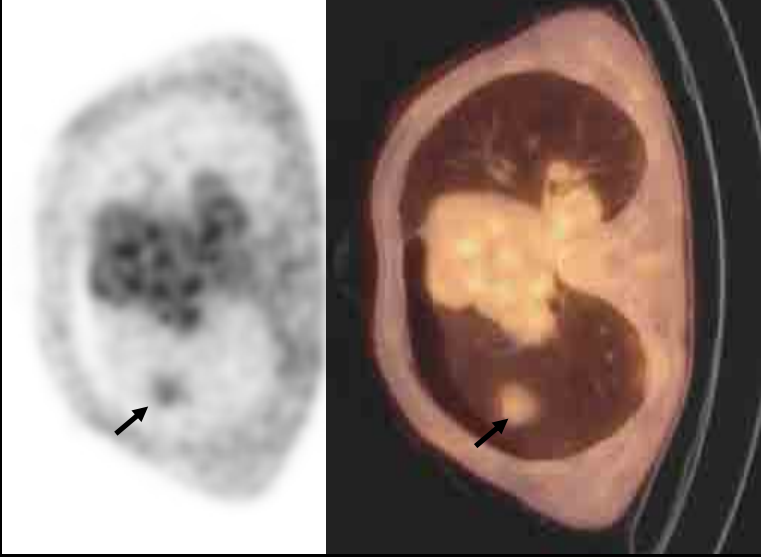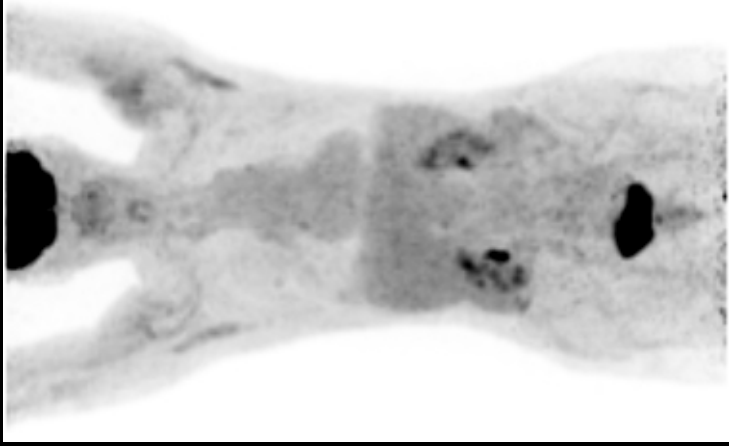
Impression: Moderate FDG avidity in non-dense soft tissue mass in the right upper lobe, secondary to the bronchoalveolar cancer (confirmed by histology).

Follow-up

Treatment: Surgery with curative intent.

Consequences of the current PET/CT examination reported here

Change in treatment plan.



Solitary pulmonary nodule

56 y/o M patient with SPN after non-diagnostic TBB and TLB.

FDG-PET/CT requested for initial staging demonstrates only marginal FDG uptake compared to mediastinal blood pool in the right upper lobe lesion.

Note: Iatrogenic PTX on the right side post biopsy.

6.2. CASE NO. TH LU 2

Study type:	Oncology	Clinical indication:	SPN
Clinical indication for PET/CT:	Initial staging		
Keywords:	SPN Lung cancer		
PET/CT system:	Philips TF 64	Tracer:	FDG
Uptake:	62 min	Dose:	366 MBq
Range:	WB	Blood glucose:	8.7 mmol/L
No. beds:	9	Min/bed:	1.5
Tube loading:	120 mAs	Tube voltage:	100 kVp

Short clinical history

A 62 year old female patient with history of COPD. A pulmonary nodule was incidentally detected on a chest X ray. CECT shows 12 mm spiculated round nodule, which is suspicious for neoplasm. In addition, there are two undetermined LN in the right hilum.

PET/CT findings

FDG–PET/CT requested for initial staging and characterization of the SPN shows increased FDG avidity in the right lung nodule. However, there is no pathological activity in the LNs or in other mediastinal areas.

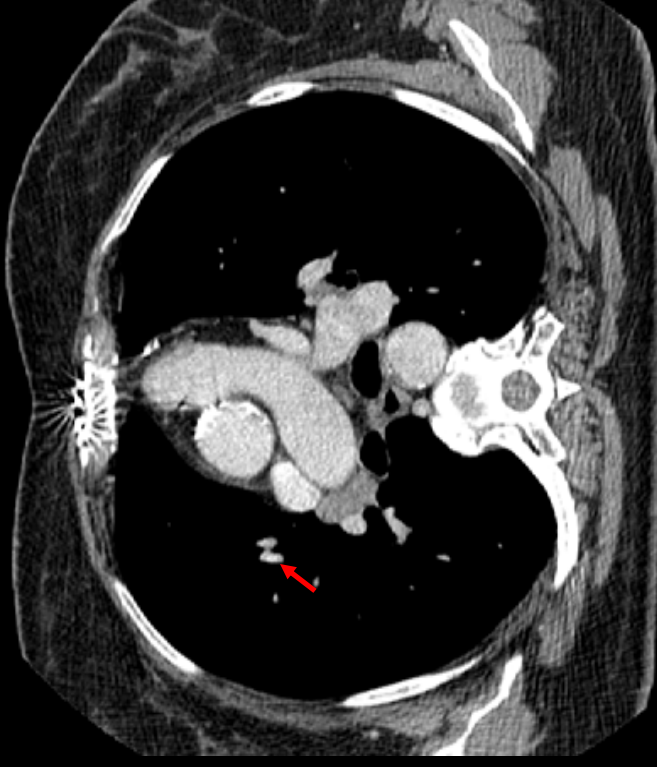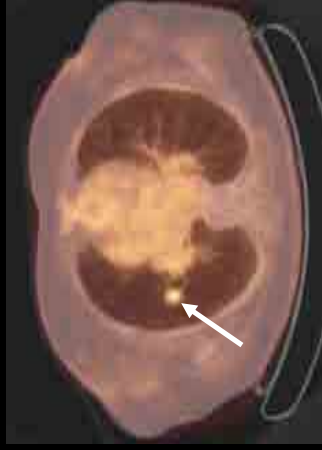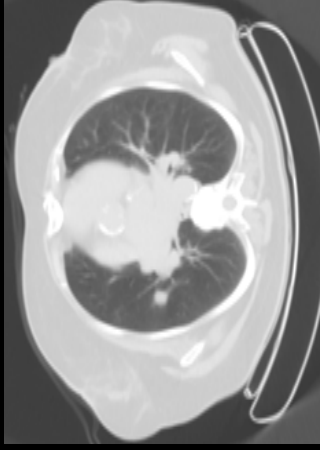
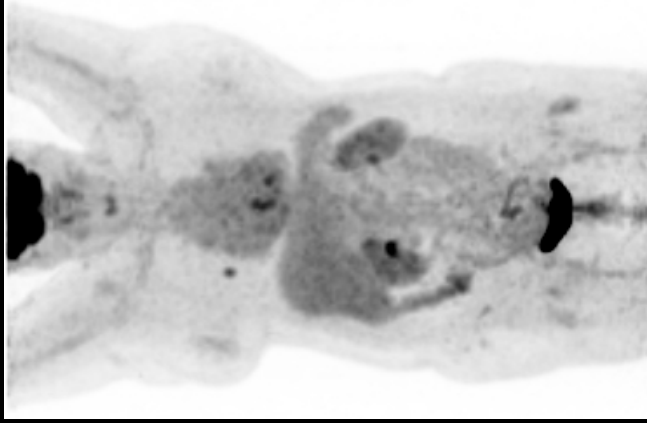
Histologically the pulmonary nodule was confirmed to be adenocarcinoma, with the following staging pT1a pN0 pMx.

Follow-up

Treatment: Surgery with curative intent.

Consequences of the current PET/CT examination reported here

Downstage of disease and change in treatment plan.



Solitary pulmonary nodule

62 y/o F patient with history of COPD. Incidental finding on chest X ray. Subsequent CT suspicious for malignancy. FDG-PET/CT requested for staging reveals FDG avid nodule (arrow) in the right upper lobe consistent with malignant process. No significant uptake in the LNs of the right hilum seen on CECT: cT1 cN0 cM0.

6.3. CASE NO. TH LU 3

Study type:	Oncology	Clinical indication:	Lung cancer
Clinical indication for PET/CT:	Initial staging		
Keywords:	Multiple metastases Lung cancer		
PET/CT system:	Philips TF 64	Tracer:	FDG
Uptake:	60 min	Dose:	316 MBq
Range:	WB	Blood glucose:	4.6 mmol/L
No. beds:	9	Min/bed:	1
Tube loading:	120 mAs	Tube voltage:	100 kVp

Short clinical history

A 72 year old male patient with severe weight loss, weakness and a cough. CECT of the chest demonstrated a centrally located left side lung cancer with enlarged mediastinal LNs. Bronchoscopy with biopsy proved positive for adenocarcinoma. FDG–PET/CT was requested for initial staging.

PET/CT findings

FDG–PET/CT shows a centrally located left-sided lung tumour with high FDG uptake. Surrounding lung parenchyma shows a fibronodular pattern with high FDG uptake. Left-sided pleural effusion. Pathologically enlarged infracarinal LNs and other multiple FDG avid mediastinal and right supraclavicular metastasis. Focal FDG avid mass in the left adrenal gland. Several FDG avid osseous lesions (e.g. left lower pubic bone).

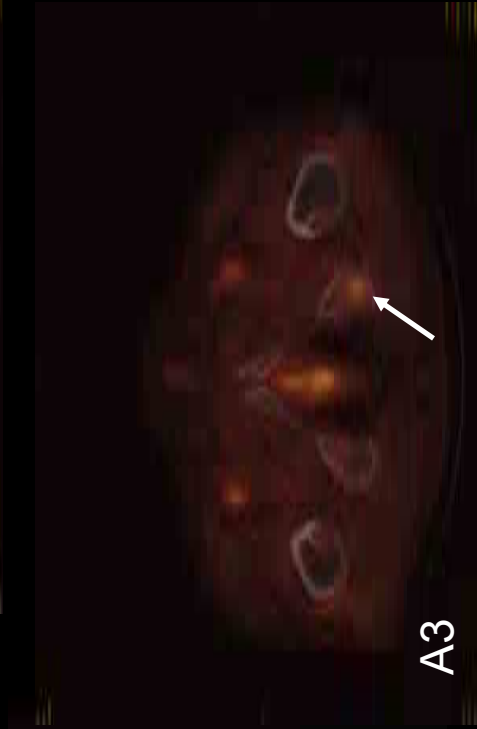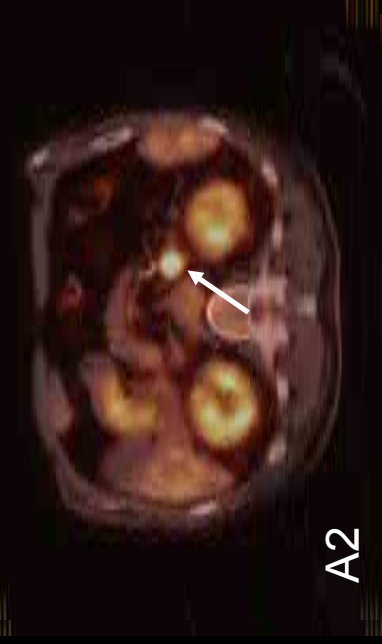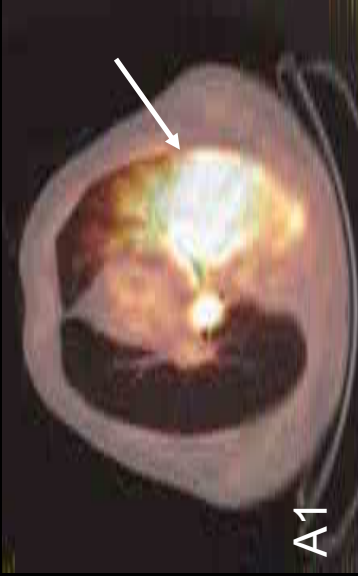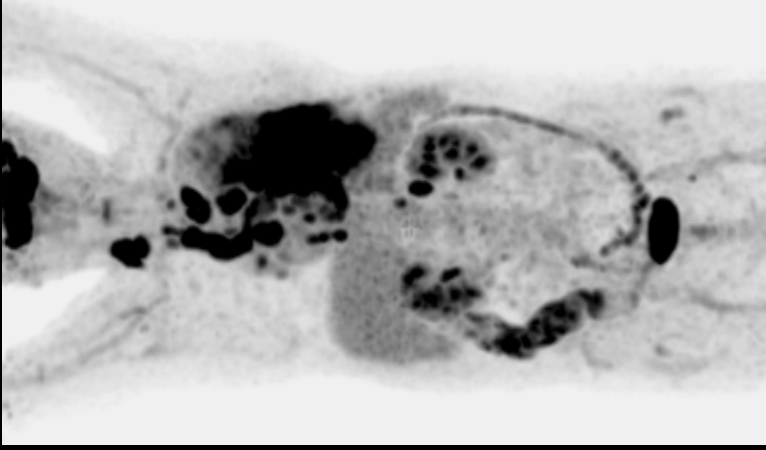
Impression: Lung cancer with lymphangitis carcinomatosa and multiple LN metastases with left adrenal and osseous metastasis.

Follow-up

Treatment: ChTx with palliative intent.

Consequences of the current PET/CT examination reported here

Upstage of disease and change in treatment plan.



Lung cancer

72 y/o M patient with NSCLC.

FDG-PET/CT requested for staging shows disseminated disease, with lymphangitis carcinomatosa and pleural carcinomatosis (A1), left adrenal gland (A2) and osseous metastasis (A3).

6.4. CASE NO. TH LU 4

Study type:	Oncology	Clinical indication:	Lung cancer
Clinical indication for PET/CT:	Restaging		
Keywords:	Osseous metastases Lung cancer		
PET/CT system:	Philips TF 64	Tracer:	FDG
Uptake:	64 min	Dose:	366 MBq
Range:	WB	Blood glucose:	4.0 mmol/L
No. beds:	9	Min/bed:	1.5
Tube loading:	120 mAs	Tube voltage:	150 kVp

Short clinical history

A 63 year old female patient diagnosed with a left upper lobe adenocarcinoma 2 years ago. S/p lobectomy with no additional adjuvant treatment.

Histology: pT1 pN1 pMx, G3.

The patient presented with back pain. An MRI demonstrated an indeterminate lesion in the Th1 vertebra.

PET/CT findings

FDG–PET/CT requested for restaging purposes shows focal intense FDG uptake in the right aspect of the Th1 vertebral body, consistent with osseus metastasis lesion located on an 8 mm lytic area on the CT image.

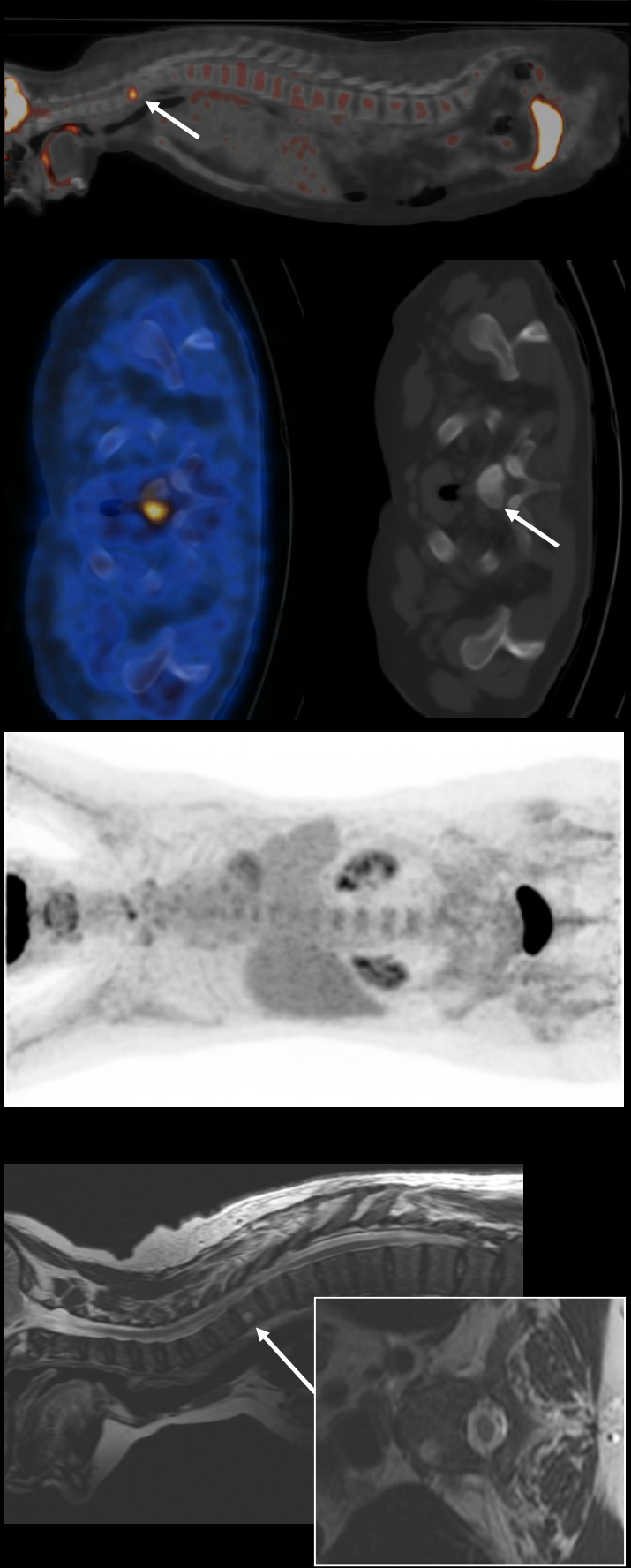
Impression: Lytic osseous metastasis in lytic metastatic Th1 vertebra.

Follow-up

Treatment: RTx with palliative intent.

Consequences of the current PET/CT examination reported here

Upstage of disease and change in treatment plan.



Lung cancer

63 y/o F patient diagnosed with left upper lobe adenocarcinoma 2 years ago. 1 year s/p left superior lobectomy without adjuvant therapy. MRI following complaints of back pain: discus hernia (Th6) and indeterminate lesion in the Th1 vertebra.

FDG-PET/CT requested for restaging shows focal FDG uptake in a lytic lesion in the Th1 consistent with osseous metastasis.

6.5. CASE NO. TH LU 5

Study type:	Oncology	Clinical indication:	Lung cancer
Clinical indication for PET/CT:	Initial staging		
Keywords:	LN metastases Lung cancer		
PET/CT system:	Philips TF 64	Tracer:	FDG
Uptake:	59 min	Dose:	318 MBq
Range:	WB	Blood glucose:	4.8 mmol/L
No. beds:	9	Min/bed:	1
Tube loading:	120 mAs	Tube voltage:	100 kVp

Short clinical history

A 56 year old male patient, asymptomatic, in whom a right pulmonary mass was incidentally detected on screening chest X ray.

Subsequent CT scan of the chest demonstrates a right upper lobe mass with additional paratracheal, aortopulmonary, subcarinal and bilateral hilar lymphadenopathy.

Cytology from TBLB: Adenocarcinoma.

PET/CT findings

FDG avid right upper lobe tumour with FDG avid mediastinal and right supraclavicular LNs.

Impression: Tumour stage as T2a N3 M0.

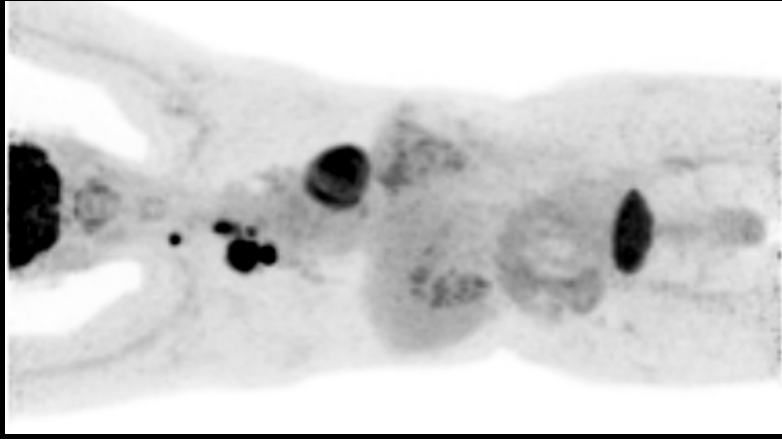
Follow-up

Tissue biopsy: Supraclavicular biopsy instead of mediastinoscopy.

Follow treatment: ChTxRT.

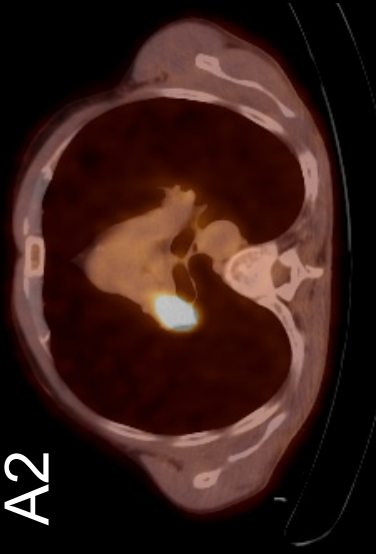
Consequences of the current PET/CT examination reported here

Upstage of disease and change in treatment plan.

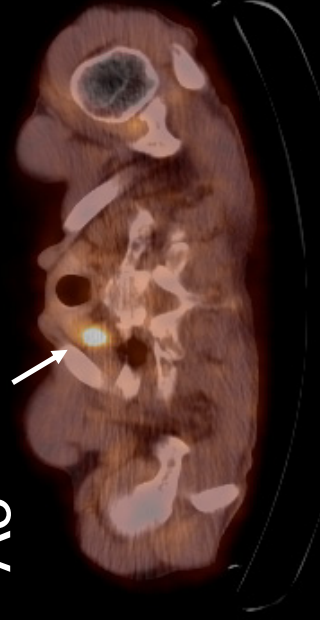

A1

A2



A3



Lung cancer

56 y/o M patient with confirmed NSCLC. Chest CT indicated right hilar and aortopulmonary adenopathy.

FDG-PET/CT requested for staging confirms CT findings (A1, A2) and shows additional right supraclavicular LN with focal FDG uptake (A3).

6.6. CASE NO. TH LU 6

Study type:	Oncology	Clinical indication:	Lung cancer
Clinical indication for PET/CT:	Restaging		
Keywords:	Pitfall Lung cancer		
PET/CT system:	Philips TF 64	Tracer:	FDG
Uptake:	58 min	Dose:	423 MBq
Range:	WB	Blood glucose:	4.7 mmol/L
No. beds:	11	Min/bed:	1.5
Tube loading:	150 mAs	Tube voltage:	120 kVp

Short clinical history

A 59 year old male patient with history of SCC diagnosed 2 years ago, followed by resection of right lower lobe and adjuvant ChTx. Follow-up CT scan 1 year ago was suggestive of tumour recurrence. FDG–PET/CT was requested for restaging.

PET/CT findings

Large FDG avid right-sided subhilar lesion is depicted. In addition, a small paracardial soft tissue mass with increased FDG uptake is also seen. There is a small focal FDG uptake in the right 4th intercostal region. Elongated diffuse FDG uptake is located in the lower third of the oesophagus.

Impression: Right-sided subhilar tumour recurrence, with paracardial metastasis.

Pitfall: Focal FDG uptake in the 4th intercostal region is the site of pleural drainage.

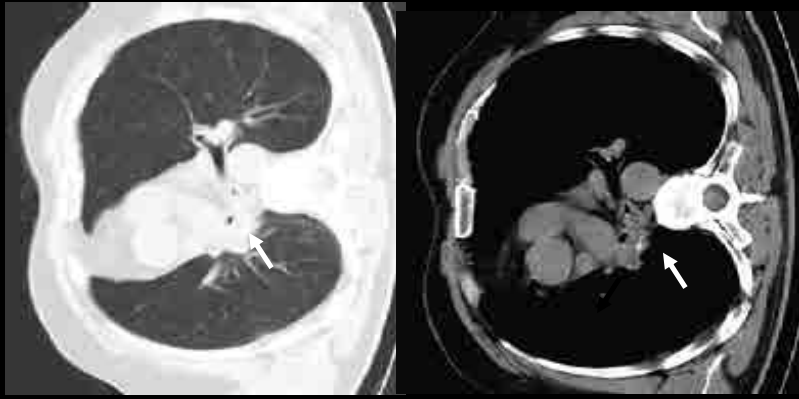
Additional finding: Oesophagitis.

Follow-up

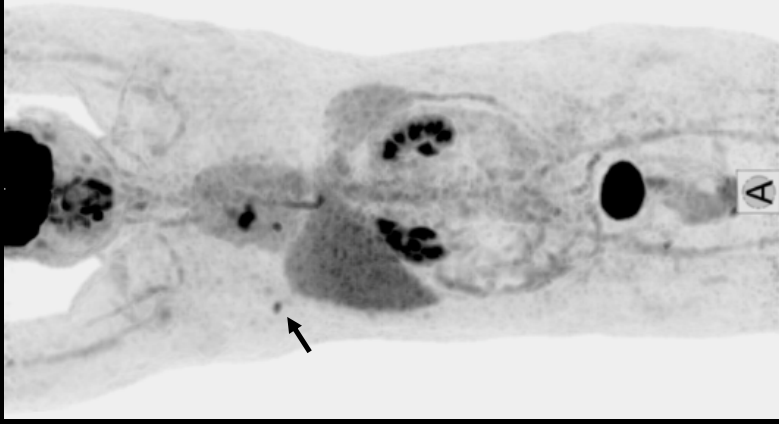
Treatment: Surgery with curative intent.

Consequences of the current PET/CT examination reported here

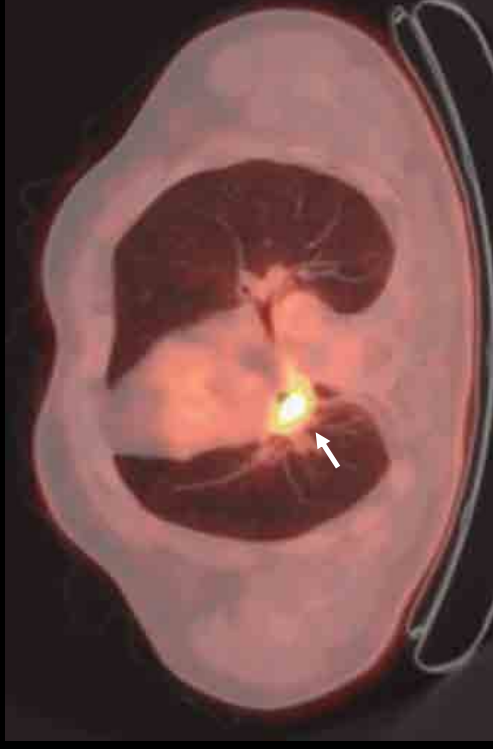
Upstage of disease and change in treatment plan.



A



B



Lung cancer

59 y/o M patient with history of SCC diagnosed 2 years ago. S/p resection and adjuvant ChTx. Follow-up CT 1 year ago suggestive of recurrence (A).

FDG-PET/CT (B) requested for restaging shows right subhilar FDG avid lesion. Additional right paracardial lesion.

Pitfall: FDG uptake after pleural drainage (black arrow).

6.7. CASE NO. TH LU 7

Study type:	Oncology	Clinical indication:	Lung cancer
Clinical indication for PET/CT:	Restaging		
Keywords:	Lung cancer Secondary cancer		
PET/CT system:	Philips TF 64	Tracer:	FDG
Uptake:	57 min	Dose:	262 MBq
Range:	WB	Blood glucose:	4.2 mmol/L
No. beds:	9	Min/bed:	1
Tube loading:	120 mAs	Tube voltage:	100 kVp

Short clinical history

A 56 year old female patient with a history of right-sided breast cancer. S/p ChTxRT 5 years ago. Follow-up CECT scan revealed a soft tissue mass in the right lung. FDG-PET/CT was requested for characterization of the mass and for restaging.

PET/CT findings

PET/CT shows a spiculated soft tissue mass in the right lung with intense FDG uptake. Two enlarged LNs in the right are moderately FDG avid.

Impression: New right lung cancer (second primary) with right hilar LN metastasis. However, there is no evidence of distant metastatic involvement.

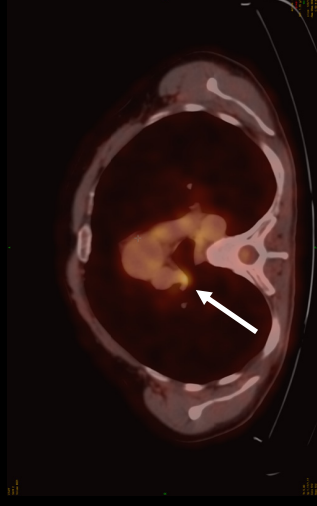
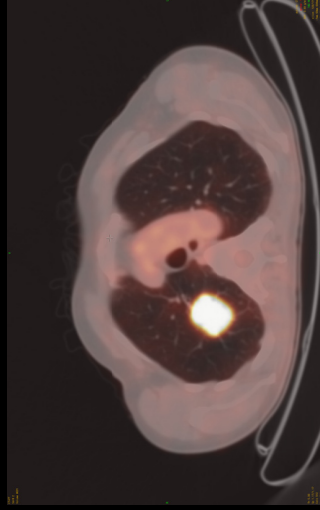
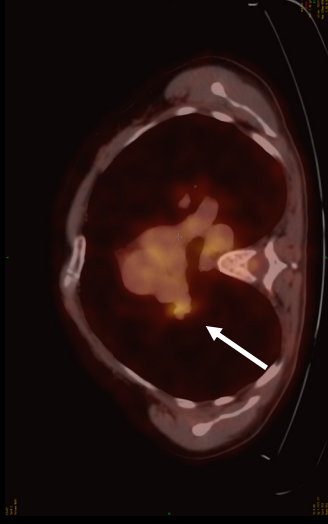
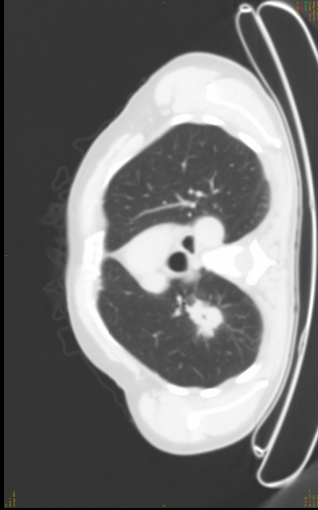
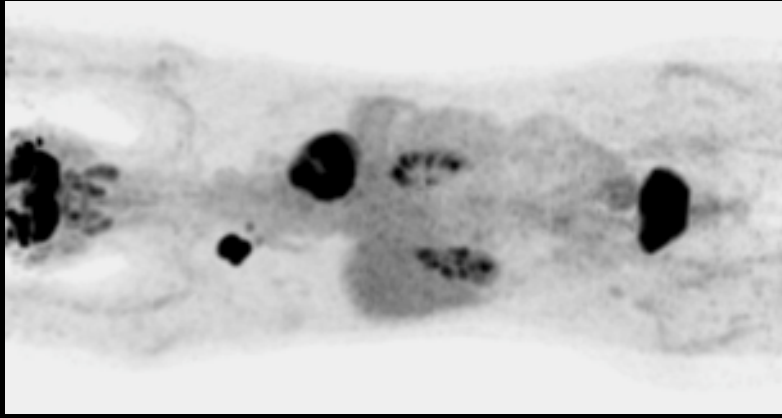
Follow-up

Tissue biopsy.

Treatment: Surgery with curative intent.

Consequences of the current PET/CT examination reported here

Change in treatment plan.



Lung cancer

56 y/o F patient diagnosed with breast cancer 5 years ago. Follow-up imaging shows right pulmonary lesion. FDG-PET/CT requested for restaging shows high FDG uptake in right pulmonary soft tissue mass with two FDG avid right hilar LN's (arrows).

6.8. CASE NO. TH LU 8

Study type:	Oncology	Clinical indication:	Lung cancer
Clinical indication for PET/CT:	Restaging		
Keywords:	Lung cancer Therapy response		
PET/CT system:	Philips TF 64	Tracer:	FDG
Uptake:	57 min	Dose:	585 MBq
Range:	WB	Blood glucose:	6.6 mmol/L
No. beds:	7	Min/bed:	1
Tube loading:	100 mAs	Tube voltage:	120 kVp

Short clinical history

A 49 year old female patient with histologically confirmed NSCLC. S/p ChTxRT. FDG–PET/CT was requested for restaging purposes.

PET/CT findings

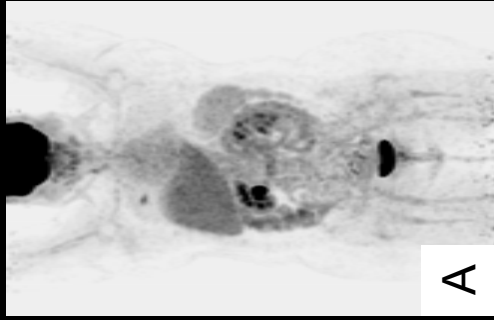
- (A) Demonstrates locally recurrent right upper lobe malignancy.
- (B) Follow-up FDG–PET/CT scan without evidence of residual mass.
Scar tissue in the right pulmonary base.

Follow-up

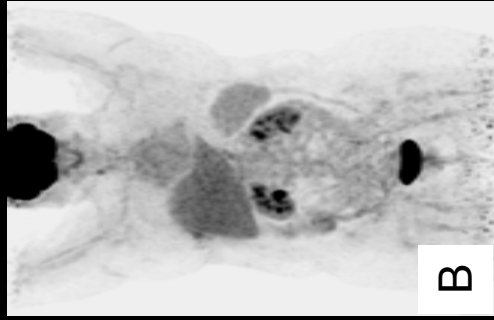
Treatment: Surgery with curative intent.

Consequences of the current PET/CT examination reported here

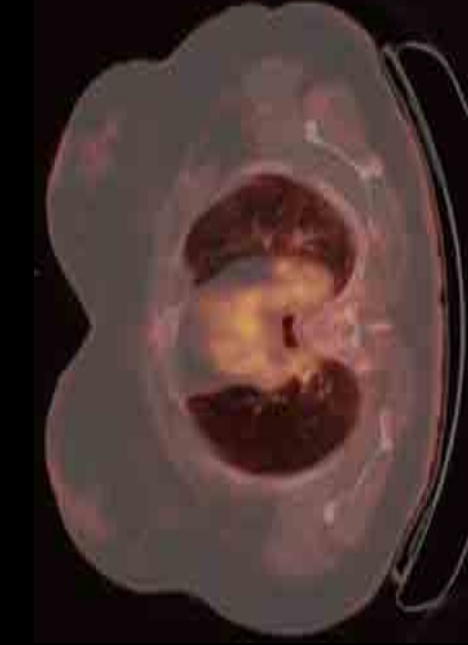
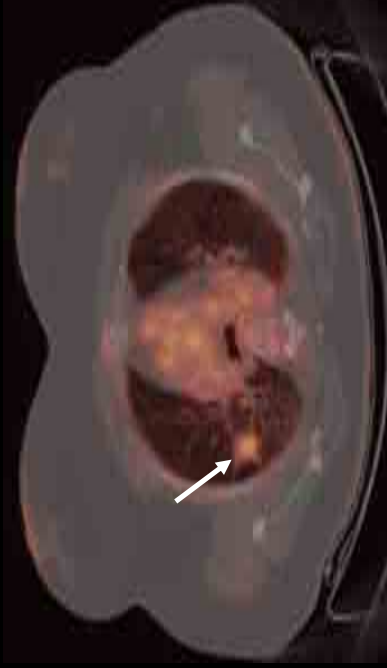No change in treatment plan.



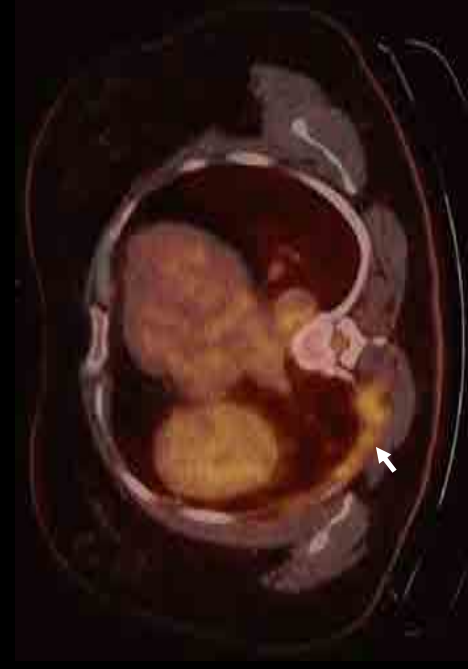A1



B1



B2



Lung cancer

49 y/o F patient with lung cancer in right upper lobe and mediastinal LN involvement. S/p ChTx.

(A) FDG–PET/CT requested for restaging: FDG avid pulmonary tumour (A1).

(B) Follow-up FDG–PET/CT: no residual mass (B1), scar tissue on the right pulmonary basis (B2).

6.9. CASE NO. TH LU 9

Study type:	Oncology	Clinical indication:	Lung cancer
Clinical indication for PET/CT:	Initial staging		
Keywords:	Lung cancer LN metastasis Osseous metastasis		
PET/CT system:	Philips TF 64	Tracer:	FDG
Uptake:	61 min	Dose:	481 MBq
Range:	WB	Blood glucose:	4.6 mmol/L
No. beds:	9	Min/bed:	1.5
Tube loading:	120 mAs	Tube voltage:	100 kVp

Short clinical history

A 62 year old female patient, asymptomatic, who presented with a right upper lobe mass incidentally discovered during chest X ray. Subsequent CT scan of the chest depicted a soft tissue mass in the right upper lobe as well as multiple mediastinal LNs.

TBLB: Adenocarcinoma.

The patient was referred for PET/CT for initial staging prior to surgery.

PET/CT findings

Large FDG avid right upper lobe tumour mass. Intense FDG uptake in several right paratracheal and pretracheal mediastinal nodes. Several FDG avid osseous metastases are identified (e.g. in the right 4th rib, right iliac bone and left side of the pelvis).

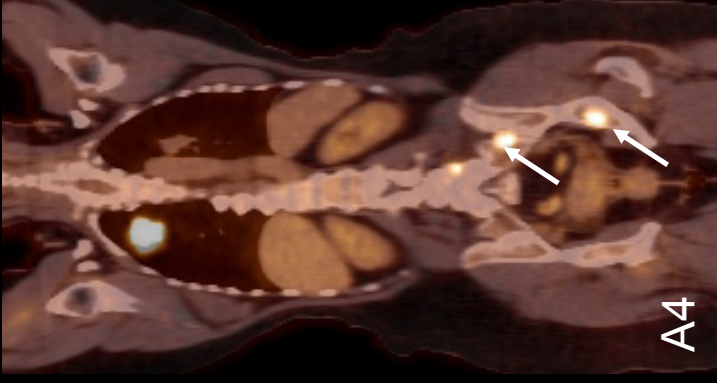
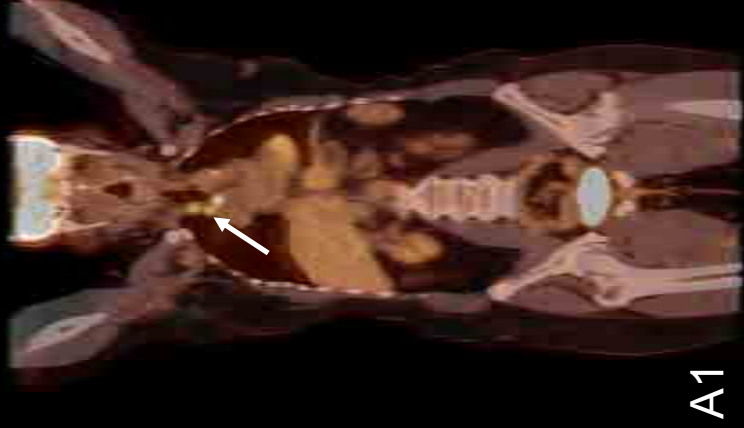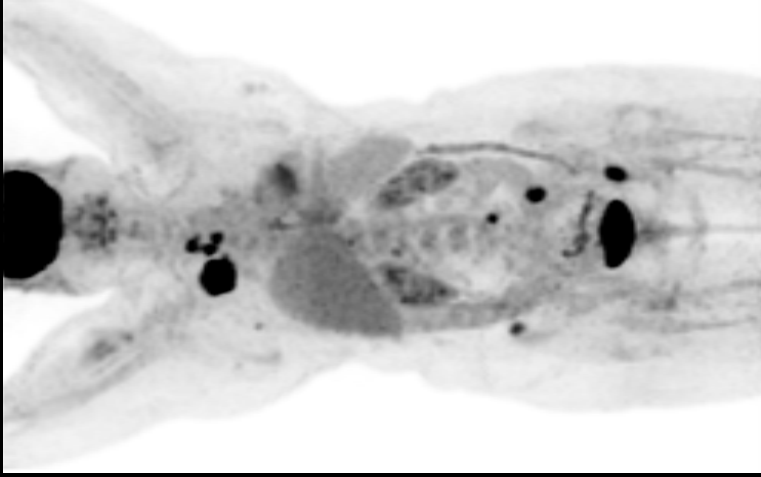
Impression: Lung cancer with mediastinal and osseous metastasis.

Follow-up

Treatment: ChTxRT with palliative intent.

Consequences of the current PET/CT examination reported here

Upstage of disease and change in treatment plan.



Lung cancer

62 y/o F patient for primary staging of NSCLC.

FDG-PET/CT requested for initial staging shows right paratracheal and pretracheal (A1) metastases, a large right upper lobe tumour (A2) and multiple osseous metastasis (A3 and A4).

6.10. CASE NO. TH LU 10

Study type:	Oncology	Clinical indication:	Lung cancer
Clinical indication for PET/CT:	Initial staging		
Keywords:	Lung cancer LN metastasis Screening		
PET/CT system:	Philips TF 64	Tracer:	FDG
Uptake:	55 min	Dose:	259 MBq
Range:	WB	Blood glucose:	4.8 mmol/L
No. beds:	8	Min/bed:	1
Tube loading:	100 mAs	Tube voltage:	120 kVp

Short clinical history

A 67 year old female patient with an incidental finding of a mass in the right lung on screening CT. Subsequent CECT revealed a left hilar soft tissue mass with post-stenotic atelectasis and mediastinal LNs. There was evidence of additional lymph node involvement in the right lung and a soft tissue mass in the left adrenal gland.

Bronchial brush cytology showed poorly differentiated non-typable carcinoma.

PET/CT findings

FDG–PET/CT for initial staging shows centrally located left lung FDG avid tumour and FDG avid mediastinal nodes. There is no evidence of FDG uptake of the right pulmonary micronodule. Adrenal gland lesion without FDG uptake.

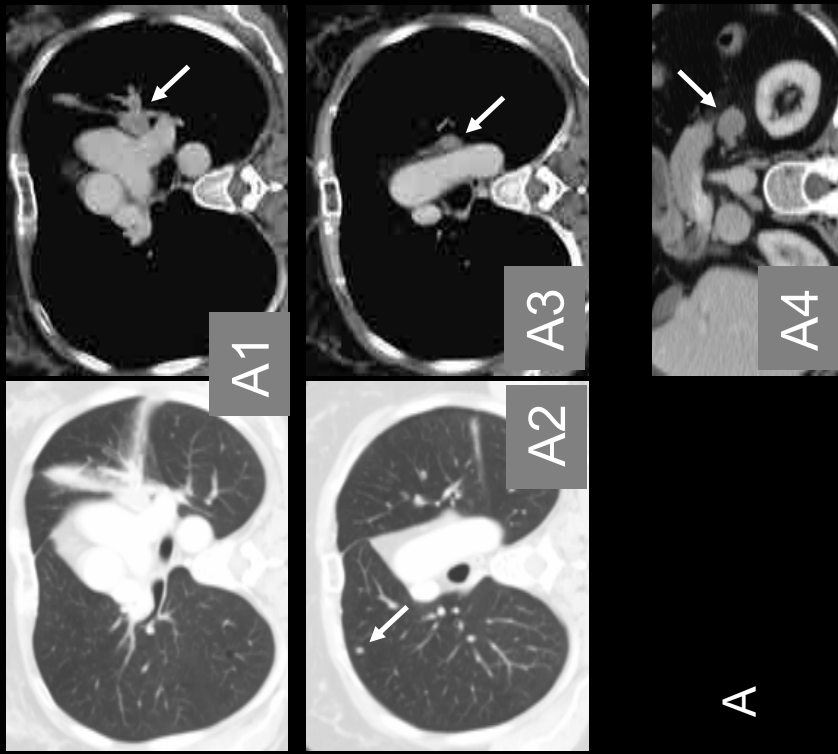
Impression: Centrally located, left lung cancer with ipsilateral mediastinal tumour involvement. Left-sided adrenal adenoma. CT scan of the chest is recommended for the right micronodule.

Follow-up

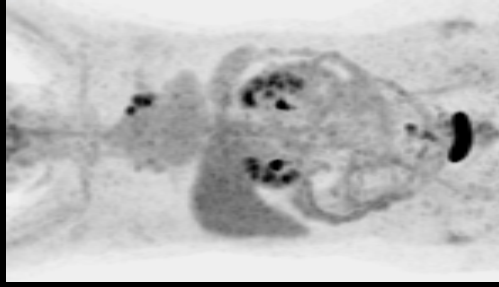
Additional imaging and treatment: Surgery with curative intent.

Consequences of the current PET/CT examination reported here

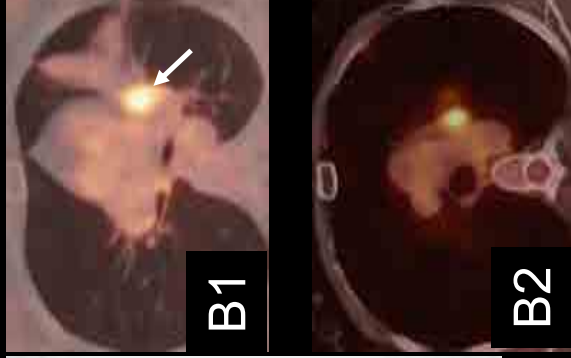
Downstage of disease and change in treatment plan.



A



B



B4

Lung cancer

67 y/o F patient with an incidental finding of a mass in the right lung on CT screening. Subsequent CECT (A) shows soft tissue mass with atelectasis to the left hilum (A1). Additional small nodule in the right lung (A2), mediastinal LN (A3) and mass in the adrenal gland (A4).

FDG-PET/CT requested for staging (B) shows FDG avidity in left hilar lesion (B1) with post-stenotic atelectasis, FDG avid mediastinal LN (B2) and pulmonary nodule (B3). No FDG uptake in the left adrenal gland (B4).

7. THORAX: MESOTHELIOMA

7.1. CASE NO. TH MES 1

Study type:	Oncology	Clinical indication:	Pleural mesothelioma
Clinical indication for PET/CT:	Initial staging		
Keywords:	Pleural mesothelioma Lung metastases		
PET/CT system:	GE Discovery 690 TOF	Tracer:	FDG
Uptake:	67 min	Dose:	240 MBq
Range:	WB	Blood glucose:	4.4 mmol/L
No. beds:	7	Min/bed:	2
Tube loading:	120 mAs	Tube voltage:	80 kVp

Short clinical history

A 62 year old male patient with recent weight loss and breathing difficulties. Outside thoracic CT scan of the chest performed at a different institution suggested the presence of a left-sided pleural mesothelioma. FDG-PET/CT was requested for staging purposes.

PET/CT findings

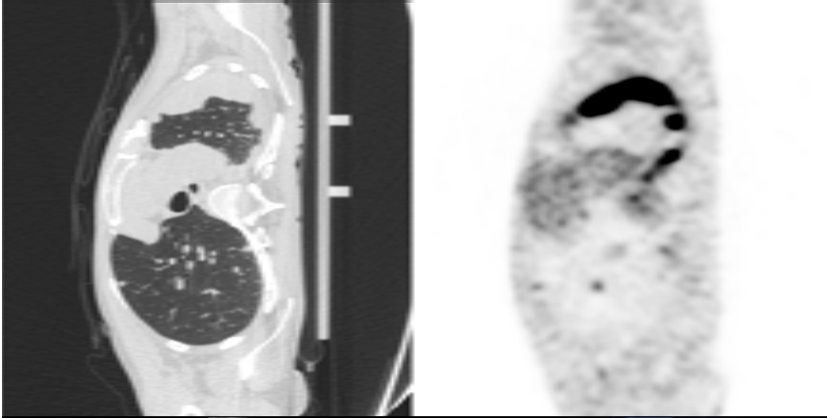
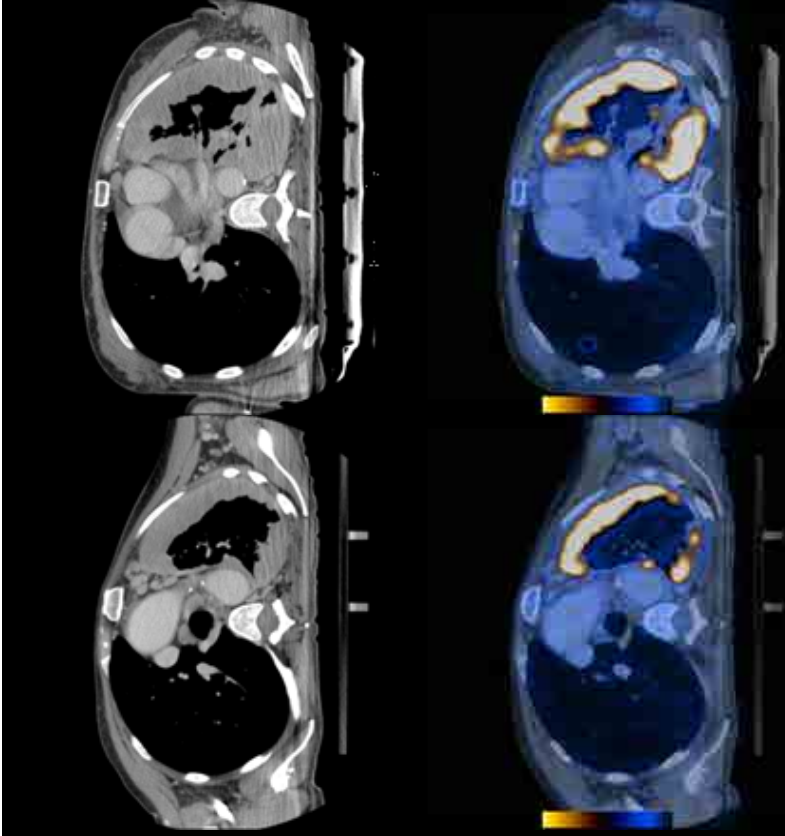
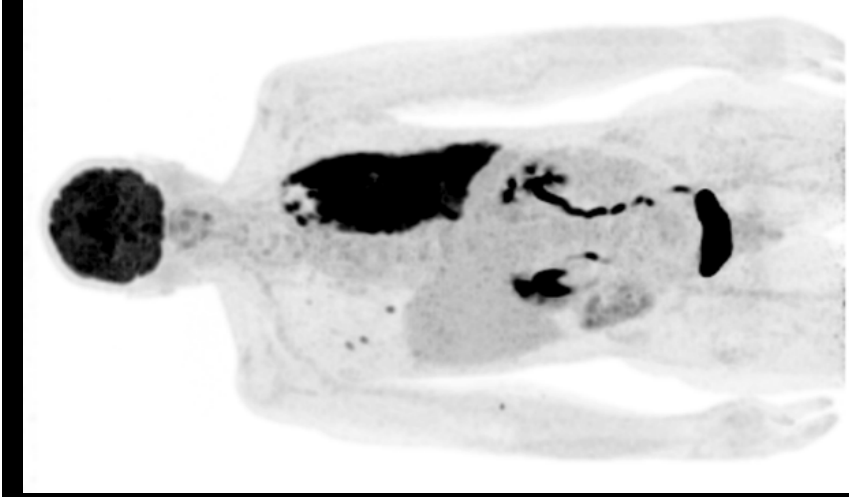
FDG-PET/CT with portal venous contrast media phase shows thick pleura of the whole left hemithorax with high glucose metabolism. Contrast media was given to define mediastinal and thoracic wall infiltration. There is also pericardial involvement as well as mediastinal LNs with elevated glucose metabolism. There are multiple contralateral pulmonary metastases within the right lung. No thoracic wall involvement could be demonstrated. No extrathoracic metastases.

Follow-up

Tissue biopsy and treatment: ChTx with palliative intent.

Consequences of the current PET/CT examination reported here

Upstage of disease and change in treatment plan.



Pleural mesothelioma

62 y/o M patient with initial diagnosis of left sided pleural mesothelioma. FDG-PET/CT was requested for staging. FDG-PET/CT shows thickened pleura of the whole left hemithorax with high glucose metabolism. In addition, pericardial involvement as well as mediastinal LN metastasis. Note the multiple contralateral pulmonary metastases. No abdominal metastases detected.

7.2. CASE NO. TH MES 2

Study type:	Oncology	Clinical indication:	Pleural mesothelioma
Clinical indication for PET/CT:	Initial staging		
Keywords:	Pleural mesothelioma Osseous metastases		
PET/CT system:	GE Discovery 690 TOF	Tracer:	FDG
Uptake:	67 min	Dose:	322 MBq
Range:	WB	Blood glucose:	6.6 mmol/L
No. beds:	7	Min/bed:	2
Tube loading:	120 mAs	Tube voltage:	80 kVp

Short clinical history

A 65 year old male patient with increasing breathing difficulties and back pain. Thoracic CT scan performed at a different institution suggested the presence of a left-sided pleural mesothelioma. Biopsy confirmed a sarcomatoid mesothelioma. FDG–PET/CT was requested for staging purposes.

PET/CT findings

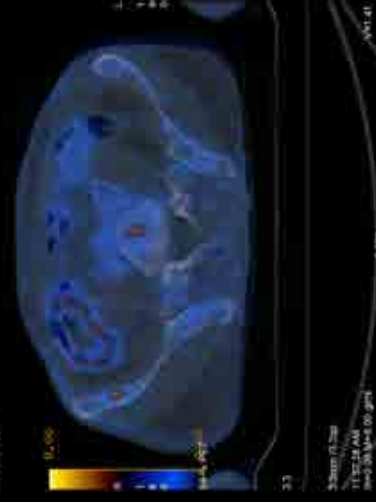
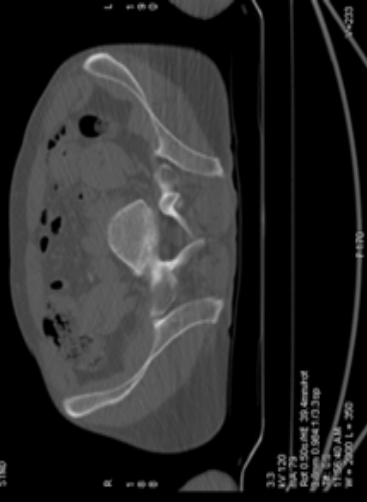
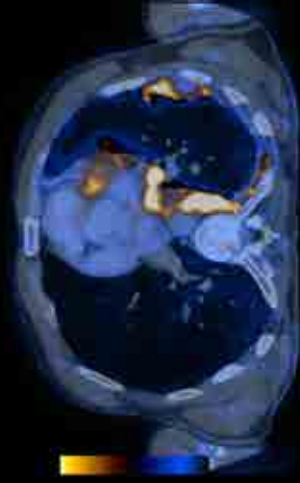
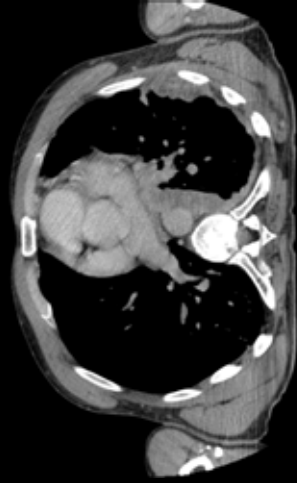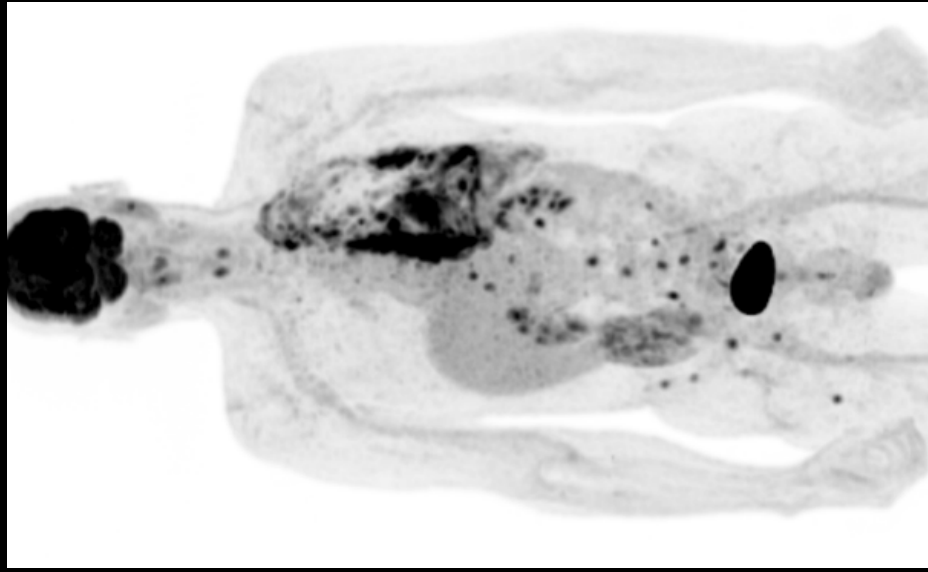
FDG–PET/CT with portal venous contrast shows partially thickened nodular pleura of the left hemithorax with high glucose metabolism. The main tumour mass is at the base of the left lung. Intravenous contrast media was given to define mediastinal and thoracic wall infiltration. There is pericardial involvement detected. In addition, multiple osseous metastases in the spine, pelvis and right thigh are also detected. Distant metastases are in line with the most aggressive type of pleural mesothelioma (sarcomatoid).

Follow-up

Treatment: ChTx with palliative intent.

Consequences of the current PET/CT examination reported here

Upstage of disease and change in treatment plan.



Pleural mesothelioma

65 y/o M patient with left-sided pleural mesothelioma. FDG-PET/CT requested for staging.

PET/CT shows a partly thickened pleura in the basal hemithorax with high glucose metabolism. In addition, there is pericardial involvement. Note multiple osseous metastases in the spine, pelvis and right thigh.

8. GASTROINTESTINAL TRACT: OESOPHAGUS

8.1. CASE NO. GI OES 1

Study type:	Oncology	Clinical indication:	Oesophageal cancer
Clinical indication for PET/CT:	Restaging		
Keywords:	Oesophageal cancer LN metastasis		
PET/CT system:	Philips TF64	Tracer:	FDG
Uptake:	55 min	Dose:	317 MBq
Range:	WB	Blood glucose:	5.6 mmol/L
No. beds:	10	Min/bed:	1
Tube loading:	1500 mAs	Tube voltage:	120 kVp

Short clinical history

A 58 year old male patient diagnosed with oesophageal cancer. There was no evidence of metastatic disease on a CECT scan at the time of initial diagnosis. Patient was initially treated with RTx. Afterwards an FDG–PET/CT scan was requested for restaging purposes.

PET/CT findings

FDG–PET/CT scan shows intense FDG uptake in the middle third of the oesophagus consistent with the primary. In addition, there is evidence of intense FDG uptake in the left supraclavicular region, highly suspicious of the nodal metastases.

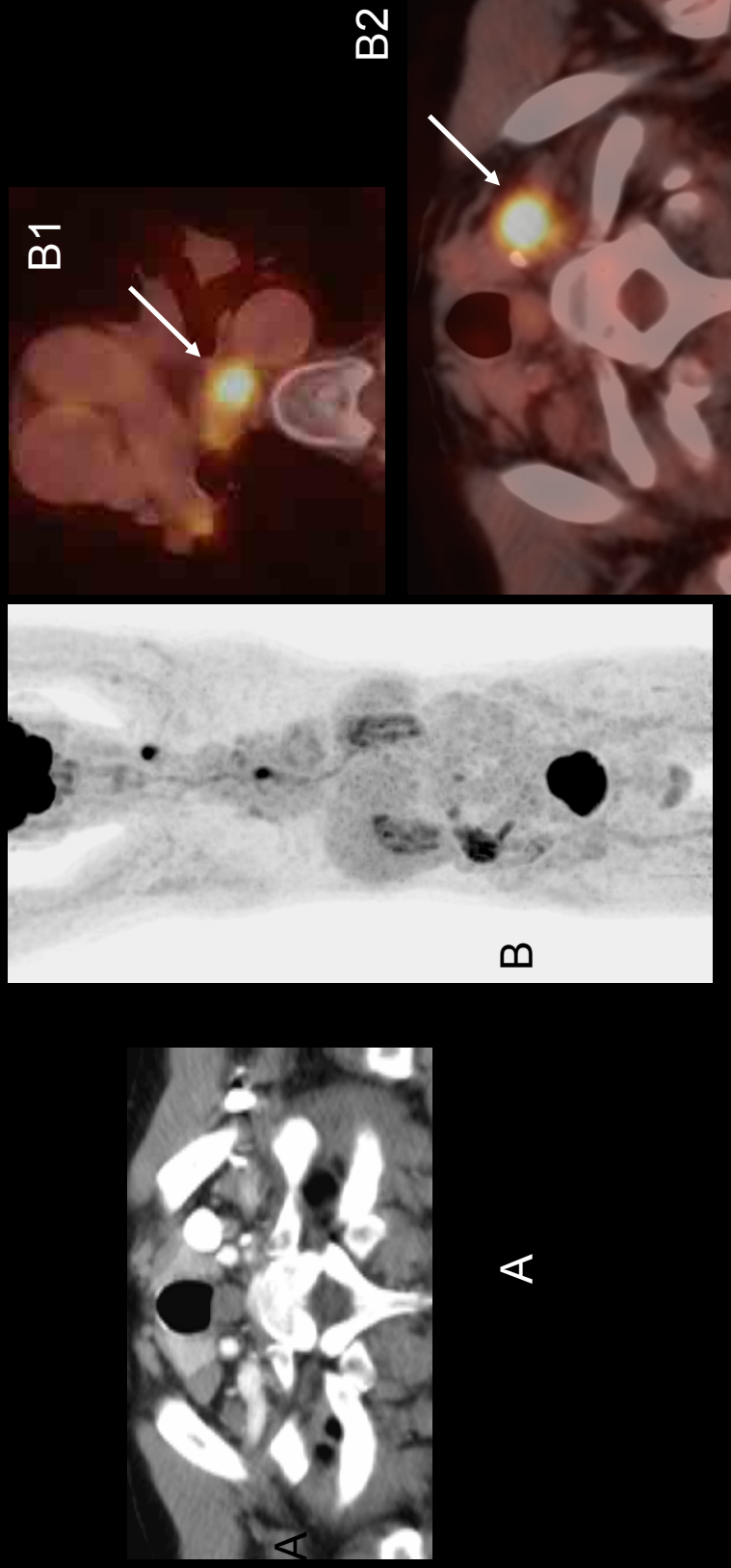
Impression: Residual primary tumour of the middle third of the oesophagus and left supraclavicular metastasis (Virchow LN).

Follow-up

Treatment: ChTx with curative intent.

Consequences of the current PET/CT examination reported here

Upstage of disease and change in treatment plan.



Oesophageal cancer

58 y/o M patient diagnosed with oesophageal cancer. No evidence of metastatic disease on CECT (A) at initial diagnosis. S/p RTx of the primary.

FDG-PET/CT requested for restaging shows intense FDG uptake in the oesophagus (primary, B1). Additional FDG avid LN in the supraclavicular region (B2).

8.2. CASE NO. GI OES 2

Study type:	Oncology	Clinical indication:	Laryngeal cancer
Clinical indication for PET/CT:	Restaging		
Keywords:	Oesophageal cancer Multiple metastases Osseous metastases		
PET/CT system:	Philips TF64	Tracer:	FDG
Uptake:	63 min	Dose:	222 MBq
Range:	WB	Blood glucose:	5.0 mmol/L
No. beds:	10	Min/bed:	1
Tube loading:	150 mAs	Tube voltage:	100 kVp

Short clinical history

A 50 year old male patient with laryngeal cancer diagnosed 6 years ago. S/p surgery and RTx. Currently, the patient is presenting with enlarged right supraclavicular LNs. Fine needle aspiration cytology showed metastasis from adenocarcinoma. However, oropharyngeal/laryngeal examination is not suspicious for local recurrence. An FDG–PET/CT was requested for restaging purposes.

PET/CT findings

FDG–PET/CT shows intense FDG uptake and thickened proximal and middle third of the oesophagus. There are multiple FDG avid supraclavicular LNs, as well as multiple FDG avid pulmonary nodules. Several FDG avid hepatic lesions. Disseminated FDG avid osseous metastatic lesions can be seen throughout the spine and pelvis.

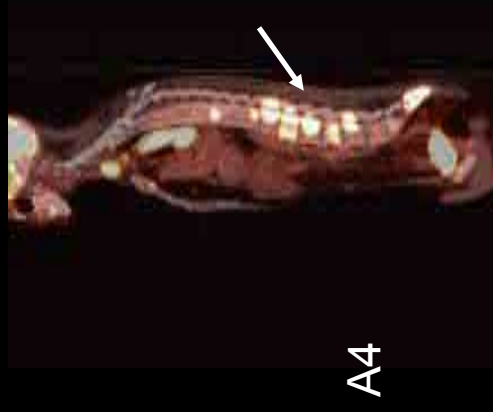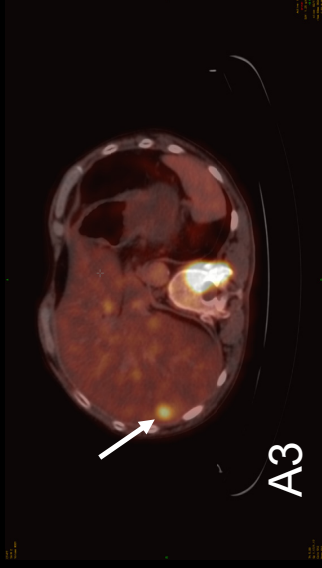
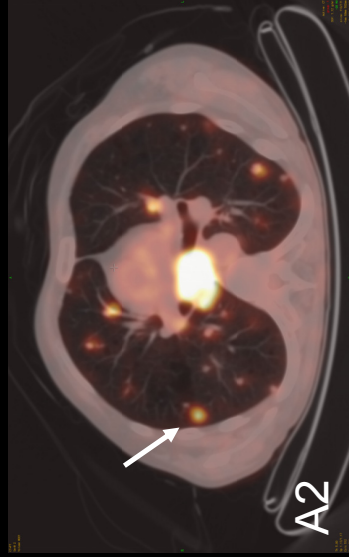
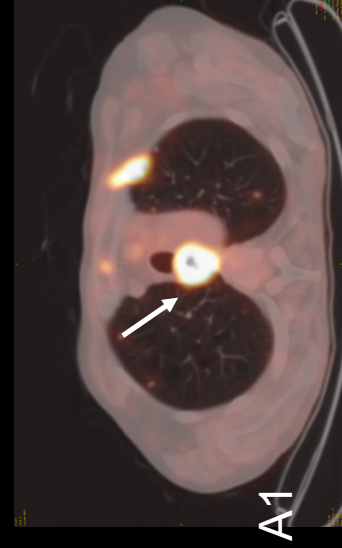
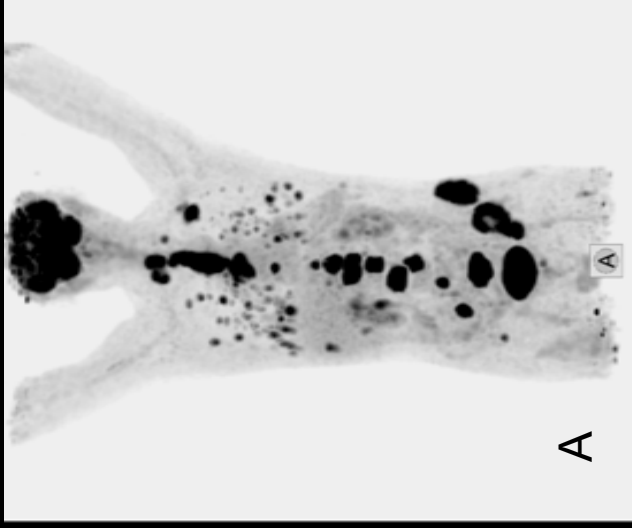
Impression: Oesophageal cancer (second primary tumour) with mediastinal and supraclavicular metastases. Multiple pulmonary and osseous metastases.

Follow-up

Treatment: ChTx with palliative intent.

Consequences of the current PET/CT examination reported here

Upstage of disease and change in treatment plan.



Oesophageal cancer

50 y/o M patient s/p laryngeal cancer diagnosed 6 years ago. Now rising tumour markers, positive fine needle aspiration cytology from a right supraclavicular LN.

FDG-PET/CT requested for restaging (A) shows wall thickening and high FDG uptake in the proximal and middle third part of the oesophagus (A1). FDG avid and enlarged supraclavicular LNs (A), multiple FDG avid pulmonary (A2), hepatic (A3) and osseous (A4) lesions.

8.3. CASE NO. GI OES 3

Study type:	Oncology	Clinical indication:	Oesophageal cancer
Clinical indication for PET/CT:	Restaging		
Keywords:	Oesophageal cancer Multiple metastases Osseous metastases		
PET/CT system:	Philips TF64	Tracer:	FDG
Uptake:	52 min	Dose:	530 MBq
Range:	WB	Blood glucose:	5.9 mmol/L
No. beds:	10	Min/bed:	2.5
Tube loading:	150 mAs	Tube voltage:	120 kVp

Short clinical history

A 69 year old male patient diagnosed with oesophageal cancer in the lower third of the oesophagus and with mediastinal metastasis. An FDG–PET/CT was requested for staging and restaging purposes.

PET/CT findings

- (A) FDG–PET/CT for staging shows an FDG avid thickened distal oesophagus. No evidence of FDG avid mediastinal metastasis. The patient was treated with surgical resection and mediastinal dissection followed by ChTx.
- (B) FDG–PET/CT scan was performed for restaging purposes 11 months later, showing recurrent, widely disseminated disease in the mediastinum and retroperitoneum.

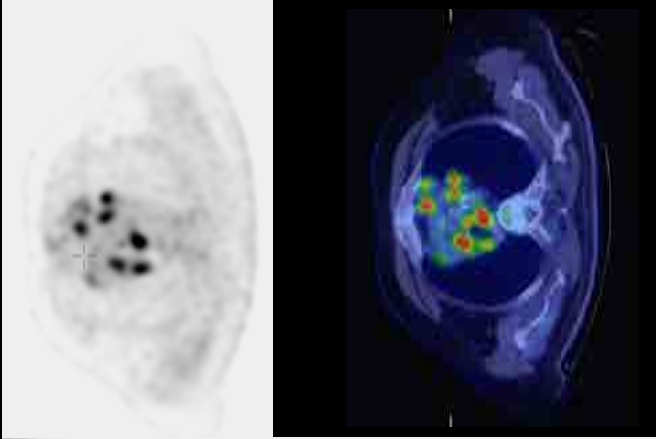
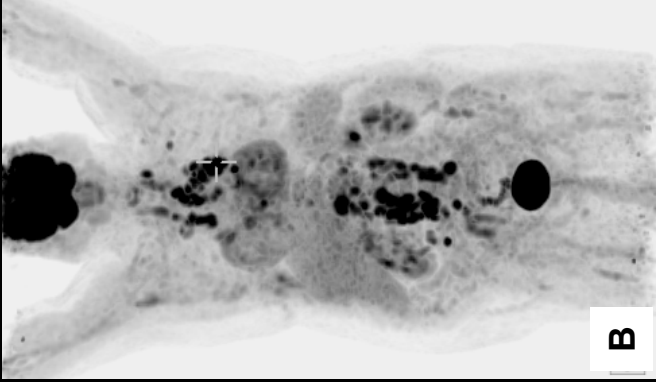
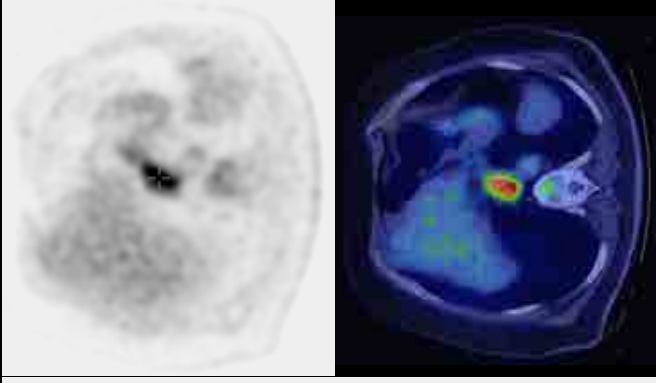
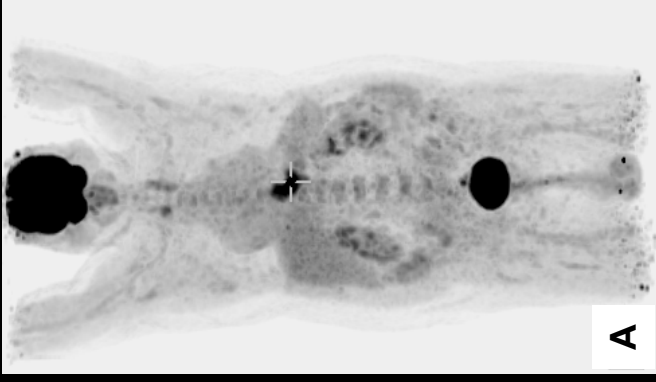
Final impression: Disseminated tumour recurrence.

Follow-up

Treatment: ChTx with palliative intent.

Consequences of the current PET/CT examination reported here

Change in treatment plan.



Oesophageal cancer

69 y/o M patient with oesophageal cancer and suspected mediastinal LN metastasis.

- (A) FDG-PET/CT requested for initial staging shows focal FDG uptake in the distal third of the oesophagus. Treated with resection and mediastinal LN dissection followed by 6 cycles ELF ChTx.
- (B) FDG-PET/CT requested for restaging shows disseminated recurrent disease in the mediastinum and retroperitoneum.

8.4. CASE NO. GI OES 4

Study type:	Oncology	Clinical indication:	Oesophageal cancer
Clinical indication for PET/CT:	Initial staging		
Keywords:	Oesophageal cancer Liver metastases		
PET/CT system:	Philips TF64	Tracer:	FDG
Uptake:	56 min	Dose:	204 MBq
Range:	WB	Blood glucose:	5.6 mmol/L
No. beds:	9	Min/bed:	1
Tube loading:	100 mAs	Tube voltage:	120 kVp

Short clinical history

A 68 year old male patient with a history of dysphagia. Oesophageal cancer was detected following endoscopy. Abdominal CECT was performed for staging purposes, which demonstrated a contrast enhancing lesion of 18 mm in the right liver lobe suspicious for distant metastatic involvement.

PET/CT findings

FDG–PET/CT requested for staging purposes detected an FDG avid lesion in the middle third of the oesophagus consistent with the known tumour in this organ. However, the hypodense lesion in segment VIII of the liver failed to show increased FDG uptake.

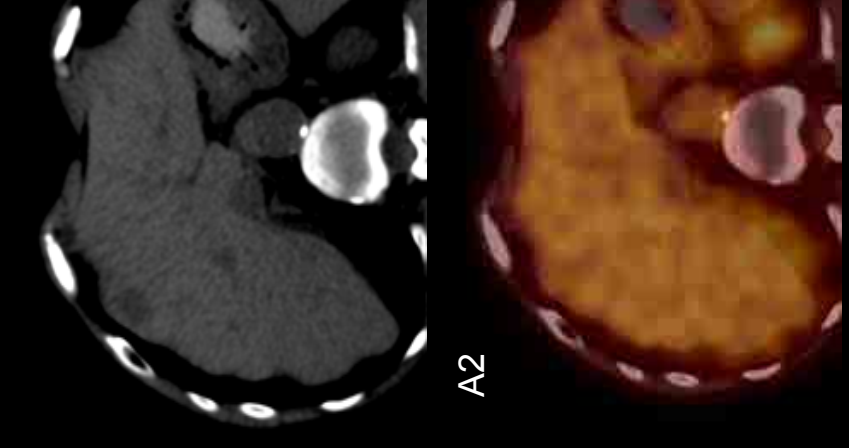
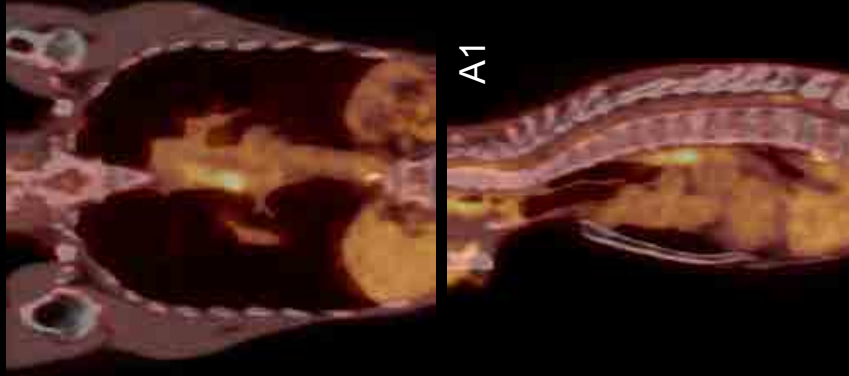
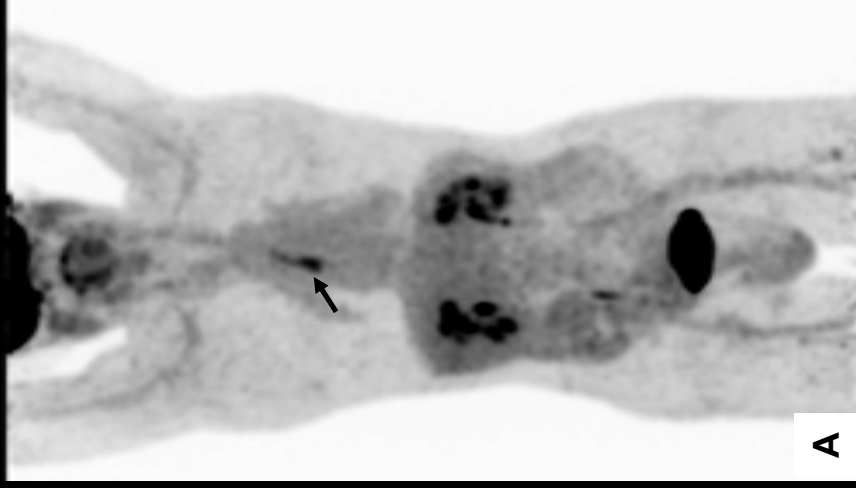
Impression: Primary oesophageal cancer with no distant hepatic metastasis.

Follow-up

Treatment: Surgery followed by RTx with curative intent.

Consequences of the current PET/CT examination reported here

Downstage of disease and change in treatment plan.



Oesophageal cancer

68 y/o M patient diagnosed with oesophageal cancer. A CECT found contrast enhancing lesion in the liver; metastasis could not be excluded.

FDG-PET/CT requested for staging (A) confirmed cancer in the middle third of the oesophageous (A1). A hypodense lesion in the liver does not show FDG uptake (A2).

9. GASTROINTESTINAL TRACT: LIVER

9.1. CASE NO. GI LIV 1

Study type:	Oncology	Clinical indication:	HCC
Clinical indication for PET/CT:	Initial staging		
Keywords:	HCC		
PET/CT system:	Siemens Biograph Duo	Tracer:	FDG
Uptake:	61 min	Dose:	310 MBq
Range:	WB	Blood glucose:	4.6 mmol/L
No. beds:	7	Min/bed:	3
Tube loading:	120 mAs	Tube voltage:	80 kVp

Short clinical history

A 58 year old female patient with a cirrhotic liver suspected of having HCC. A dedicated CT scan of the abdomen was negative.

PET/CT findings

Initial FDG–PET/CT (A) detected HCC, confirmed by DSA and biopsy. The patient was treated with radiofrequency ablation.

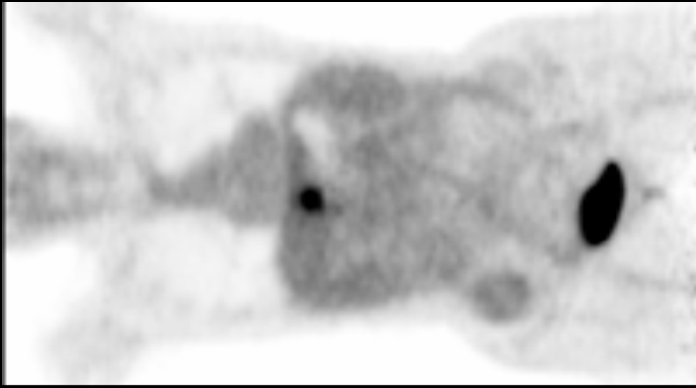
Follow-up FDG–PET/CT (B) performed 6 months later shows no evidence of disease.

Follow-up

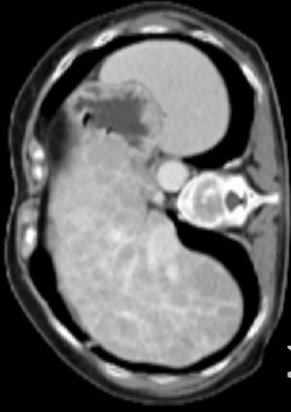Treatment: Radiofrequency ablation with curative intent.

Consequences of the current PET/CT examination reported here

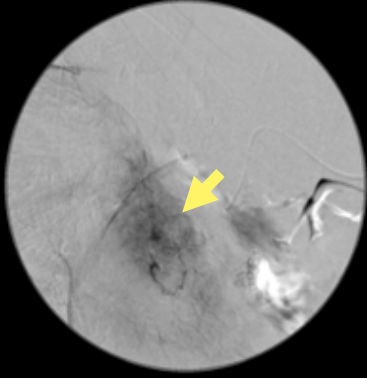
Change in treatment plan.



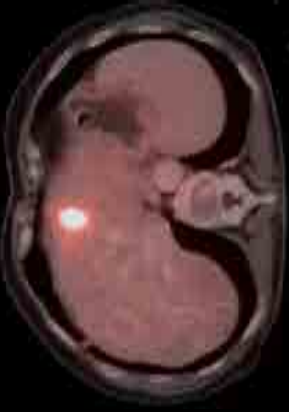A



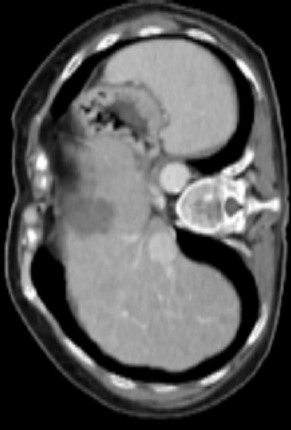A1



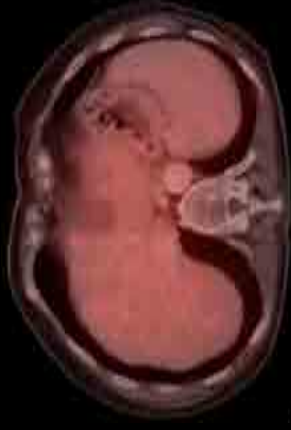DSA



A2



B1



B2

Hepatocellular carcinoma

58 y/o F patient with suspected HCC in cirrhotic liver. Dedicated CT was negative.

Initial FDG-PET/CT (A) detected HCC, confirmed by DSA. Radiofrequency ablation of HCC was performed.

Follow-up FDG-PET/CT (B) requested 6 months later shows no evidence of disease.

9.2. CASE NO. GI LIV 2

Study type:	Oncology	Clinical indication:	HCC
Clinical indication for PET/CT:	Initial staging, restaging		
Keywords:	HCC Therapy response		
PET/CT system:	Siemens Biograph Duo	Tracer:	FDG
Uptake:	61 min	Dose:	341 MBq
Range:	WB	Blood glucose:	5.2 mmol/L
No. beds:	7	Min/bed:	3
Tube loading:	120 mAs	Tube voltage:	80 kVp

Short clinical history

A 67 year old male patient with known HCC. No curative surgical resection is possible. An FDG–PET/CT scan was requested before and following radiofrequency ablation.

PET/CT findings

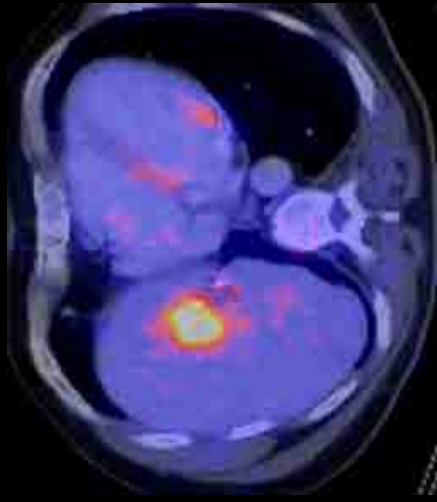
- (A) Initial FDG–PET/CT scan shows viable FDG avid HCC. Radiofrequency ablation of HCC was performed.
- (B) Follow-up FDG–PET/CT performed 4 weeks after ablation shows no evidence of viable tumour.
- (C) Follow-up FDG–PET/CT 3 month after ablation shows a small area of FDG avid tumour recurrence.

Follow-up

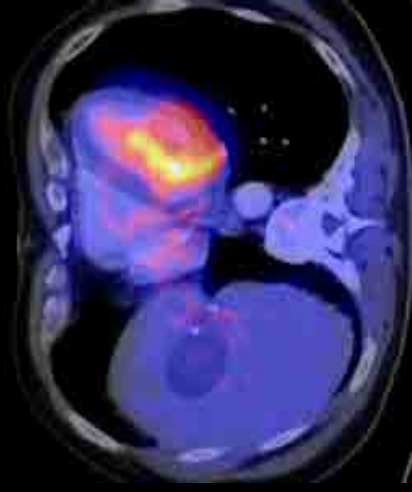
Treatment: Radiofrequency ablation with curative intent. ChTx.

Consequences of the current PET/CT examination reported here

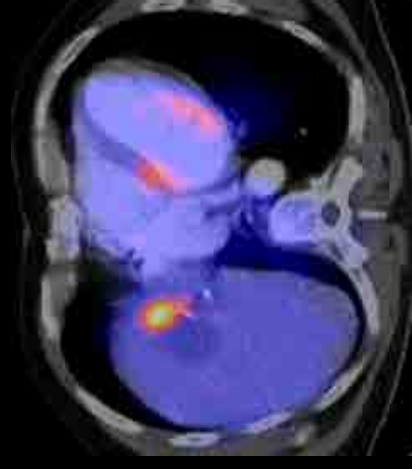
Change in treatment plan.



(A)



(B)



(C)

Hepatocellular carcinoma

67 y/o M patient with HCC. No curative surgical treatment possible. FDG-PET/CT before and after radiofrequency ablation.

(A) Initial FDG-PET/CT shows viable HCC.

(B) Follow-up 4 weeks after ablation shows no viable tumour.

(C) Follow-up 3 months after ablation shows tumour recurrence.

9.3. CASE NO. GI LIV 3

Study type:	Oncology	Clinical indication:	Liver tumour
Clinical indication for PET/CT:	Initial staging		
Keywords:	Unclear liver tumour		
PET/CT system:	GE Discovery VCT	Tracer:	FDG
Uptake:	70 min	Dose:	312 MBq
Range:	WB	Blood glucose:	4.6 mmol/L
No. beds:	7	Min/bed:	2
Tube loading:	120 mAs	Tube voltage:	80 kVp

Short clinical history

A 59 year old female patient hospitalized due to perforated diverticulitis 10 days ago. At primary imaging (contrast enhanced CT), a large liver tumour of the right hepatic lobe was discovered. Additional clinical history revealed that the patient was already symptomatic prior to the diverticulitis.

PET/CT findings

FDG–PET/CT scan shows a large, 16 cm, centrally necrotic lesion with high glucose metabolism at the rim. No other tumours or lesions are detected. Note also the faint uptake of the prior diverticulitis at the right colonic flexure.

Based on the FDG–PET/CT scan, a CCC or HCC was suspected. Histopathology after hemihepatectomy revealed a poorly differentiated, highly malignant and highly proliferating tumour. No other differentiation could be made.

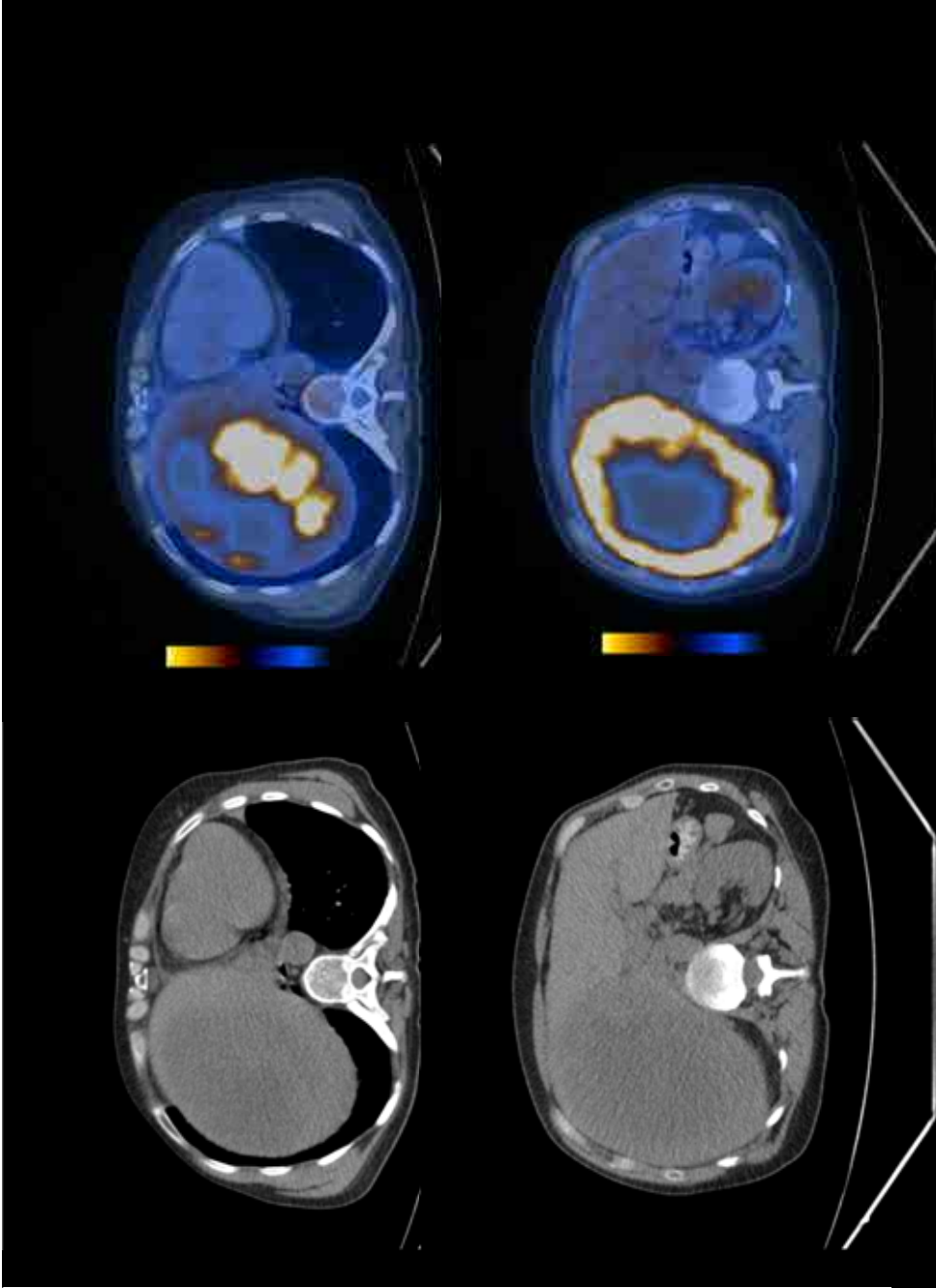
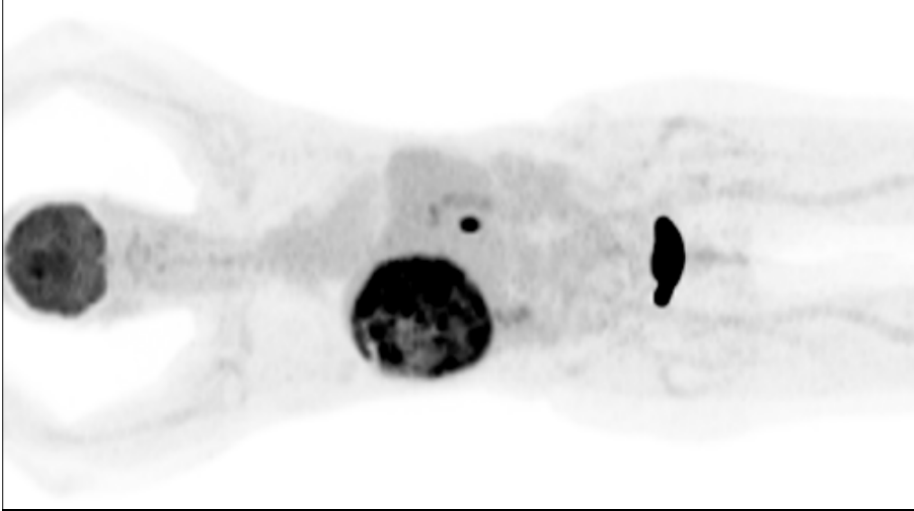
Follow-up

Additional imaging.

Treatment: Surgery with curative intent.

Consequences of the current PET/CT examination reported here

No change in treatment plan.



Unclear liver tumour

59 y/o F patient hospitalized with covered perforated diverticulitis at the right colonic flexure 10 days ago. Imaging showed a symptomatic, large liver tumour of the right hepatic lobe. FDG-PET/CT scan shows a large, 16 cm, centrally necrotic lesion with high glucose metabolism at the rim. No other tumours/lesions detected. Based on FDG-PET/CT, a CCC or HCC was suspected.

10. GASTROINTESTINAL TRACT: PANCREAS

10.1. CASE NO. GI PANC 1

Study type:	Oncology	Clinical indication:	Pancreatic cancer
Clinical indication for PET/CT:	Restaging		
Keywords:	Pancreatic cancer Secondary tumour Pitfall		
PET/CT system:	GE Discovery 690 TOF	Tracer:	FDG
Uptake:	68 min	Dose:	377 MBq
Range:	WB	Blood glucose:	5.6 mmol/L
No. beds:	7	Min/bed:	2
Tube loading:	120 mAs	Tube voltage:	80 kVp

Short clinical history

A 49 year old male patient who had radical cystectomy several years ago. Patient received adjuvant ChTx and an ileal conduit. Currently, there is suspicion of pancreatic cancer (from outside follow-up/restaging CT).

PET/CT findings

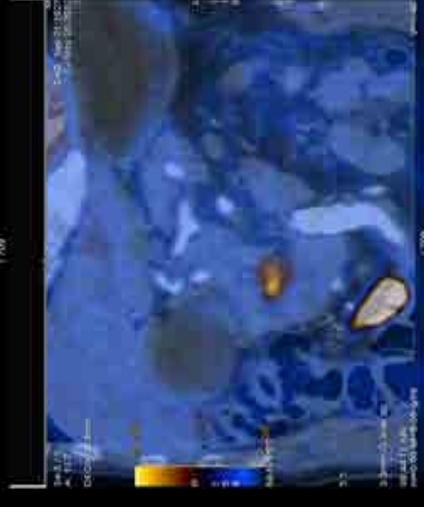
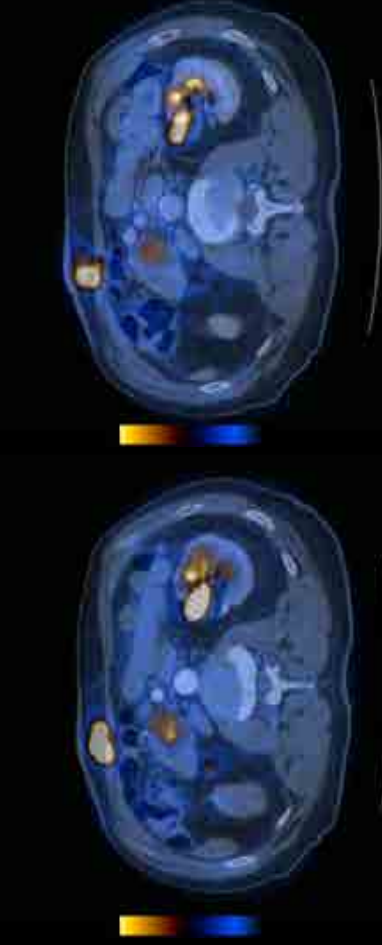
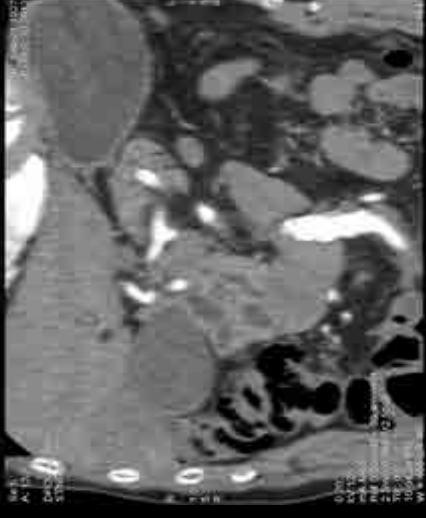
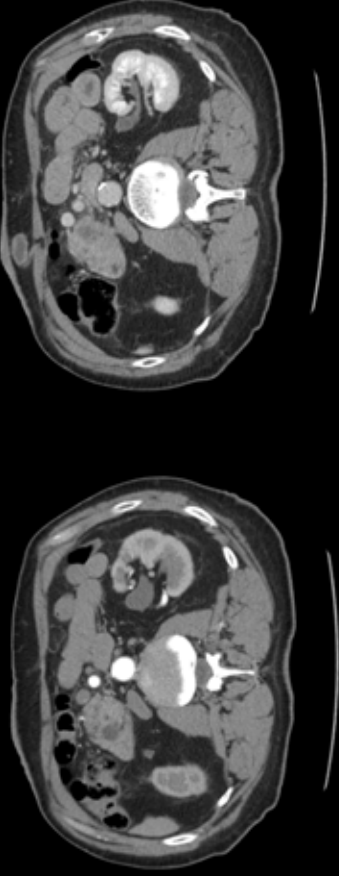
FDG–PET/CT scan with arterial and portal venous contrast media phase shows a hypodense lesion within the pancreatic head with focal glucose metabolism. Slight widening of the pancreatic duct. There is direct contact to the 2nd part of the duodenum. The fat plane cannot be differentiated, which is suspicious for infiltration. No locoregional LNs or distant metastases are to be found. Note also the ileal conduit subcutaneously in the anterior abdomen post-radical cystectomy.

Follow-up

Treatment: Surgery with curative intent.

Consequences of the current PET/CT examination reported here

Upstage of disease and change in treatment plan.



Pancreatic cancer

49 y/o M patient with previously operated bladder cancer; now suspicion for pancreatic cancer. FDG-PET/CT requested for staging.

PET/CT performed with CT contrast media shows a hypodense lesion within the pancreatic head with focal glucose metabolism. Note conduit subcutaneous in the anterior abdomen post-radical cystectomy (potential pitfall).

10.2. CASE NO. GI PANC 2

Study type:	Oncology	Clinical indication:	Pancreatic cancer
Clinical indication for PET/CT:	Initial staging		
Keywords:	Pancreatic cancer Pitfall		
PET/CT system:	GE Discovery 690 TOF	Tracer:	FDG
Uptake:	68 min	Dose:	301 MBq
Range:	WB	Blood glucose:	6.0 mmol/L
No. beds:	7	Min/bed:	2
Tube loading:	120 mAs	Tube voltage:	80 kVp

Short clinical history

A 73 year old female patient who complained about a slight increase in digestive problems. An MRI scan was requested which demonstrated a cystic pancreatic neoplasm. An FDG–PET/CT scan was requested for staging purposes.

PET/CT findings

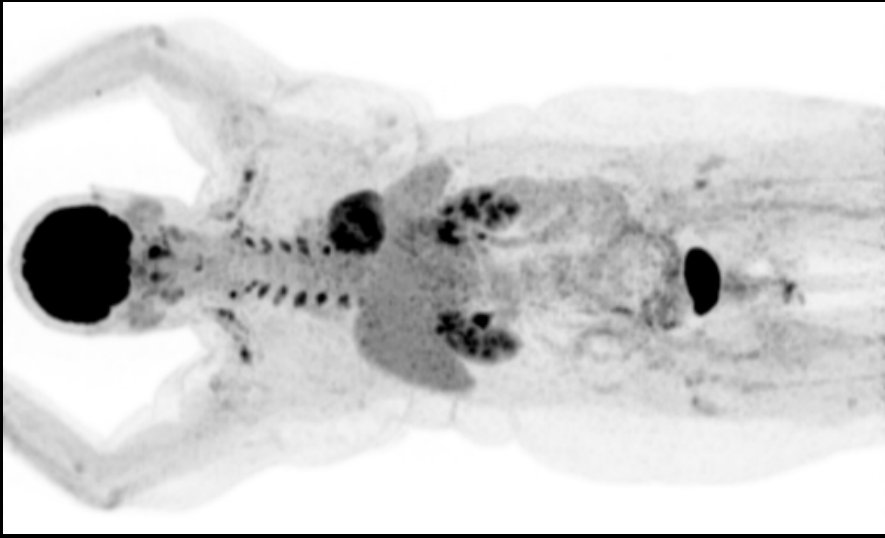
FDG–PET/CT scan with arterial and portal venous contrast media shows a large cystic mass within the pancreatic head with septa and calcifications. However, no elevated focal or diffuse glucose metabolism can be seen. The portal vein confluence is slightly dilated. No locoregional LNs or distant metastases can be seen. Imaging findings are in keeping with a mucinous cystic and infiltrative pancreatic neoplasm. Note the brown fat uptake in the supraclavicular and paraspinal regions.

Follow-up

Observation.

Consequences of the current PET/CT examination reported here

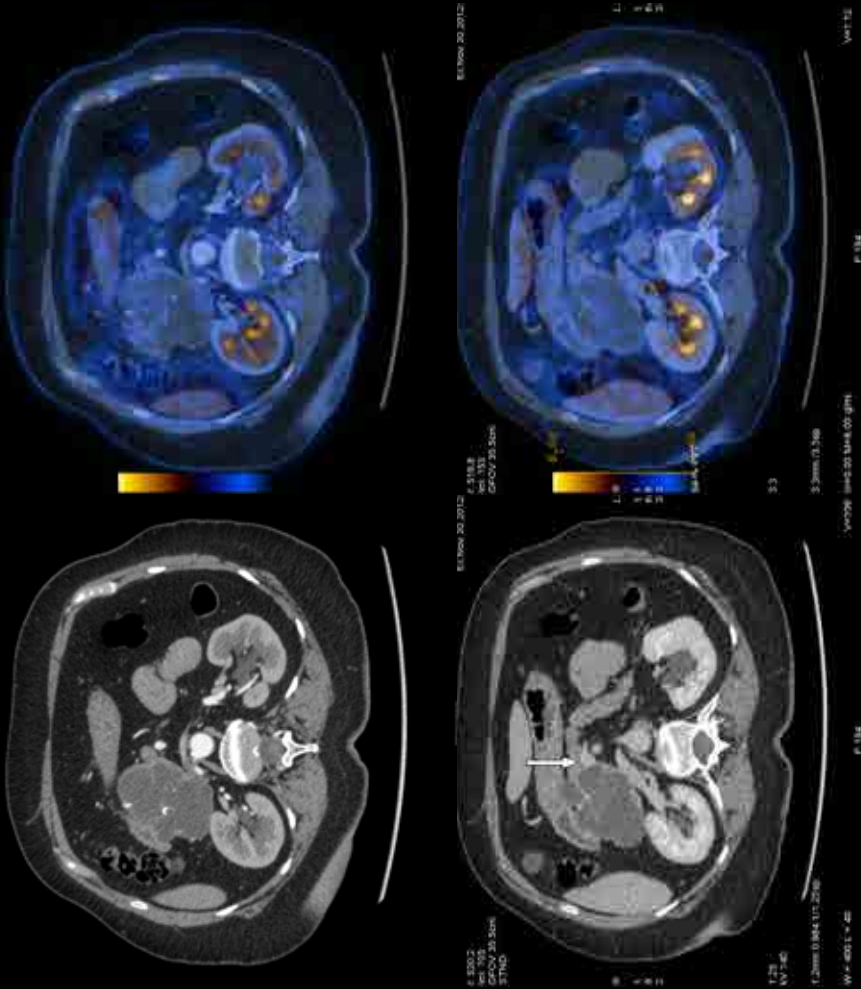
No change in treatment plan.



Pancreatic cancer

73 y/o F patient with suspicion of a cystic pancreatic neoplasm. FDG-PET/CT requested for staging.

PET/CT scan shows large cystic mass within the pancreatic head with calcifications and septa. No elevated glucose metabolism (FDG negative). The portal vein confluence is slightly dilated (arrow). Note the brown fat uptake in the supraclavicular and paraspinal regions.



10.3. CASE NO. GI PANC 3

Study type:	Oncology	Clinical indication:	Pancreatic cancer
Clinical indication for PET/CT:	Initial staging		
Keywords:	Pancreatic cancer Hepatic metastasis		
PET/CT system:	Philips TF64	Tracer:	FDG
Uptake:	61 min	Dose:	314 MBq
Range:	WB	Blood glucose:	4.8 mmol/L
No. beds:	9	Min/bed:	1
Tube loading:	50 mAs	Tube voltage:	120 kVp

Short clinical history

A 62 year old female patient with no major prior disease. She complained of right-sided abdominal pain radiating to her back. In addition, the CA 19-9 tumour marker level is elevated.

PET/CT findings

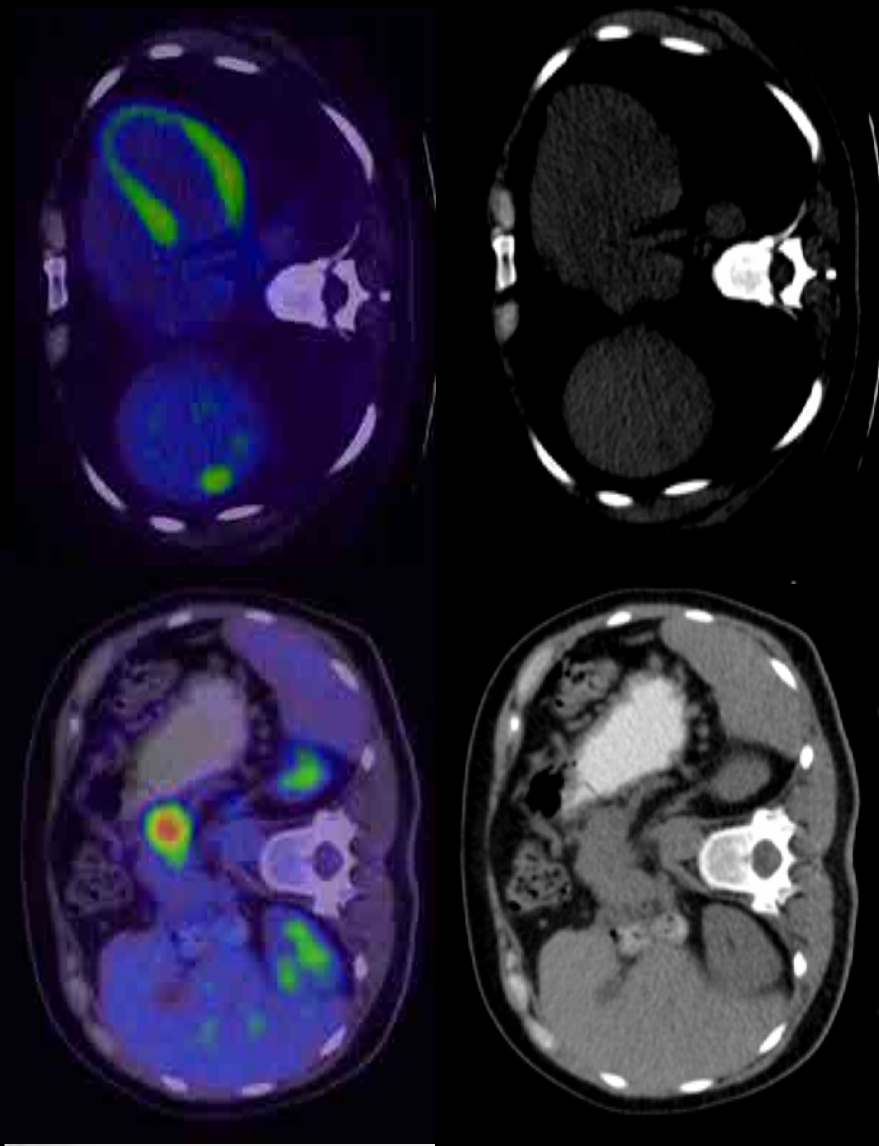
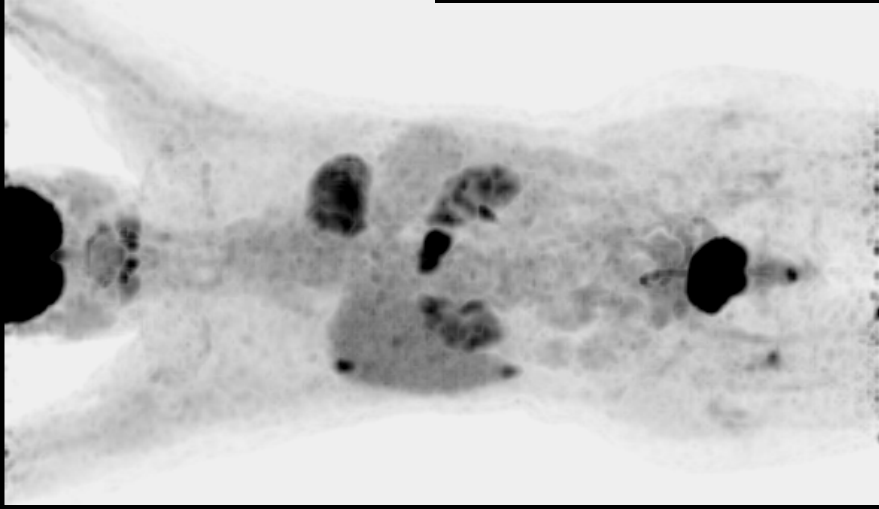
Intense focal uptake at the pancreatic body corresponding to a malignant carcinoma. There are focal FDG avid lesions in the liver representing metastases.

Follow-up

Treatment: ChTx and surgery with palliative intent.

Consequences of the current PET/CT examination reported here

Upstage of disease and change in treatment plan.



Pancreatic cancer

62 y/o F patient with abdominal pain of the right side, elevated cancer 19-9 level.

FDG-PET/CT requested for staging shows intense focal uptake in the pancreas body with three focal FDG avid lesions in the liver corresponding to metastases.

11. GASTROINTESTINAL TRACT: COLON

11.1. CASE NO. GI CO 1

Study type:	Oncology	Clinical indication:	Colon cancer
Clinical indication for PET/CT:	Restaging and suspected recurrence		
Keywords:	Colon cancer Lung metastases Osseous metastases LN metastases		
PET/CT system:	GE Discovery 690 TOF	Tracer:	FDG
Uptake:	87 min	Dose:	312 MBq
Range:	WB	Blood glucose:	5.3 mmol/L
No. beds:	7	Min/bed:	2
Tube loading:	120 mAs	Tube voltage:	80 kVp

Short clinical history

A 66 year old female patient with rectal cancer resected two years ago. The patient was treated with neo-adjuvant ChTxRT. Currently, there is suspicion of tumour recurrence at the left iliac vein with vessel infiltration. An FDG–PET/CT scan was requested for restaging purposes.

PET/CT findings

The FDG–PET/CT scan demonstrates the suspected tumour recurrence at the left iliac vein. In addition, there are several FDG avid lesions in the lung as well as in the left sacral bone. Interestingly, the bone lesion is not visible on the CT image.

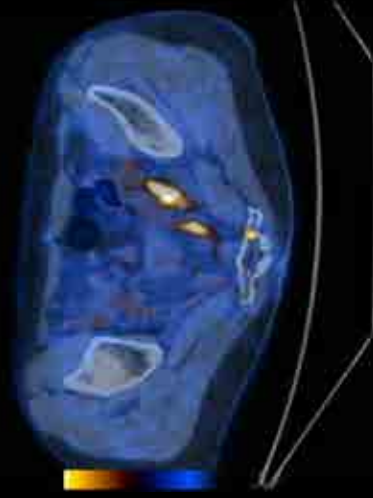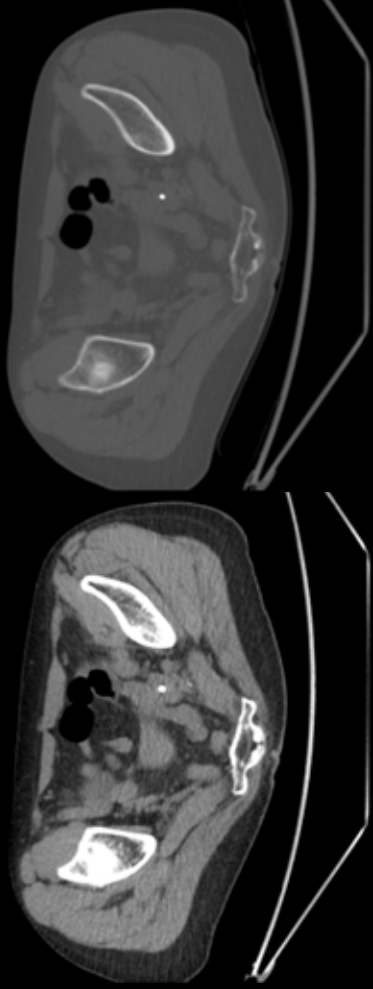
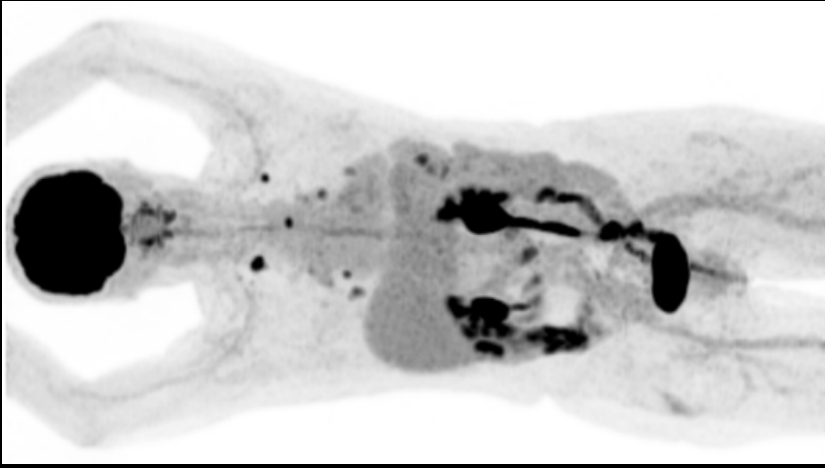
Impression: Metastatic recurrence at the left iliac vein, with several pulmonary metastases and a single osseous metastasis in the left sacrum.

Follow-up

Treatment: ChTxRT with palliative intent.

Consequences of the current PET/CT examination reported here

Upstage of disease and change in treatment plan.



Rectal cancer

66 y/o F patient with rectal cancer s/p resection.

FDG-PET/CT requested for restaging shows the already suspected recurrence at the left iliac vein. In addition, several lung metastases as well as one small osseous metastases in the left sacral bone is detected.

11.2. CASE NO. GI CO 2

Study type:	Oncology	Clinical indication:	Colon cancer
Clinical indication for PET/CT:	Restaging and suspected recurrence		
Keywords:	Colon cancer Brain metastases Liver metastases Lung metastases		
PET/CT system:	GE Discovery VCT	Tracer:	FDG
Uptake:	87 min	Dose:	349 MBq
Range:	WB	Blood glucose:	7.5 mmol/L
No. beds:	8	Min/bed:	2
Tube loading:	140 mAs	Tube voltage:	80 kVp

Short clinical history

A 68 year old female patient referred for initial staging of a cancer of the rectosigmoid junction. On the CT image, there are suspected liver metastases. The patient was referred for an FDG–PET/CT scan for initial staging purposes.

PET/CT findings

FDG–PET/CT scan for initial staging confirms the presence of the already known circular rectosigmoid cancer with high FDG uptake. In addition, an FDG avid liver lesion, left lower lung lesion and an FDG avid brain lesion are detected. Furthermore, suspicious focal FDG uptake is detected at the ascending colon. Note the FDG injection site in the right arm.

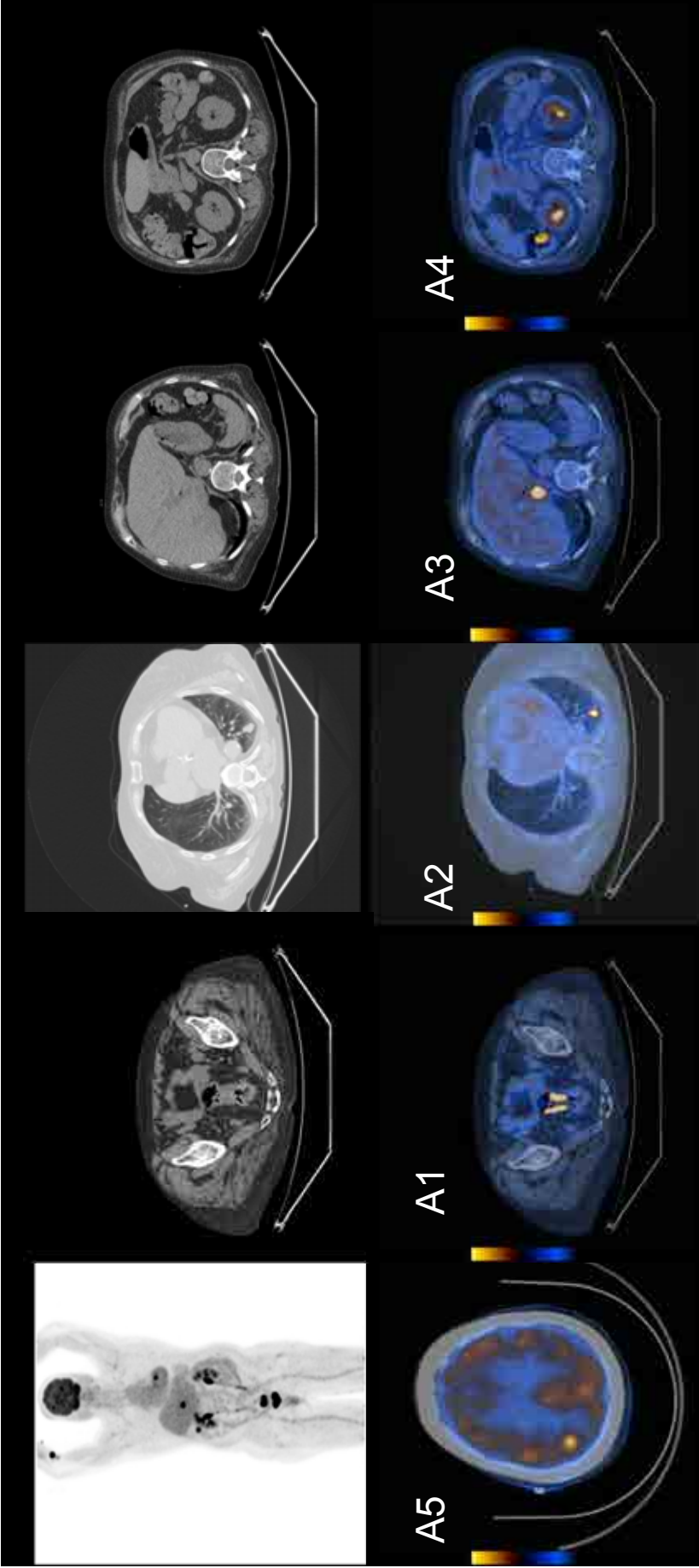
Impression: Rectosigmoid cancer, with liver, lung and brain metastasis. Possible second primary cancer at proximal ascending colon.

Follow-up

Additional imaging and treatment: Surgery (neck dissection) and ChxRT with palliative intent.

Consequences of the current PET/CT examination reported here

Upstage of disease and change in treatment plan.



Colon cancer

68 y/o F patient with rectosigmoid cancer.

FDG-PET/CT requested for initial staging shows a circular rectosigmoid cancer with high FDG uptake (A1), a left lower lung metastasis (A2), a liver metastasis (A3) and a brain metastasis (A5).

Suspicious focal FDG uptake is detected at the caecum — indicating a possible secondary colon cancer (A4).

Note: FDG injection site in right arm.

11.3. CASE NO. GI CO 3

Study type:	Oncology	Clinical indication:	Colon cancer
Clinical indication for PET/CT:	Restaging and treatment monitoring		
Keywords:	Colon cancer Therapy response		
PET/CT system:	Philips TF64	Tracer:	FDG
Uptake:	58 min	Dose:	386 MBq
Range:	WB	Blood glucose:	5.8 mmol/L
No. beds:	9	Min/bed:	1
Tube loading:	120 mAs	Tube voltage:	100 kVp

Short clinical history

A 50 year old female patient diagnosed with rectal cancer 1 year ago which was treated surgically. Currently, she is presenting with rising tumour marker levels and pain in the sacral region. An FDG–PET/CT scan was requested for restaging purposes.

PET/CT findings

- (A) FDG–PET/CT scan for restaging shows intense FDG uptake corresponding to soft tissue lesions along the right pelvic wall. She was managed with ChTxRT and surgical resection.
- (B) FDG–PET/CT scan after therapy, requested for restaging purposes shows decreased FDG uptake in the right pelvic wall lesions. However, there are new FDG avid lesions in the left side of the pelvis.

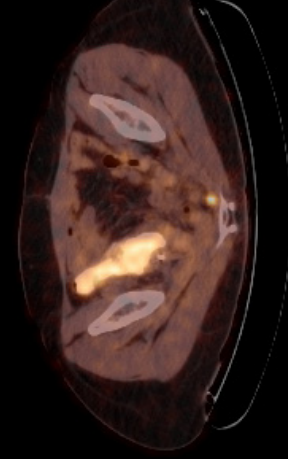
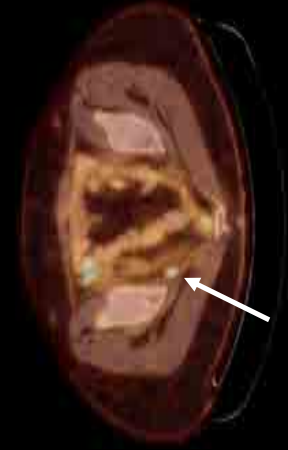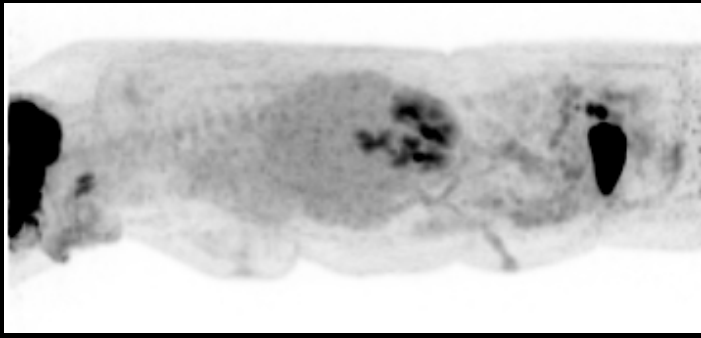
Impression: Local recurrence and progressive disease after therapy.

Follow-up

Tissue biopsy confirms cancer recurrence. Treatment: Surgery and ChTxRT with palliative intent.

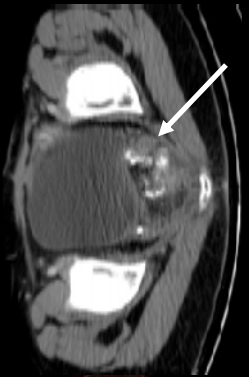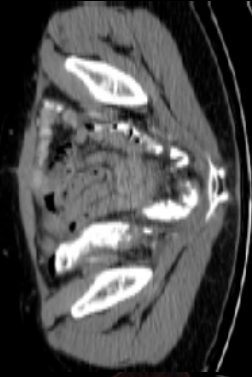
Consequences of the current PET/CT examination reported here

Upstage of disease and change in treatment plan.



A

B



Rectal cancer

50 y/o F patient with rectal cancer, s/p surgery.

(A) FDG-PET/CT requested for restaging shows tumour recurrence in the right pelvis.

(B) FDG-PET/CT requested for restaging shows progression.

11.4. CASE NO. GI CO 4

Study type:	Oncology	Clinical indication:	Colon cancer
Clinical indication for PET/CT:	Restaging		
Keywords:	Colon cancer Pitfall Residual mass Therapy response		
PET/CT system:	Philips TF64	Tracer:	FDG
Uptake:	60 min	Dose:	444 MBq
Range:	WB	Blood glucose:	5.3 mmol/L
No. beds:	8	Min/bed:	1.5
Tube loading:	150 mAs	Tube voltage:	120 kVp

Short clinical history

A 46 year old male patient diagnosed with rectal cancer 2 years ago, s/p surgery and ChTxRT. Currently, rising CEA and CA 19-9 levels. FDG-PET/CT was requested for restaging purposes.

PET/CT findings

- (A) FDG-PET/CT scan for restaging shows two presacral foci with intense FDG uptake. Treated with ChTx.
- (B) FDG-PET/CT scan for assessment of response to ChTx administered over 5 months, demonstrates increasing size and FDG activity in the presacral lesion.

Note: FDG uptake in the left lower abdomen corresponding to stoma.

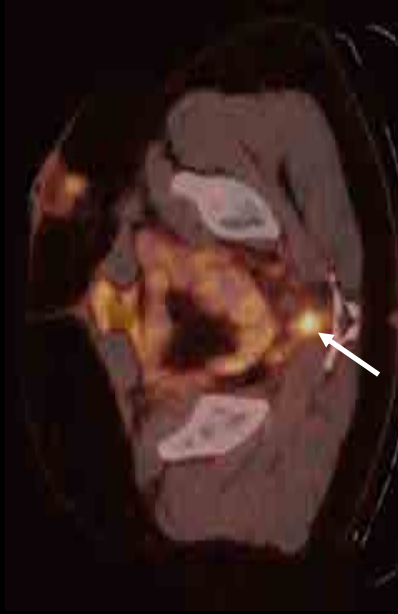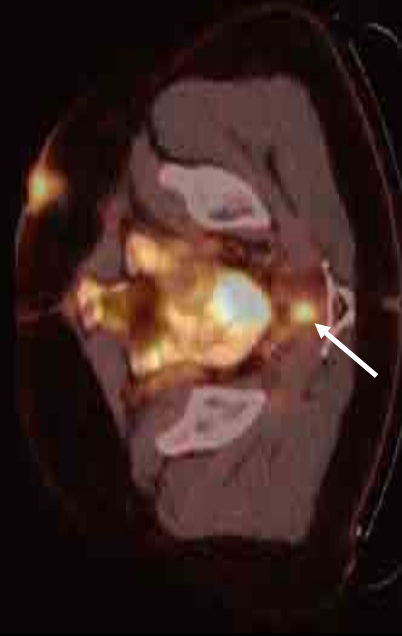
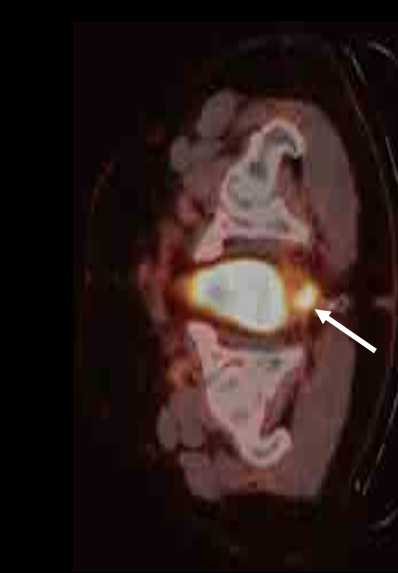
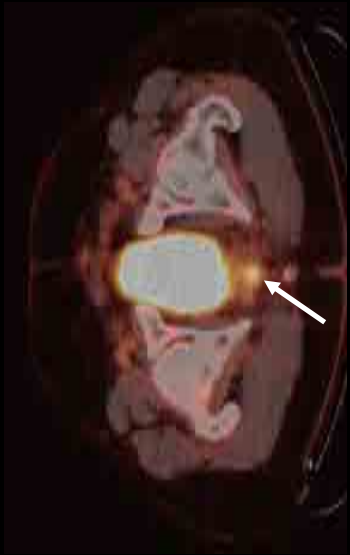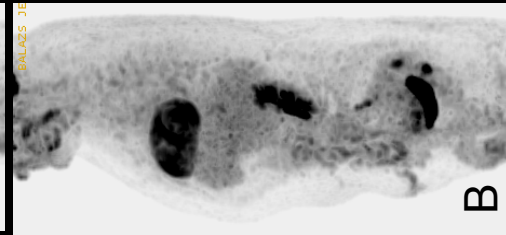
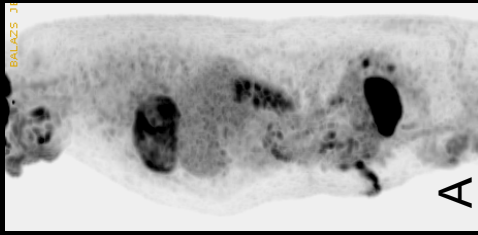
Impression: Locoregional recurrence and progressive disease after therapy.

Follow-up

Treatment: ChTxRT.

Consequences of the current PET/CT examination reported here

Upstage of disease and change in treatment plan.



Rectal cancer

46 y/o M patient with rectal cancer recurrence.

(A) FDG-PET/CT requested for restaging shows two presacral FDG avid foci. Treated with ChTx.

(B) Follow-up FDG-PET/CT (+5 mo) shows progression.

Note: FDG uptake in the left lower abdomen corresponding to stoma.

11.5. CASE NO. GI CO 5

Study type:	Oncology	Clinical indication:	Colon cancer
Clinical indication for PET/CT:	Restaging		
Keywords:	Colon cancer Secondary cancer Liver metastases		
PET/CT system:	Philips TF64	Tracer:	FDG
Uptake:	60 min	Dose:	308 MBq
Range:	WB	Blood glucose:	5.9 mmol/L
No. beds:	8	Min/bed:	1
Tube loading:	80 mAs	Tube voltage:	120 kVp

Short clinical history

A 67 year old male patient with history of rectal cancer diagnosed 1 year ago, treated surgically and with ChTx.

Histology: Adenocarcinoma, Grade I, Dukes C1, pT3 pN1 pMx. An FDG–PET/CT scan was requested for restaging purposes.

PET/CT findings

(A) FDG–PET/CT scan for restaging shows pathological focal uptake in the liver and an FDG avid mass in the upper lobe of the left lung with an ipsilateral mediastinal node showing increased FDG accumulation.

Impression: Second primary lung cancer with ipsilateral mediastinal nodal metastasis. Solitary hepatic metastasis. Surgical treatment confirmed SCC.

Treatment: Left upper lobe resection.

(B) Follow-up PET/CT scan revealed an increase in the size of the previously detected FDG avid lesion in the left hepatic lobe.

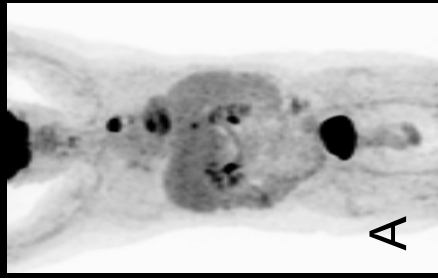
Impression: Progression of the hepatic metastasis.

Follow-up

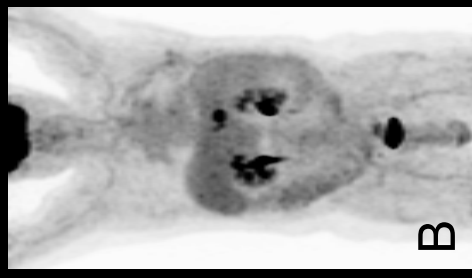
Tissue biopsy and treatment: Surgery with curative intent.

Consequences of the current PET/CT examination reported here

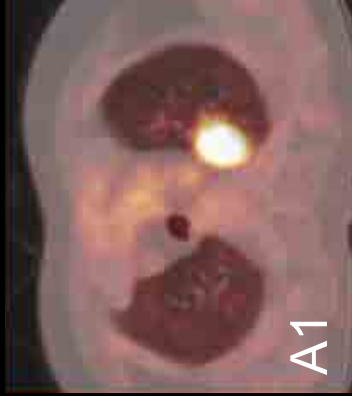Upstage of disease and change in treatment plan.



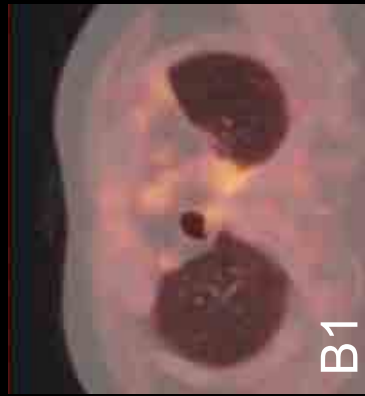A



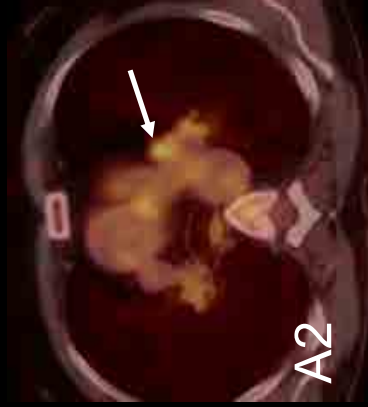B



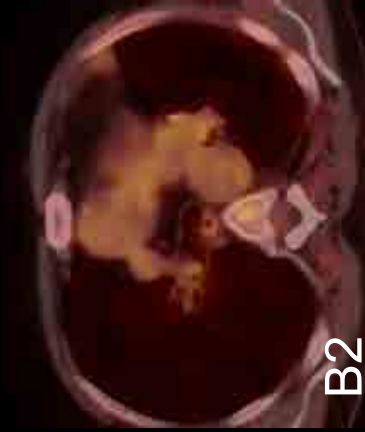A1



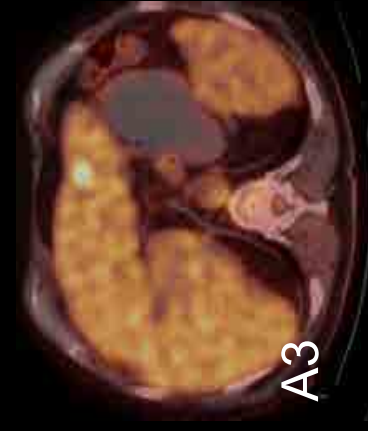B1



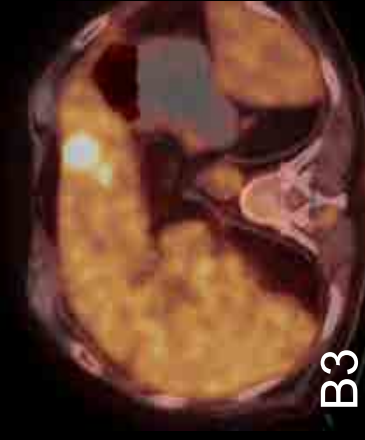A2



B2



A3



B3

Rectal cancer

67 y/o M patient with rectal cancer.

(A) FDG–PET/CT requested for restaging shows a secondary cancer in the left lung (A1) with an ipsilateral LN (A2) and a solitary focal FDG uptake in the liver (A3).

(B) FDG–PET/CT requested for follow-up shows s/p left upper lobe resection (B1) and lymphadenectomy (B2). The focal liver lesion shows progression.

11.6. CASE NO. GI CO 6

Study type:	Oncology	Clinical indication:	Colon cancer
Clinical indication for PET/CT:	Restaging		
Keywords:	Colon cancer Liver metastases		
PET/CT system:	Philips TF64	Tracer:	FDG
Uptake:	58 min	Dose:	336 MBq
Range:	WB	Blood glucose:	5.1 mmol/L
No. beds:	8	Min/bed:	1
Tube loading:	100 mAs	Tube voltage:	120 kVp

Short clinical history

A 44 year old female patient with rectal cancer diagnosed 1 year ago.

Histology: Adenocarcinoma. FDG–PET/CT scan was requested for restaging purposes.

PET/CT findings

An FDG–PET/CT scan shows several large irregular hypodense hepatic lesions which demonstrate ring-like intense FDG uptake. A small subpleural nodule is also visible on the left lower lobe, with discrete FDG uptake.

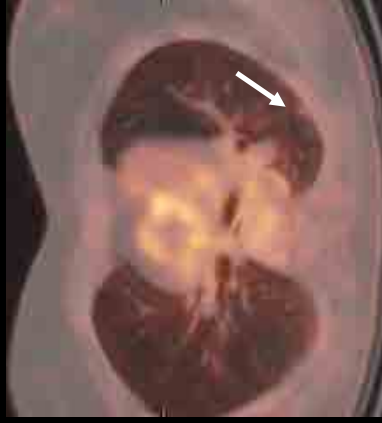
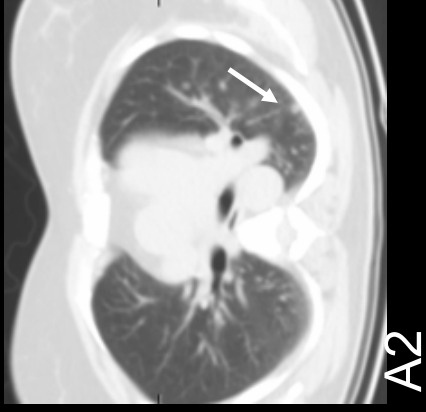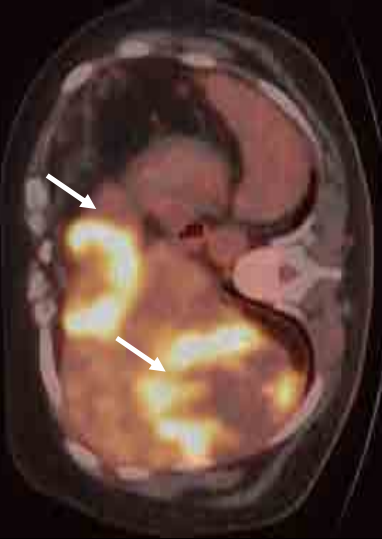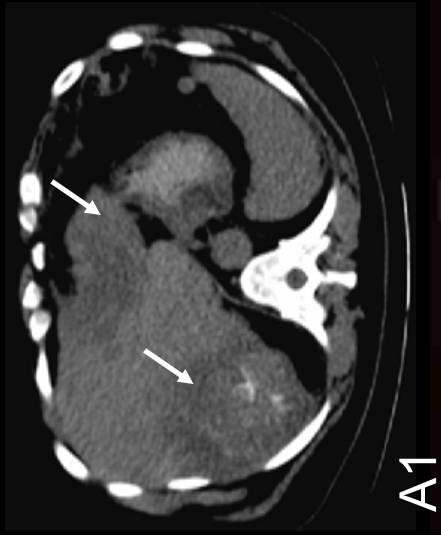
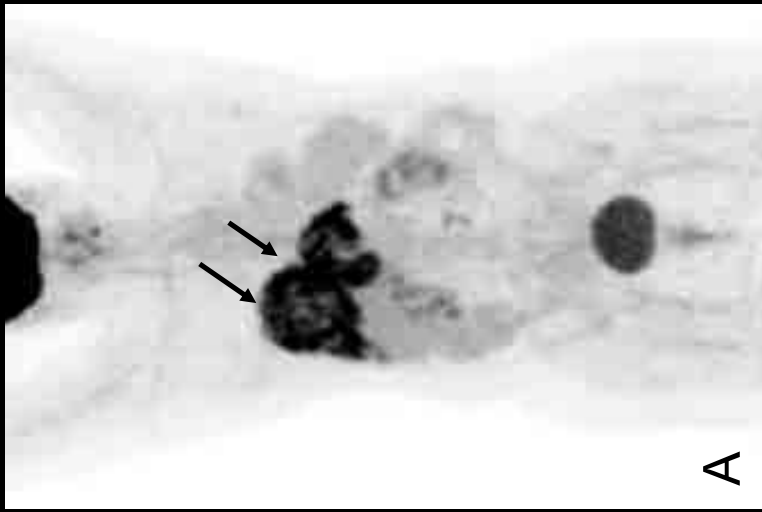
Impression: Multiple liver metastases with central necrosis and sclerotic areas indicative of metastasis from mucinous cancer. Suspected metastasis in the left lung. A CT scan is requested for follow-up.

Follow-up

Additional imaging and treatment: ChTx.

Consequences of the current PET/CT examination reported here

Change in treatment plan.



Rectal cancer

44 y/o F patient with rectal cancer, s/p surgery.

FDG-PET/CT requested for restaging (A) shows large irregular hypodense hepatic lesions with ring-like intense FDG uptake (A1).

A small subpleural nodule is also visible in the left lower lobe of the lung showing discrete FDG uptake (A2).

11.7. CASE NO. GI CO 7

Study type:	Oncology	Clinical indication:	Colon cancer
Clinical indication for PET/CT:	Monitoring treatment response		
Keywords:	Colon cancer Peritoneal metastases		
PET/CT system:	Philips TF64	Tracer:	FDG
Uptake:	56 min	Dose:	381 MBq
Range:	WB	Blood glucose:	4.1 mmol/L
No. beds:	7	Min/bed:	1
Tube loading:	100 mAs	Tube voltage:	120 kVp

Short clinical history

A 73 year old male patient diagnosed with colon cancer at the right hepatic flexure. Treated with hemicolectomy. FDG–PET/CT scan was requested for staging purposes.

PET/CT findings

(A) FDG–PET/CT scan for initial staging shows multiple foci of intense FDG uptake in the peritoneum.

Impression: Peritoneal metastases.

Treated with ChTx.

(B) FDG–PET/CT scan for assessment of response to therapy after 8 months demonstrates several new FDG avid peritoneal lesions.

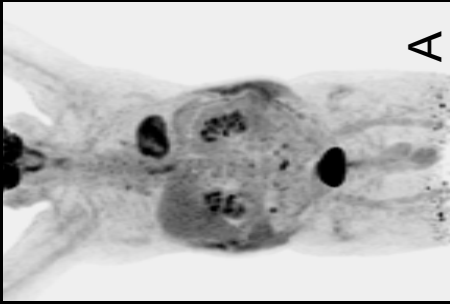
Impression: Progression of peritoneal carcinomatosis.

Follow-up

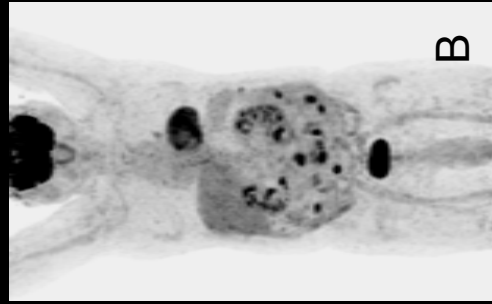
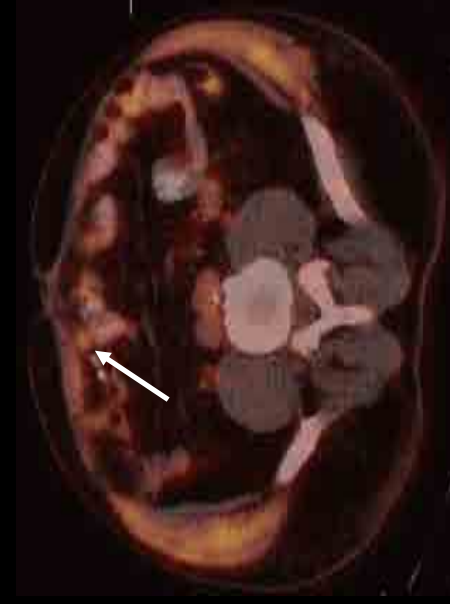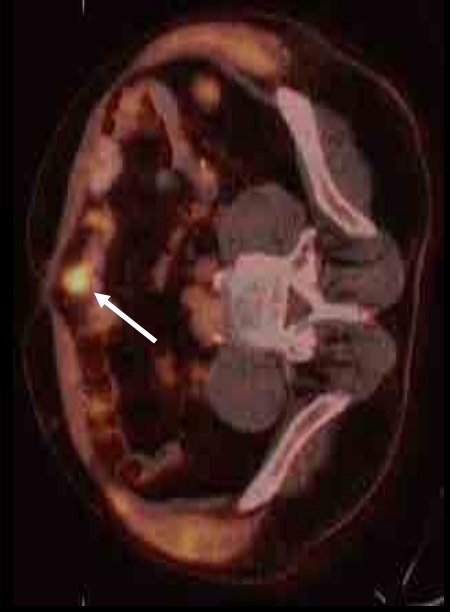Treatment: ChTx.

Consequences of the current PET/CT examination reported here

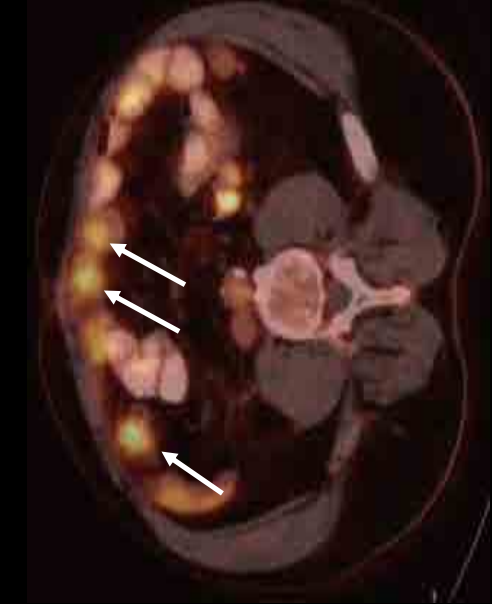
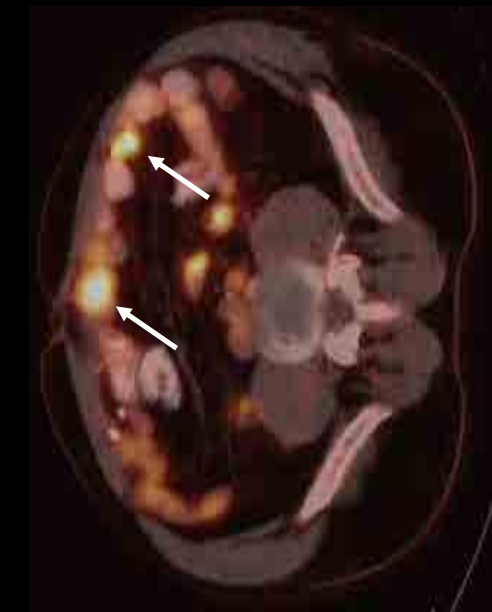
Change in treatment plan.



A



B



Colon cancer

73 y/o M patient with colon cancer at the hepatic flexure.

(A) FDG-PET/CT requested for initial staging shows multiple peritoneal metastases.

(B) FDG-PET/CT requested for follow-up shows peritoneal progression.

11.8. CASE NO. GI CO 8

Study type:	Oncology	Clinical indication:	Colon cancer
Clinical indication for PET/CT:	Monitoring treatment response		
Keywords:	Colon cancer Residual mass		
PET/CT system:	Philips TF64	Tracer:	FDG
Uptake:	69 min	Dose:	396 MBq
Range:	WB	Blood glucose:	8.3 mmol/L
No. beds:	10	Min/bed:	1.5
Tube loading:	150 mAs	Tube voltage:	120 kVp

Short clinical history

A 65 year old male patient with sigmoid cancer diagnosed 5 years ago treated with resection and ChTx. Currently, he has rising tumour markers. FDG–PET/CT scan was requested for restaging purposes.

PET/CT findings

(A) FDG–PET/CT scan shows a prevesical hypermetabolic lesion in connection with the anterior abdominal wall, corresponding to recurrence of disease.

Treated with surgical resection (histology: metastatic adenocarcinoma) and ChTx.

(B) FDG–PET/CT scan performed after treatment shows inhomogeneous FDG uptake in the post-operative prevesical region.

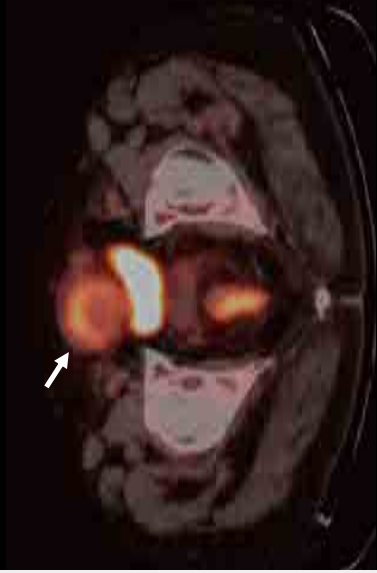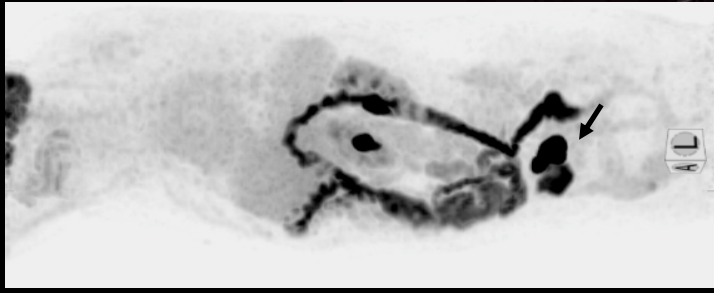
Impression: Post-operative status in the prevesical region, versus residual disease cannot be excluded.

Follow-up

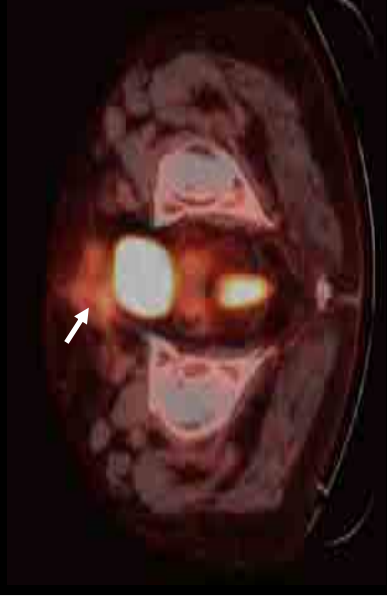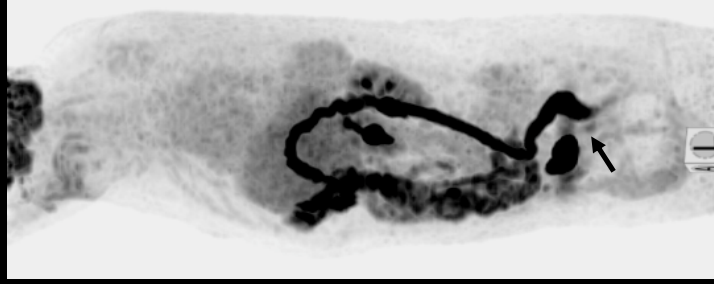
Observation.

Consequences of the current PET/CT examination reported here

No change in treatment plan.



A



B

Sigmoid cancer

65 y/o M patient with sigmoid cancer, s/p resection and ChTx.

(A) FDG-PET/CT requested for restaging shows prevesical hypermetabolic lesion in connection with the abdominal wall corresponding to recurrent disease.

(B) FDG-PET/CT requested for restaging shows inhomogeneous FDG uptake, diff. diagnosis: reactive uptake vs. residual disease.

11.9. CASE NO. GI CO 9

Study type:	Oncology	Clinical indication:	Colon cancer
Clinical indication for PET/CT:	Monitoring treatment response		
Keywords:	Colon cancer Splenic metastasis		
PET/CT system:	Philips TF64	Tracer:	FDG
Uptake:	60 min	Dose:	537 MBq
Range:	WB	Blood glucose:	7.0 mmol/L
No. beds:	11	Min/bed:	1.5
Tube loading:	80 mAs	Tube voltage:	120 kVp

Short clinical history

A 72 year old male patient with a history of colon cancer diagnosed 4 years ago, treated with a right hemicolectomy and ChTx. Currently, the patient is presenting with rising tumour marker. However, CECT and colonoscopy are negative. FDG–PET/CT scan was requested for restaging purposes.

PET/CT findings

FDG–PET/CT scan shows a focus of intense FDG uptake in the spleen corresponding to a hypodense lesion on the CT image. Intense linear FDG uptake in the descending colon can be seen.

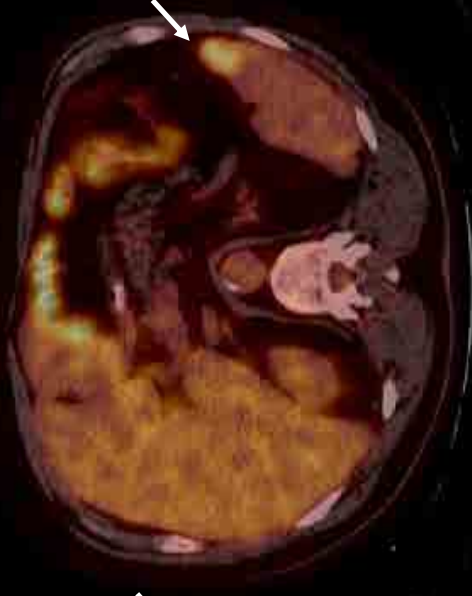
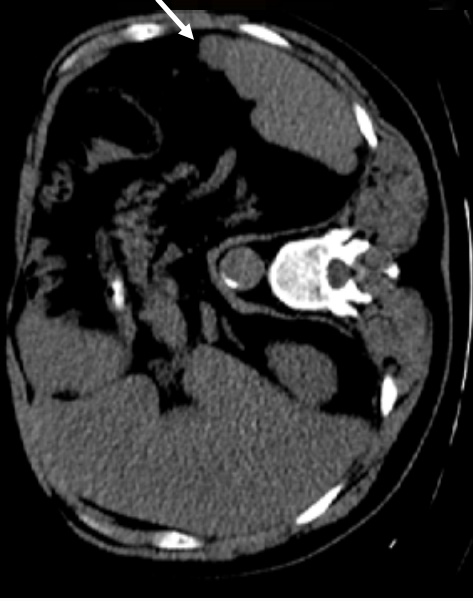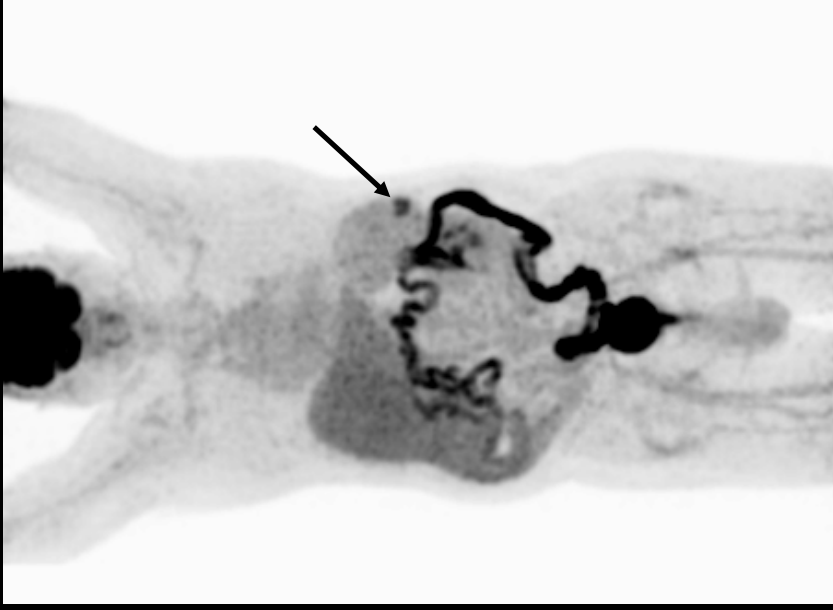
Impression: Histology confirmed suspected splenic metastasis. Fairly intense FDG uptake in the colon is either physiologic or secondary to medication (anti-diabetic).

Follow-up

Tissue biopsy followed by surgery with curative intent.

Consequences of the current PET/CT examination reported here

Upstage of disease and change in treatment plan.



Colon cancer

72 y/o M patient with colon cancer.

FDG-PET/CT requested for restaging shows focal splenic uptake corresponding to a hypodense area (arrow). Splenectomy was performed and histology confirmed the presence of a metastasis.

12. GASTROINTESTINAL TRACT: GASTROINTESTINAL STROMAL TUMOUR

12.1. CASE NO. GI GIST 1

Study type:	Oncology	Clinical indication:	GIST
Clinical indication for PET/CT:	Therapy response assessment (Gleevec)		
Keywords:	GIST Liver metastases		
PET/CT system:	Philips TF 64	Tracer:	FDG
Uptake:	55 min	Dose:	407 MBq
Range:	WB	Blood glucose:	4.6 mmol/L
No. beds:	10	Min/bed:	1.5
Tube loading:	150 mAs	Tube voltage:	120 kVp

Short clinical history

A 54 year old male patient diagnosed with a rectal GIST 5 years ago. CECT showed multiple hepatic metastases. Patient was treated with imatinib.

PET/CT findings

(A) FDG–PET/CT for therapy follow-up performed 3 years ago showed multiple hypodense lesions in the liver without increased FDG uptake and a presacral lesion with focal uptake suspicious for local recurrence. Treated with targeted therapy.

Impression: 1st follow-up — CMR in liver metastasis, suspected local recurrence.

(B) FDG–PET/CT for therapy follow-up showed increased FDG uptake in all liver lesions but no evidence of increase of FDG uptake in the presacral lesion.

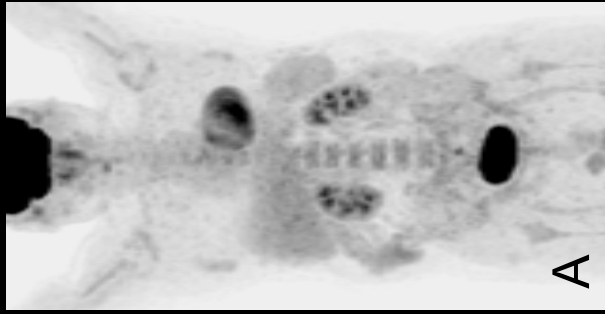
Impression: Progression of disease with metabolically active liver metastasis. No evidence of FDG uptake in the presacral region (likely reactive tissue on prior PET/CT scan).

Follow-up

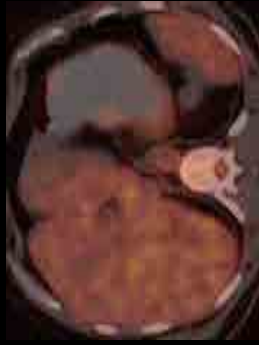Treatment: ChTx with curative intent.

Consequences of the current PET/CT examination reported here

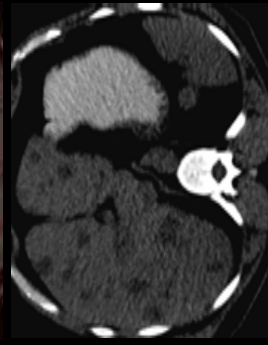Upstage of disease and change in treatment plan.



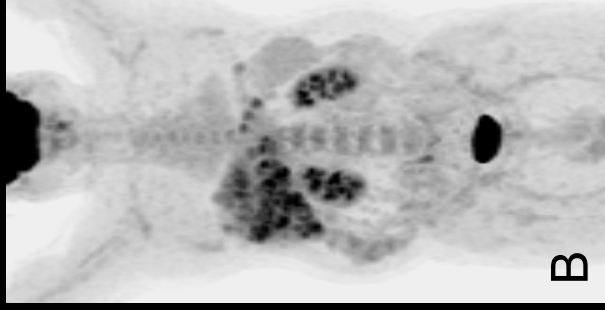
A



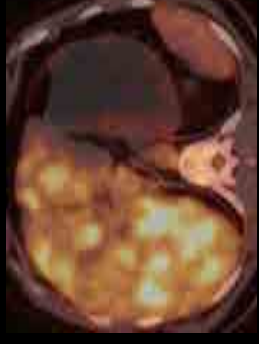A1



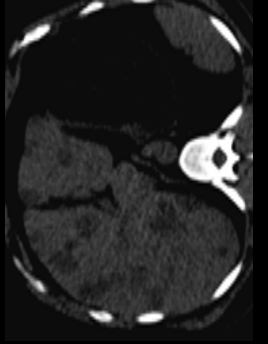A2



B



B1



B2



Gastrointestinal stromal tumour

54 y/o M patient diagnosed with GIST s/p resected rectal cancer. CECT for follow-up showed hepatic metastatic disease. Treated with targeted therapy (imatinib).

(A) FDG-PET/CT requested for therapy follow-up shows multiple hypodense liver lesions w/o increased FDG uptake and presacral focal FDG avidity.

(B) FDG-PET/CT requested for therapy follow-up 2 years later shows progressive disease with metabolically active liver metastasis; no FDG-uptake in presacral region.

13. PELVIS: OVARY

13.1. CASE NO. PE OV 1

Study type:	Oncology	Clinical indication:	Ovarian cancer
Clinical indication for PET/CT:	Initial staging		
Keywords:	Ovarian cancer LN metastasis		
PET/CT system:	Philips TF 64	Tracer:	FDG
Uptake:	55 min	Dose:	310 MBq
Range:	WB	Blood glucose:	5.4 mmol/L
No. beds:	9	Min/bed:	1
Tube loading:	100 mAs	Tube voltage:	120 kVp

Short clinical history

A 58 year old female patient with history of breast cancer treated with lumpectomy and RTx. Referred for PET/CT for initial staging of clinically suspected ovarian cancer.

PET/CT findings

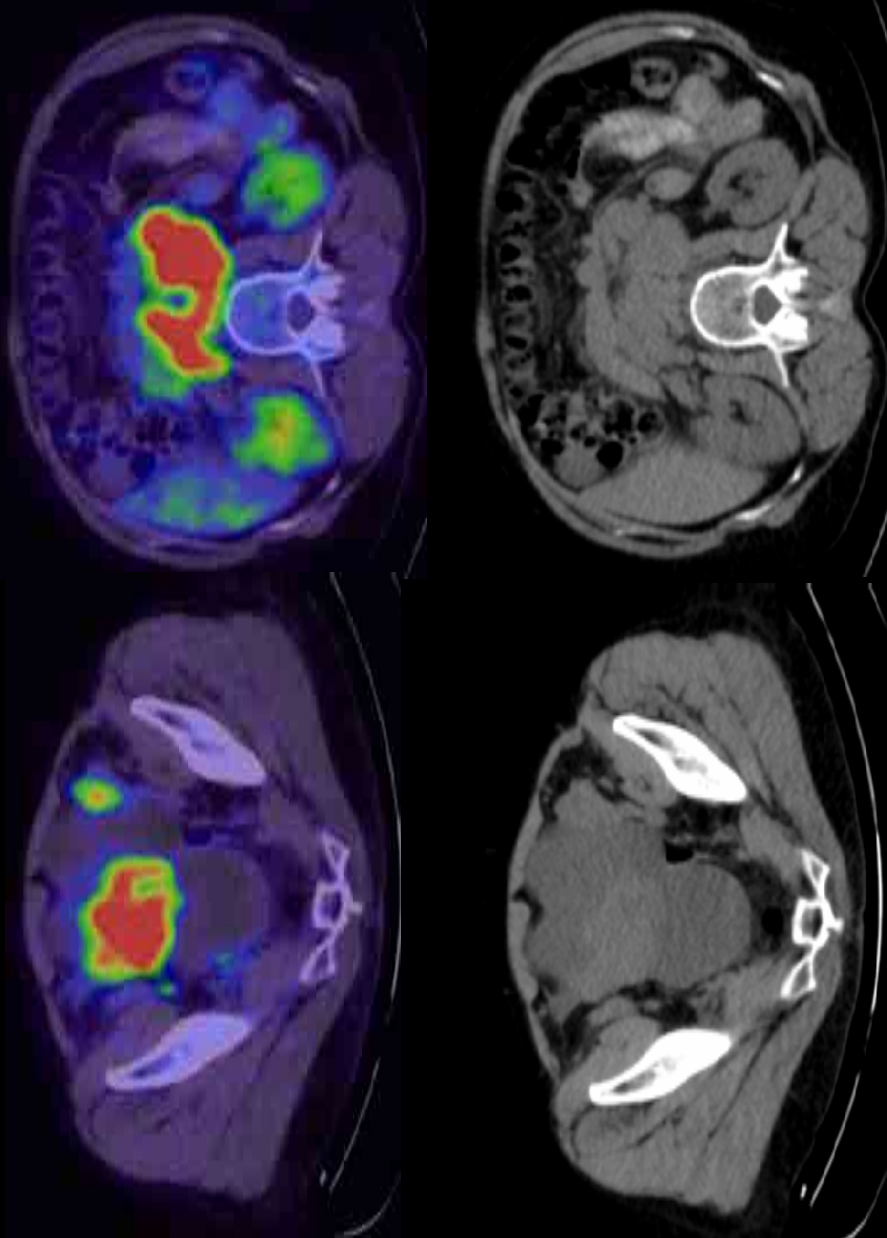
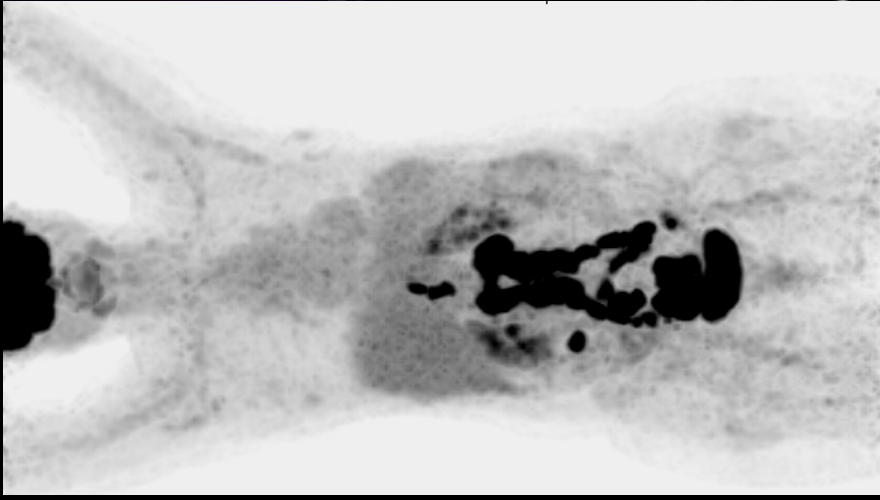
Intense FDG uptake by a right ovarian multilocular cystic tumour and the multiple metastatic LNs in the retrocrural, para-aortic and para-iliac regions.

Follow-up

Treatment: ChTx.

Consequences of the current PET/CT examination reported here

Upstage of disease and change in treatment plan.



Ovarian cancer

58 y/o F patient with history of breast cancer. FDG-PET/CT requested for initial staging of ovarian cancer.

Right ovarian multilocular cystic tumour with multiple retroperitoneal metastatic LNs.

13.2. CASE NO. PE OV 2

Study type:	Oncology	Clinical indication:	Ovarian cancer
Clinical indication for PET/CT:	Initial staging		
Keywords:	Ovarian cancer Secondary cancer		
PET/CT system:	Philips TF 64	Tracer:	FDG
Uptake:	57 min	Dose:	308 MBq
Range:	WB	Blood glucose:	5.0 mmol/L
No. beds:	8	Min/bed:	1
Tube loading:	100 mAs	Tube voltage:	120 kVp

Short clinical history

A 75 year old female patient with history of breast cancer (histology: IDC, treated with ChTxRT) and bladder cancer (histology: transitional cell, treated with surgery and intravesical ChTx).

PET/CT findings

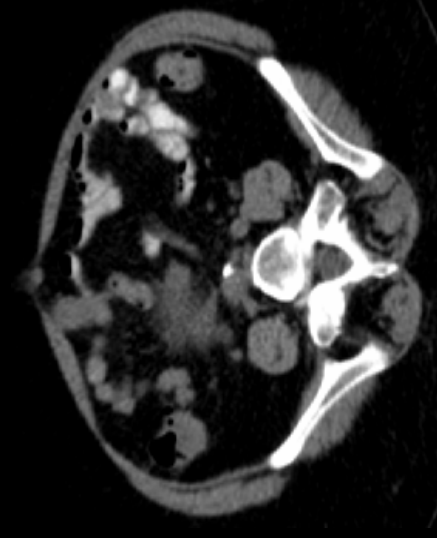
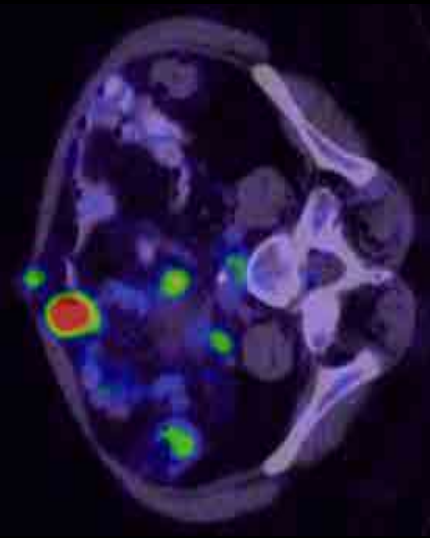
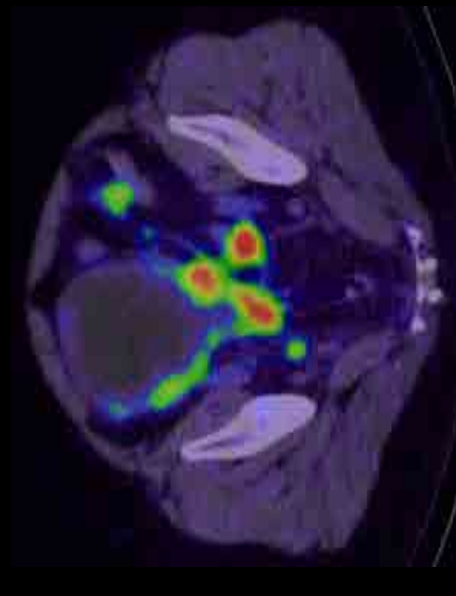
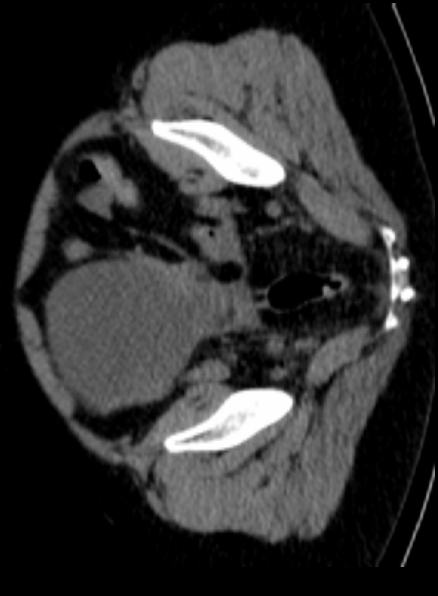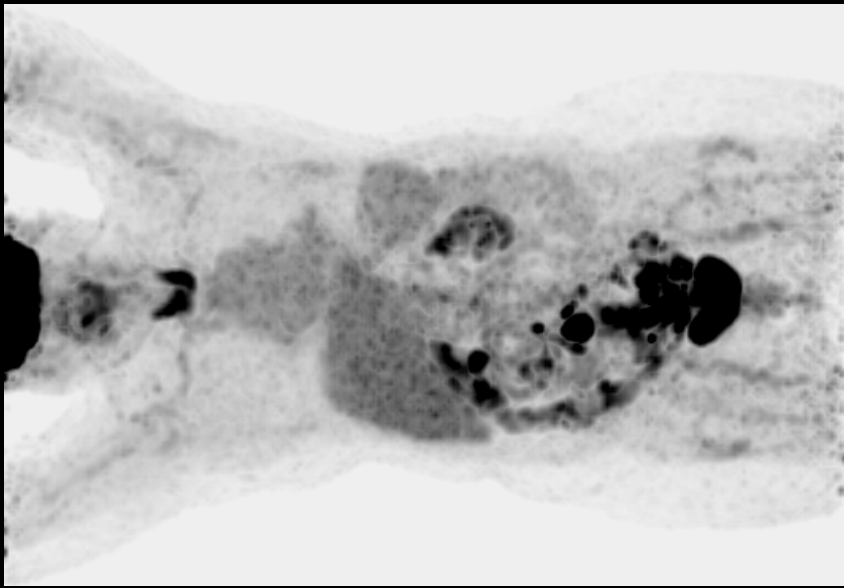
FDG–PET/CT scan for initial staging shows an FDG avid right cystic ovarian tumour mass with multiple peritoneal implants and several retroperitoneal metastatic LNs.

Follow-up

Treatment: ChTx with palliative intent.

Consequences of the current PET/CT examination reported here

Upstage of disease and change in treatment plan.



Ovarian cancer

75 y/o F patient with history of breast cancer and bladder cancer.

FDG-PET/CT requested for initial staging shows right cystic ovarian tumour with multiple peritoneal implants and retroperitoneal metastatic LNs.

14. PELVIS: CERVIX

14.1. CASE NO. PE CV 1

Study type:	Oncology	Clinical indication:	Cervical cancer
Clinical indication for PET/CT:	Initial staging		
Keywords:	Cervical cancer Peritoneal carcinomatosis		
PET/CT system:	Philips TF 64	Tracer:	FDG
Uptake:	55 min	Dose:	525 MBq
Range:	WB	Blood glucose:	5.2 mmol/L
No. beds:	9	Min/bed:	3
Tube loading:	200 mAs	Tube voltage:	120 kVp

Short clinical history

A 66 year old female patient with suspected diagnosis of cervical cancer (histology: endometrioid adenocarcinoma).

PET/CT findings

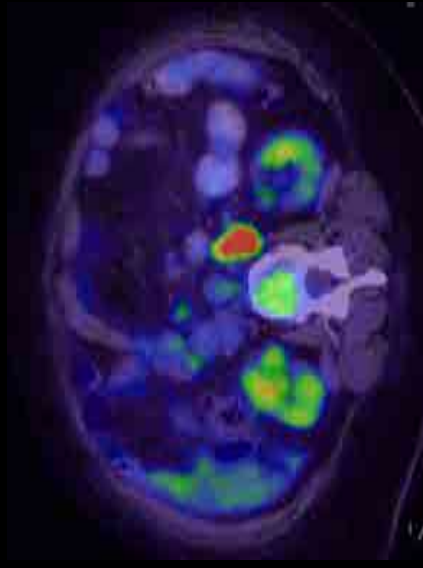
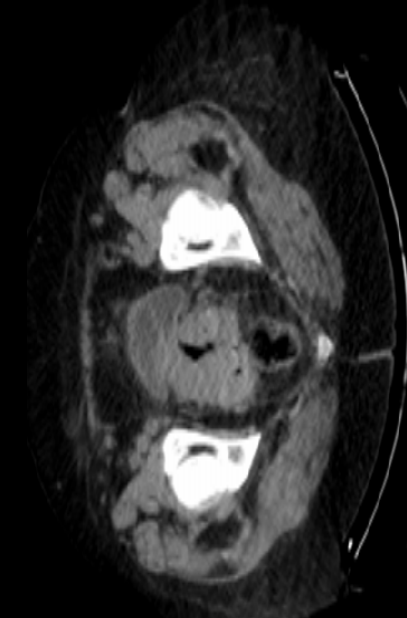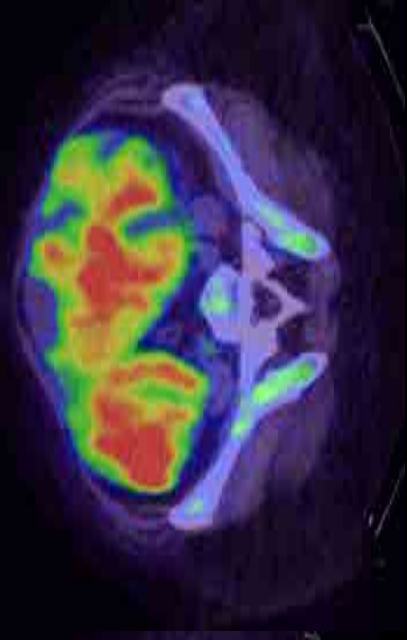
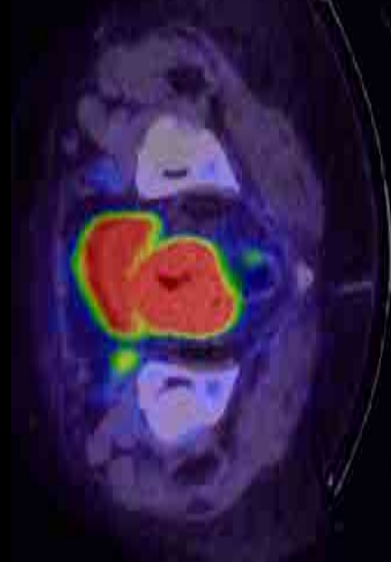
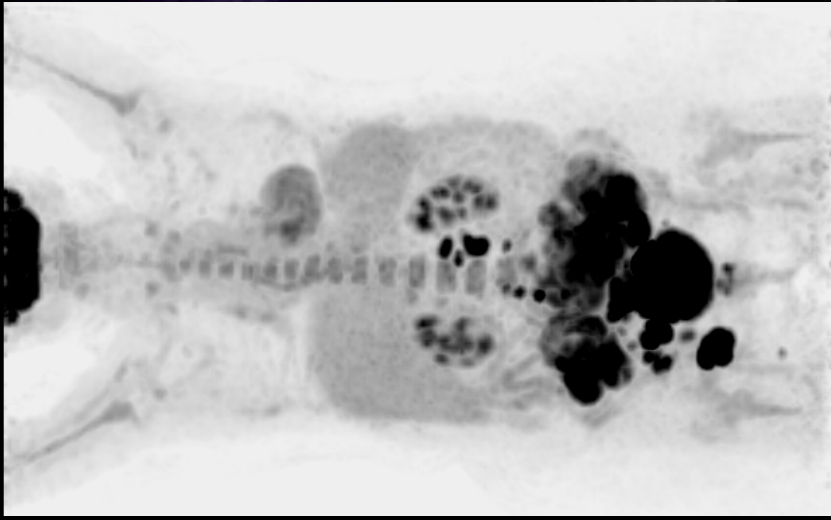
FDG–PET/CT for initial staging shows intense uptake in the cervix corresponding to the malignant tumour with an additional large peritoneal metastatic conglomerate (‘omental cake’). Furthermore, multiple FDG avid metastatic LNs in the retroperitoneal, para-iliac and right inguinal regions are also depicted.

Follow-up

Treatment: ChTxRT.

Consequences of the current PET/CT examination reported here

Upstage of disease and change in treatment plan.



Cervical cancer

66 y/o F patient diagnosed with cervical cancer.

FDG-PET/CT requested for initial staging shows cervical tumour and peritoneal metastatic conglomerate and multiple metastatic LNs.

Note diffuse uptake in the bones corresponding to increased bone marrow activity.

14.2. CASE NO. PE CV 2

Study type:	Oncology	Clinical indication:	Cervical cancer
Clinical indication for PET/CT:	Initial staging		
Keywords:	Cervical cancer LN metastasis		
PET/CT system:	Philips TF 64	Tracer:	FDG
Uptake:	55 min	Dose:	310 MBq
Range:	WB	Blood glucose:	5.1 mmol/L
No. beds:	9	Min/bed:	1
Tube loading:	100 mAs	Tube voltage:	120 kVp

Short clinical history

A 62 year old female patient diagnosed with cervical cancer and no history of prior major diseases.

PET/CT findings

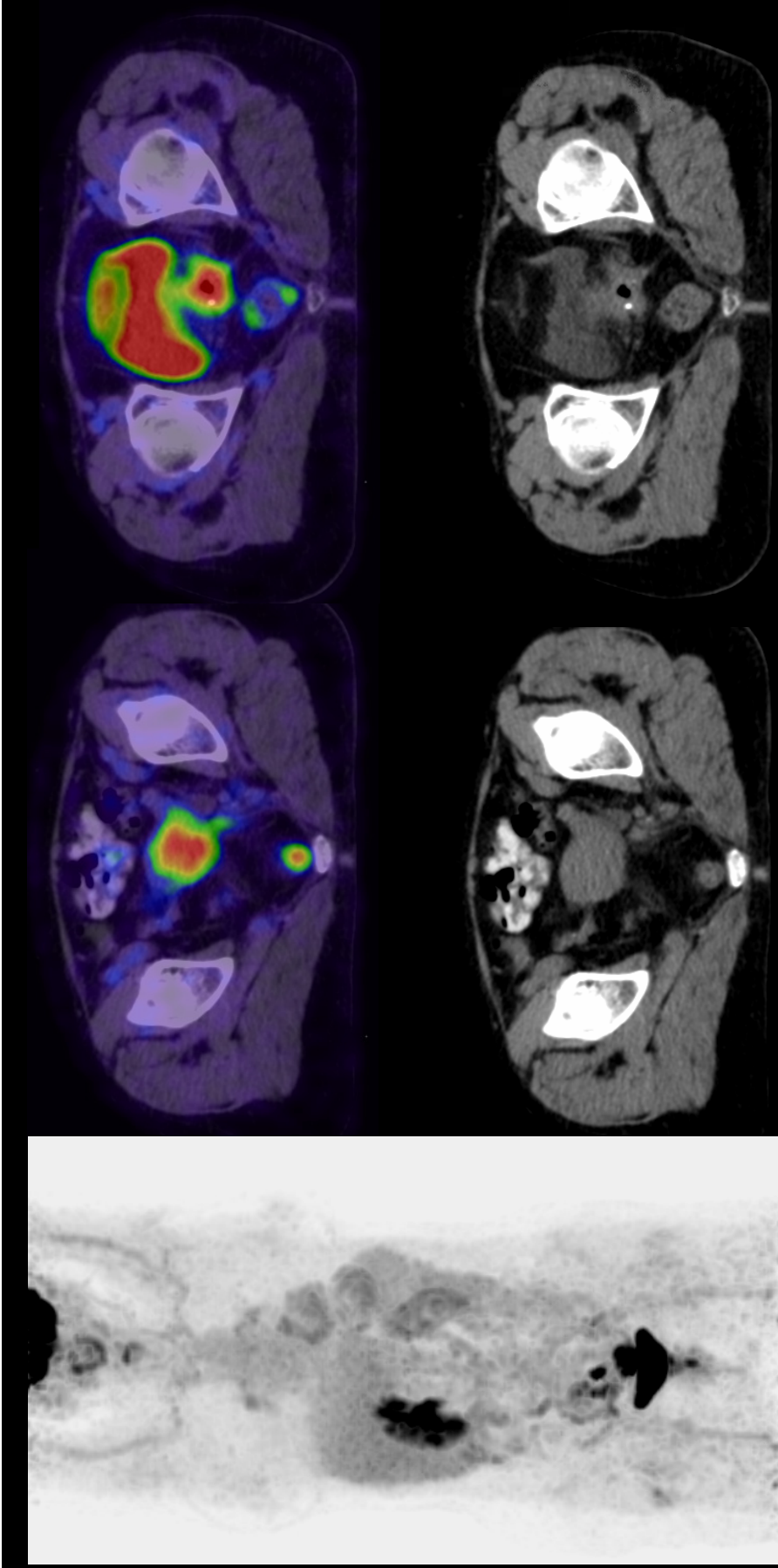
FDG–PET/CT scan requested for initial staging shows intense FDG uptake in the cervical region corresponding to the primary malignant tumour obstructing the left ureter (note the decreased uptake of the left kidney). Additional FDG avid nodal metastasis can be seen in the right common iliac region.

Follow-up

Treatment: RTx.

Consequences of the current PET/CT examination reported here

No change in treatment plan.



Cervical cancer

62 y/o F patient diagnosed with cervical cancer.

FDG-PET/CT requested for initial staging shows intense uptake in the cervix and in a LN at the right iliac artery. Note the decreased uptake of the left kidney caused by the obstruction of the left ureter.

14.3. CASE NO. PE CV 3

Study type:	Oncology	Clinical indication:	Cervical cancer
Clinical indication for PET/CT:	Initial staging		
Keywords:	Cervical cancer LN metastasis Pitfall		
PET/CT system:	Philips TF 64	Tracer:	FDG
Uptake:	59 min	Dose:	346 MBq
Range:	WB	Blood glucose:	4.9 mmol/L
No. beds:	9	Min/bed:	1
Tube loading:	120 mAs	Tube voltage:	100 kVp

Short clinical history

A 58 year old female patient with recent history of cervical cancer, presented with bleeding disorders.
Histology from curettage: Clear cell adenocarcinoma.
PET/CT scan was requested for initial staging purposes.

PET/CT findings

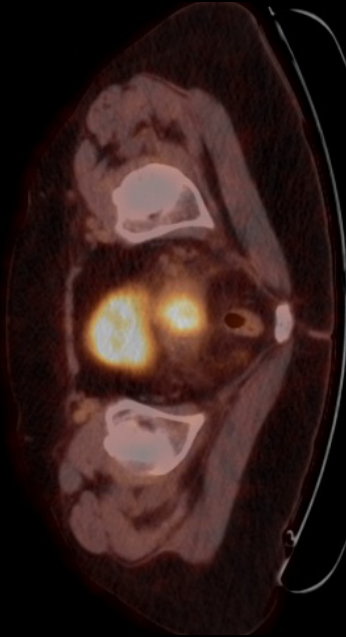
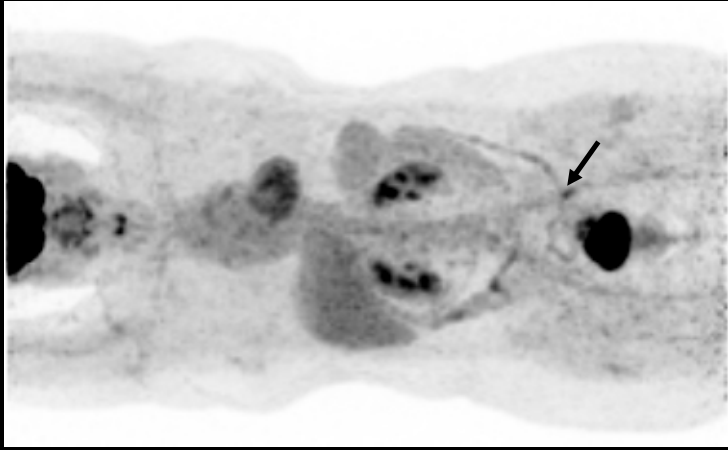
- (A) Intense FDG uptake can be seen in the uterine cervix invading the proximal part of the corpus as well. There is an FDG avid subcentimetre LN in the left para-iliac chain.
- (B) On delayed images both focal uptakes show increasing activity. However, there is no evidence of distant metastases.

Follow-up

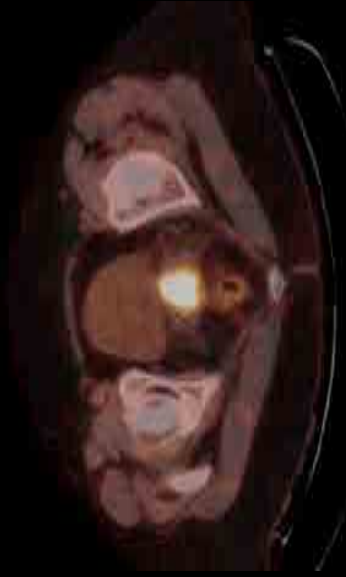Treatment: ChTxRT with curative intent.

Consequences of the current PET/CT examination reported here

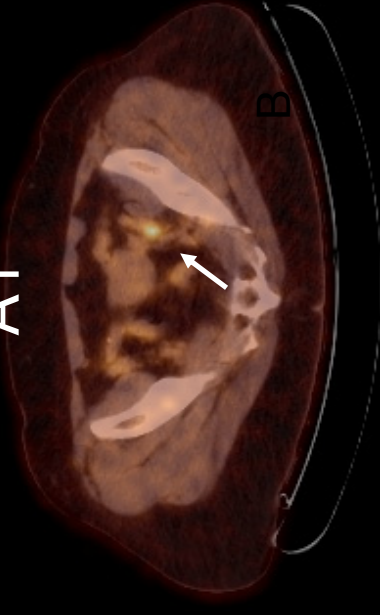
Upstage of disease and change in treatment plan.



A1



A2



B

Cervical cancer

58 y/o F patient referred for FDG-PET/CT for primary staging of cervical cancer.

(A1) PET/CT (60 min pi) shows the cervical cancer and an FDG avid small LN in the left parailiacal chain.

(A2) Delayed PET/CT (180 min pi + IV Furosemide) of the pelvis shows increased activity of the LN (increase of SUV_{max}). Note: No significant activity in the bladder.

14.4. CASE NO. PE CV 4

Study type:	Oncology	Clinical indication:	Cervical cancer
Clinical indication for PET/CT:	Monitoring ChTxRT		
Keywords:	Cervical cancer LN metastasis Therapy response		
PET/CT system:	Philips TF 64	Tracer:	FDG
Uptake:	69 min	Dose:	316 MBq
Range:	WB	Blood glucose:	6.0 mmol/L
No. beds:	9	Min/bed:	1
Tube loading:	100 mAs	Tube voltage:	120 kVp

Short clinical history

A 50 year old female patient with cervical cancer.

PET/CT findings

(A) Initial staging PET/CT scan shows the primary cervical cancer with multiple metastatic LNs retroperitoneum. Subsequently, the patient was treated with ChTxRT.

Follow-up FDG–PET/CT for therapy response assessment was performed.

(B) Complete metabolic and partial morphologic response of the infradiaphragmatic LN metastasis.

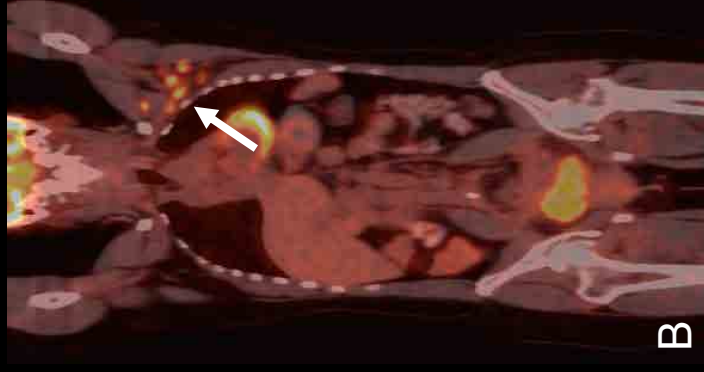
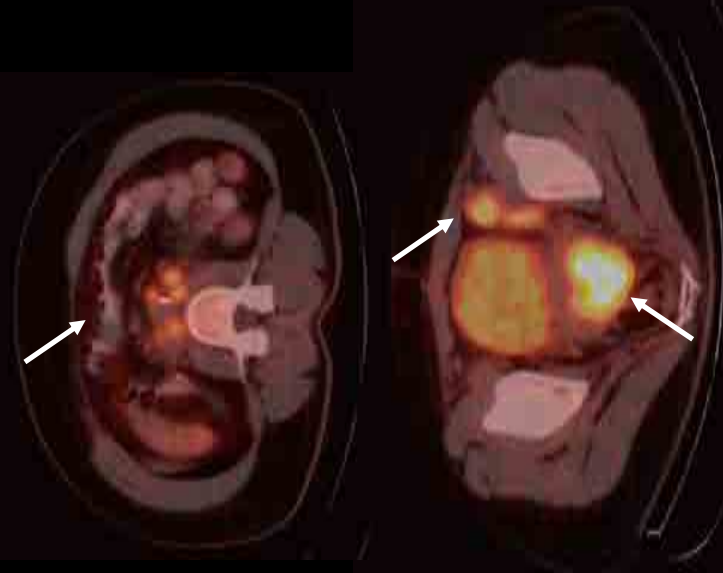
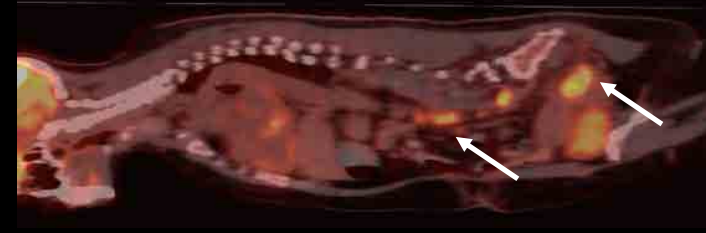
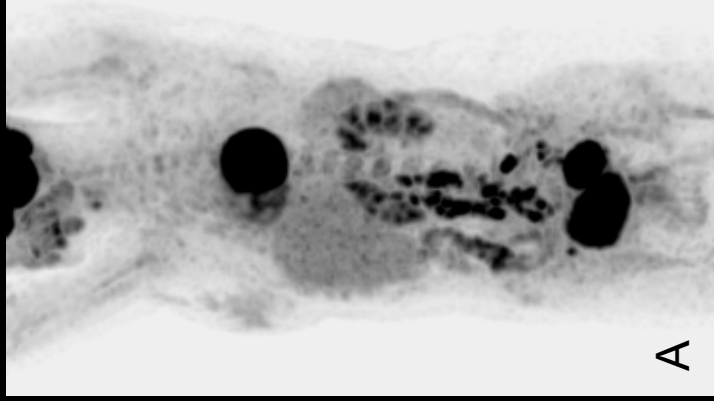
Additional secondary finding: Probably metastatic LNs from occult breast carcinoma in the left axilla, subpectoral and in the supraclavicular regions. A biopsy recommended.

Follow-up

Additional imaging and tissue biopsy.

Consequences of the current PET/CT examination reported here

Upstage of disease and change in treatment plan.



Cervical cancer

50 y/o F patient with cervical cancer. FDG-PET/CT requested for therapy planning.

(A) FDG-PET/CT shows the primary tumour and metastatic LN retroperitoneum. Treated with ChTxRT.

(B) Restaging FDG-PET/CT: positive response for infradiaphragmatic LN. Secondary finding: metastatic disease from occult breast cancer.

15. LYMPHOMA

15.1. CASE NO. LY 1

Study type:	Oncology	Clinical indication:	Lymphoma
Clinical indication for PET/CT:	T-cell lymphoma, initial staging		
Keywords:	Lymphoma		
PET/CT system:	GE Discovery 690 TOF	Tracer:	FDG
Uptake:	63 min	Dose:	222 MBq
Range:	WB	Blood glucose:	4.7 mmol/L
No. beds:	7	Min/bed:	2
Tube loading:	120 mAs	Tube voltage:	80 kVp

Short clinical history

A 63 year old female patient with general malaise complaining of right-sided nasal congestion. Biopsy of the mucosa of the right nasal region demonstrated a T-cell lymphoma. Subsequently, the patient was referred for an FDG–PET/CT scan for staging purposes.

PET/CT findings

FDG–PET/CT scan shows a soft tissue mass within the right nose with high FDG uptake. Parts of the anterior ethmoidal cells are filled with FDG avid soft tissue, too. All other adjacent sinuses are ventilated. No signs of local bone destruction, no signs of any other tumour involvement.

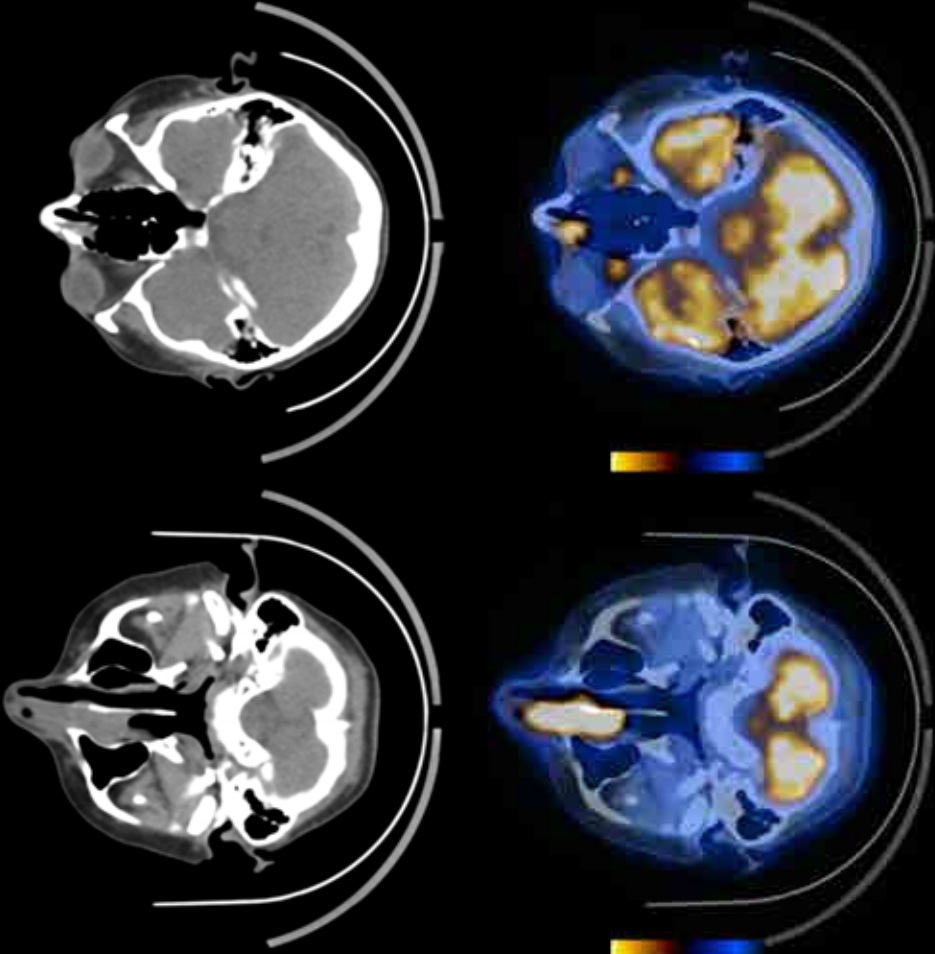
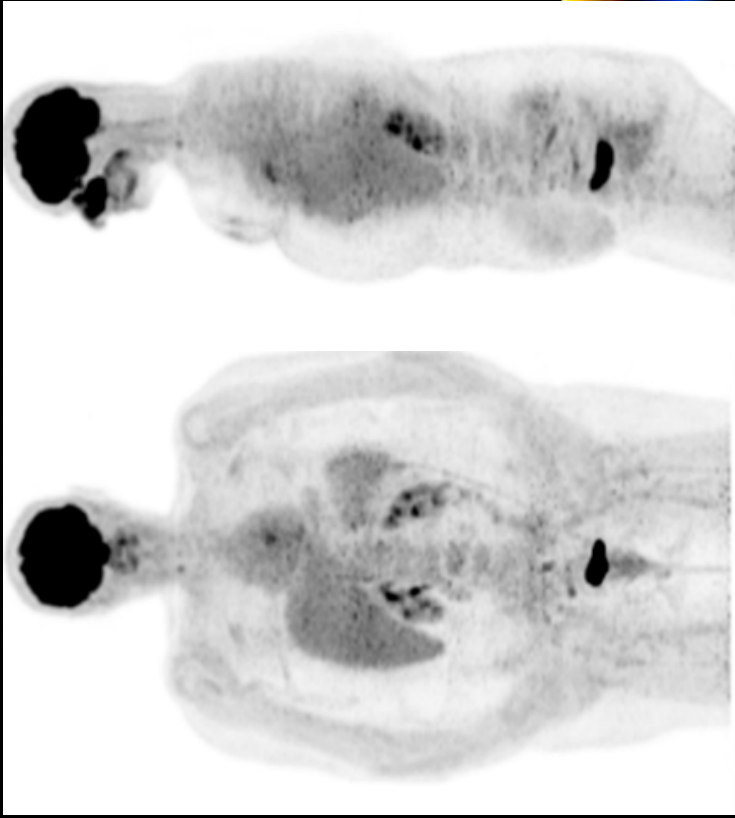
Impression: Localized FDG avid T-cell lymphoma of the right nose, with no evidence of additional signs of tumour involvement.

Follow-up

Treatment: ChTx.

Consequences of the current PET/CT examination reported here

No change in treatment plan.



T-cell lymphoma

63 y/o F patient with primary diagnosis of T-cell lymphoma of the right nose.

FDG-PET/CT requested for initial staging, shows a soft tissue mass within the right nose with high FDG uptake. Parts of the anterior ethmoidal cells are also filled with FDG avid soft tissue. All other adjacent sinuses are ventilated. No signs of local osseous destruction, no signs of any other lymphoma manifestation within the field of view.

15.2. CASE NO. LY 2

Study type:	Oncology	Clinical indication:	Lymphoma
Clinical indication for PET/CT:	DLBCL, initial staging, monitoring treatment response during ChTx		
Keywords:	Lymphoma Bone marrow involvement Treatment response		
PET/CT system:	Philips 64 TF	Tracer:	FDG
Uptake:	59/57 min	Dose:	345/329 MBq
Range:	WB	Blood glucose:	6.3 mmol/L
No. beds:	8/9	Min/bed:	1
Tube loading:	120 mAs	Tube voltage:	100 kVp

Short clinical history

A 63 year old female patient with DLBCL referred for an FDG–PET/CT scan for initial staging purposes.

PET/CT findings

- (A) Initial FDG–PET/CT scan demonstrates FDG avid LNs (10–15 mm) in the left supraclavicular, retropancreatic, retrocrural and right para-iliac region. Focal FDG uptake in the middle third of the sternal body without corresponding morphological correlate.
- (B) FDG–PET/CT scan requested for assessment of follow-up after 2 cycles of CHOP ChTx shows a complete response to therapy with no residual FDG avid lesions. Moderately increased FDG uptake in the bone marrow secondary to ChTx.

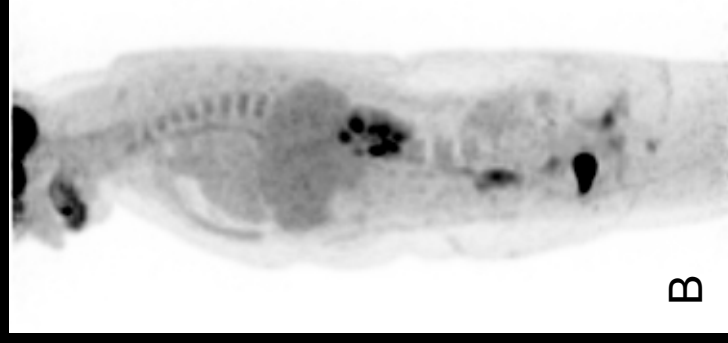
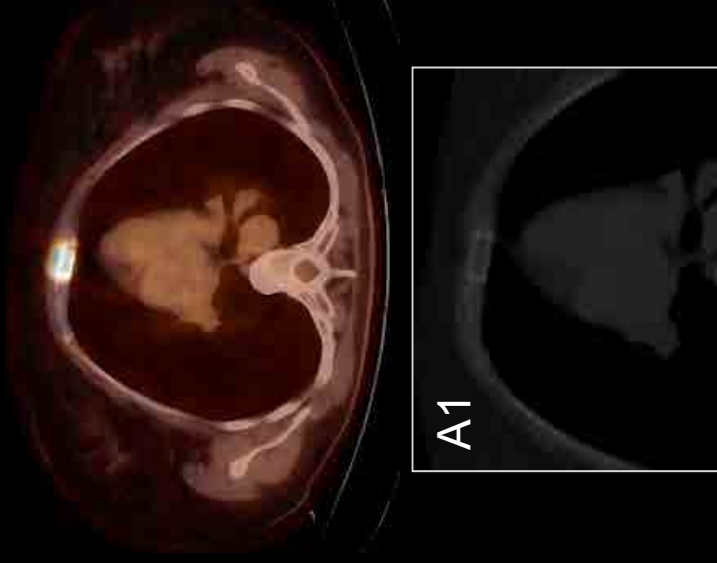
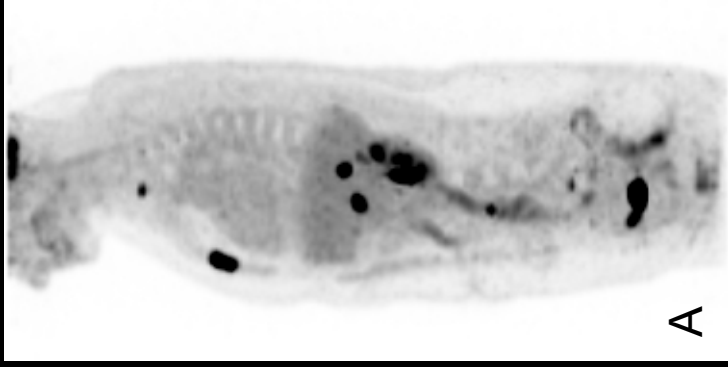
Impression: Focal bone marrow involvement at initial staging and retroperitoneal lymphoma manifestations. CMR in FDG–PET/CT at therapy follow-up.

Follow-up

Treatment: ChTxRT with curative intent.

Consequences of the current PET/CT examination reported here

No change in treatment plan.



Diffuse large B-cell lymphoma

63 y/o F patient with DLBCL referred for a FDG-PET/CT scan for initial staging purposes.

(A) FDG-PET/CT requested for initial staging shows pathologic supra and infradiaphragmatic LNs and a solitary sternal lesion (A1), without morphological correlate on CT. Bone marrow (iliac bone) biopsy was negative. Treated with 2 cycles ChTx.

(B) FDG-PET/CT requested for therapy control 1 month after onset of treatment was negative.

15.3. CASE NO. LY 3

Study type:	Oncology	Clinical indication:	Lymphoma
Clinical indication for PET/CT:	NHL, initial staging, monitoring treatment response during ChTx		
Keywords:	Lymphoma Treatment response		
PET/CT system:	Philips 64 TF	Tracer:	FDG
Uptake:	60 min	Dose:	296 MBq
Range:	WB	Blood glucose:	4.5 mmol/L
No. beds:	10	Min/bed:	1
Tube loading:	120 mAs	Tube voltage:	100 kVp

Short clinical history

A 21 year old male patient initially presented with multiple subcutaneous nodules and lymphadenopathy throughout his body. Biopsy of the left clavicular region was diagnostic of a T-cell NHL. Clinically, he was staged as IIIB. Bone marrow failed to demonstrate any involvement. FDG–PET/CT scan was requested for initial staging.

PET/CT findings

(A) FDG–PET/CT for initial staging showed disseminated cutaneous FDG avid lesions, as well as supra and infradiaphragmatic FDG avid LNs. Moderate diffuse FDG avidity of the bone marrow, no focal bone marrow lesion is detected. Hepatosplenomegaly.

The patient was treated with methotrexate and steroids.

(B) FDG–PET/CT was requested to assess response to therapy. No evidence of FDG avid lesions consistent with complete response to therapy.

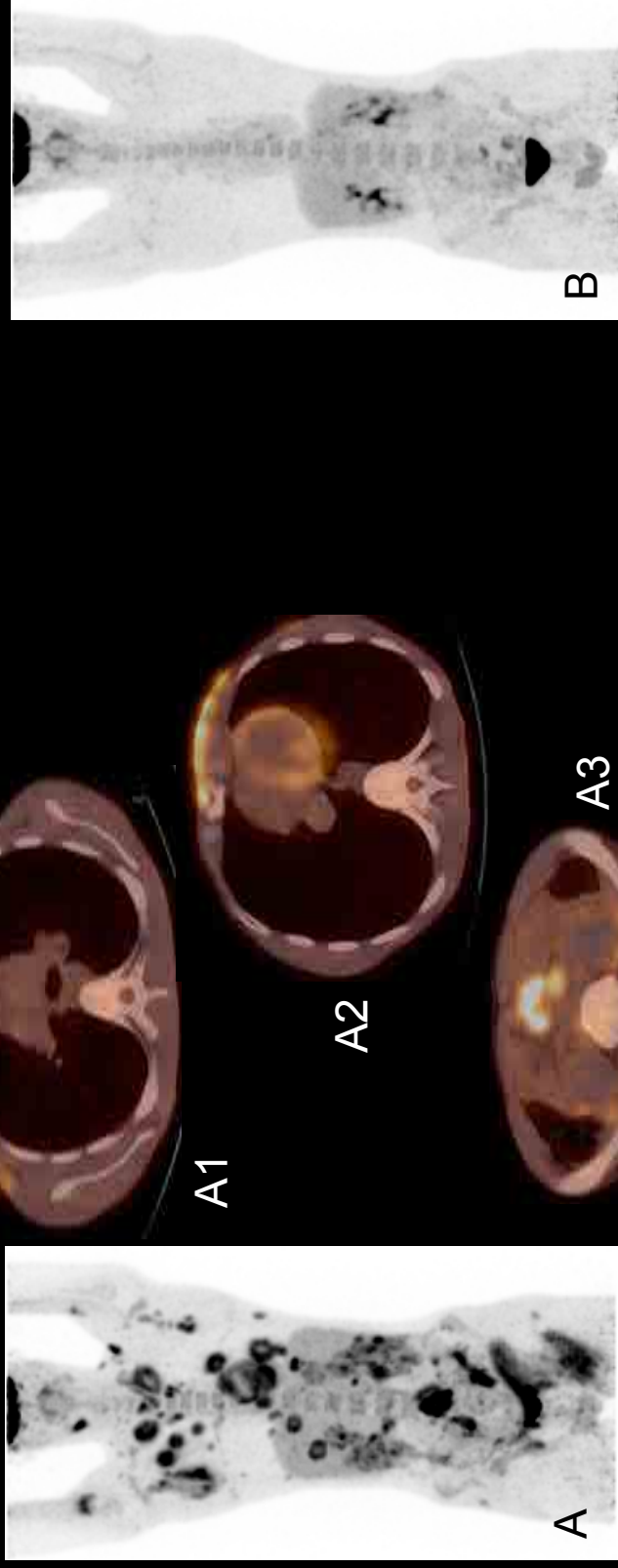
Impression: Mainly cutaneous, including supra and infradiaphragmatic lymphoma involvement with a CMR to therapy seen on the follow-up scan.

Follow-up

Treatment: ChTxRT with curative intent.

Consequences of the current PET/CT examination reported here

No change in treatment plan.



Non-Hodgkin's lymphoma

21 y/o M patient with histologically proven NHL and negative bone biopsy.

(A) FDG-PET/CT requested for initial staging shows stage IV disease with multiple manifestations in the skin (A1 and A2) and abdomen (A3). Treated with ChTx.

(B) FDG-PET/CT requested for therapy follow-up shows CMR consistent with clinical impression.

15.4. CASE NO. LY 4

Study type:	Oncology	Clinical indication:	Lymphoma
Clinical indication for PET/CT:	HD, initial staging, monitoring treatment response during ChTx		
Keywords:	Lymphoma Treatment response		
PET/CT system:	Philips 64 TF	Tracer:	FDG
Uptake:	58/55 min	Dose:	238/262 MBq
Range:	WB	Blood glucose:	5.1 mmol/L
No. beds:	7/8	Min/bed:	1
Tube loading:	120 mAs	Tube voltage:	100 kVp

Short clinical history

A 15 year old female patient presented with chest pain. Chest X ray and CT scan of the chest requested for initial diagnosis and staging demonstrated a large mediastinal mass. FDG–PET/CT was requested for initial staging.

PET/CT findings

- (A) FDG–PET/CT for initial staging shows large supra and infradiaphragmatic FDG avid lesions as well as several foci of increased FDG uptake in the spleen consistent with tumour involvement in this organ. The patient was treated with ChTx.
- (B) FDG–PET/CT scan for therapy monitoring shows diffuse increased FDG uptake throughout the bone marrow and the spleen secondary to post-treatment changes.

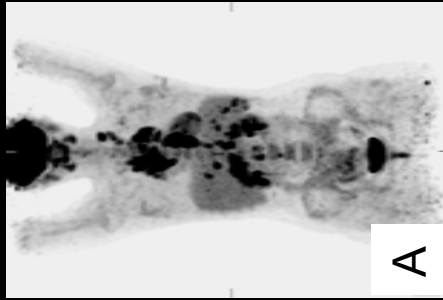
Impression: Supra and infradiaphragmatic lymphoma manifestations with additional spleen involvement at initial staging. CMR observed on the follow-up scan performed 2 months after initiating therapy. There is evidence of reactive bone marrow uptake and splenic uptake, secondary to treatment with ChTx.

Follow-up

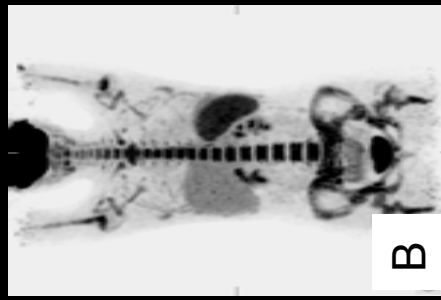
Treatment: ChTxRT with curative intent.

Consequences of the current PET/CT examination reported here

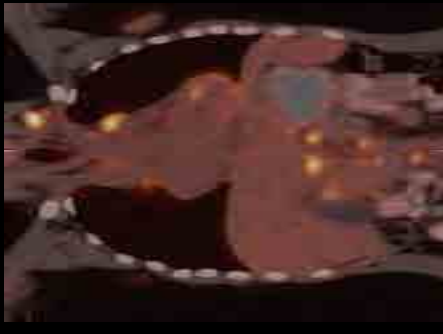
Upstage of disease and change in treatment plan.



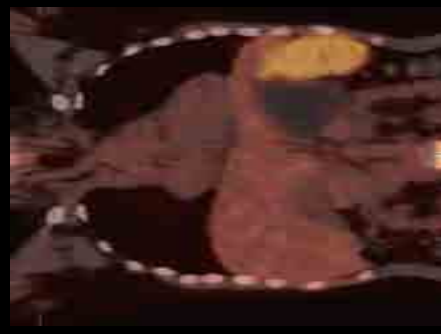
A



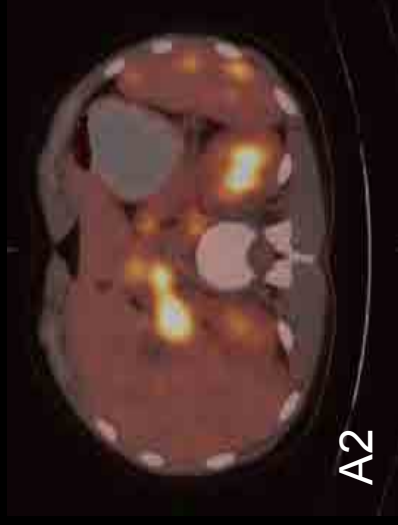B



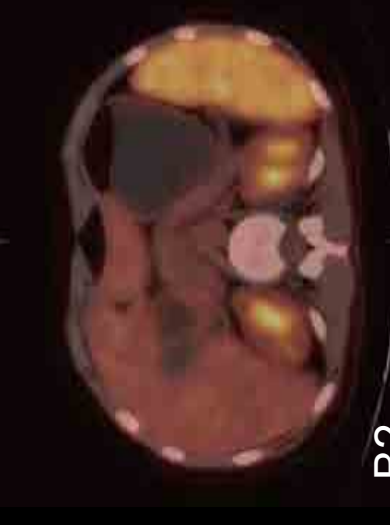A1



B1



A2



B2

Hodgkin's lymphoma

15 y/o F patient with chest pain. Chest X ray and CT demonstrate mediastinal lymphatic disease.

(A) FDG-PET/CT requested for initial staging shows supra (A1) and infradiaphragmatic lymphatic and splenic involvement (A2). Follow-up after ChTx.

(B) FDG-PET/CT for therapy monitoring (+2 mo) shows complete metabolic and morphological remission (B1). Diffuse bone marrow and splenic uptake (B1, B2) owing to therapy.

15.5. CASE NO. LY 5

Study type:	Oncology	Clinical indication:	Lymphoma
Clinical indication for PET/CT:	DLBCL, initial staging, restaging, monitoring treatment response during ChTx		
Keywords:	Lymphoma Treatment response		
PET/CT system:	Philips 64 TF	Tracer:	FDG
Uptake:	56 min	Dose:	470 MBq
Range:	WB	Blood glucose:	5.5 mmol/L
No. beds:	10	Min/bed:	1.5
Tube loading:	150 mAs	Tube voltage:	120 kVp

Short clinical history

A 32 year old male patient initially presented with B symptoms. Chest X ray and subsequent chest CT scan demonstrated a large mediastinal mass. Biopsy performed during mediastinoscopy showed DLBCL. Several FDG–PET/CT scans were requested for initial staging, therapy monitoring, follow-up and restaging.

PET/CT findings

- (A) FDG–PET/CT for initial staging showed a bulky FDG avid mediastinal mass and FDG active mediastinal and retroperitoneal LNs. Patient was treated with with ChTx (R-CHOP).
- (B) FDG–PET/CT for therapy monitoring after 2 cycles of ChTx (+1 mo) shows no FDG avid lesions. The patient was also treated with RTx of the mediastinum due to residual morphological small mass.
- (C) FDG–PET/CT for follow-up at 6 months after initiating therapy, demonstrates reactive diffuse bone marrow uptake secondary to post-treatment changes.
- (D) FDG–PET/CT for follow-up after 13 months of initial diagnosis demonstrates a new FDG avid mediastinal mass consistent with tumour recurrence.

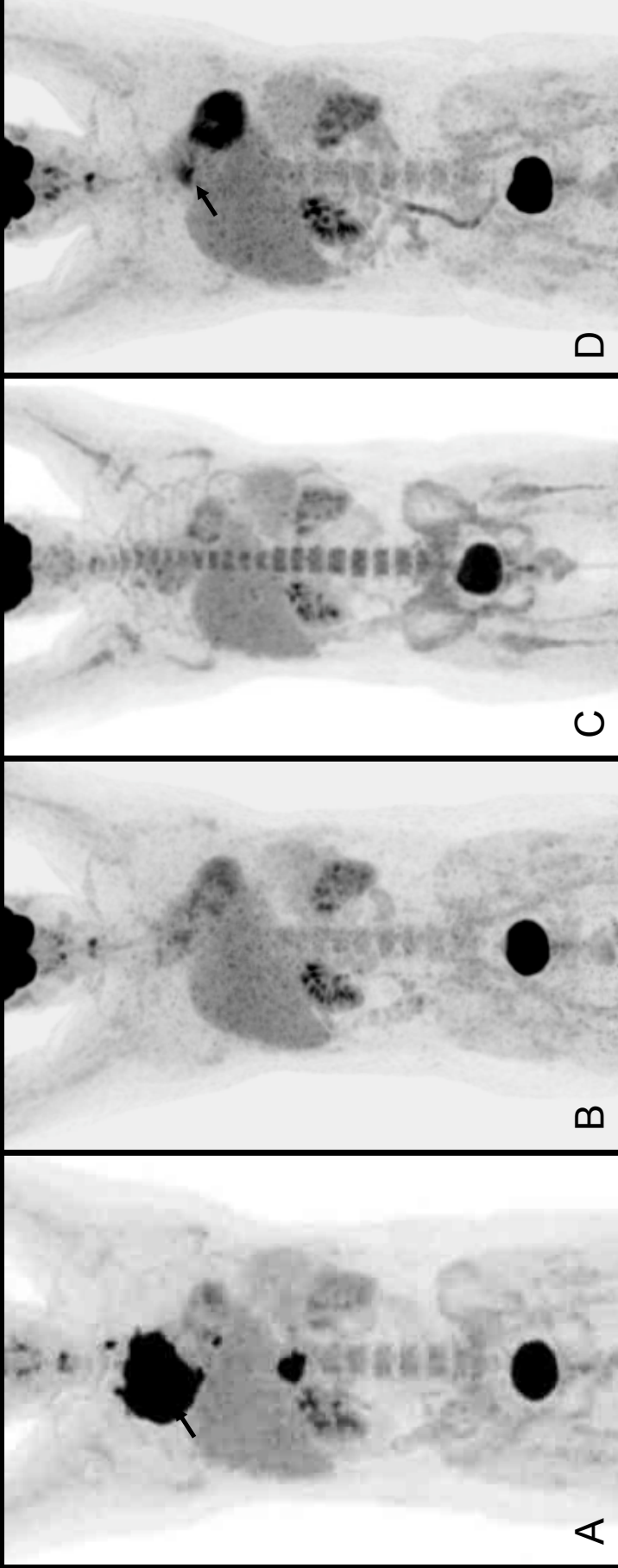
Impression: NHL with supra and infradiaphragmatic lesions from lymphoma with initial CMR, but evidence of early mediastinal recurrence.

Follow-up

Treatment: ChTxRT with curative intent.

Consequences of the current PET/CT examination reported here

Change in treatment plan.



Diffuse large B-cell lymphoma

32 y/o M patient with DLBCL diagnosed 2 years ago (stage IIIA).

- (A) FDG–PET/CT requested for initial staging presented a bulky hypermetabolic mass in the right hilum. Treated with ChTx.
- (B) FDG–PET/CT requested for therapy monitoring (s/p 2 cycles, +1 mo) shows CMR.
- (C) FDG–PET/CT requested for therapy follow-up (s/p CHOP, +6 mo) shows no change.
- (D) FDG–PET/CT requested for restaging (+13 mo) shows recurrent disease.

15.6. CASE NO. LY 6

Study type:	Oncology	Clinical indication:	Lymphoma
Clinical indication for PET/CT:	HD, initial staging		
Keywords:	Lymphoma		
PET/CT system:	Philips 64 TF	Tracer:	FDG
Uptake:	57 min	Dose:	276 MBq
Range:	WB	Blood glucose:	5.2 mmol/L
No. beds:	9	Min/bed:	1
Tube loading:	120 mAs	Tube voltage:	100 kVp

Short clinical history

A 34 year old female patient who initially presented with a jugular mass. Biopsy proved that it was HD. FDG–PET/CT scan was requested for initial staging.

PET/CT findings

FDG–PET/CT for initial staging presents intense FDG activity in a soft tissue mass in the jugular region and the superior anterior mediastinum. However, there is no evidence of tumour involvement throughout the rest of the body.

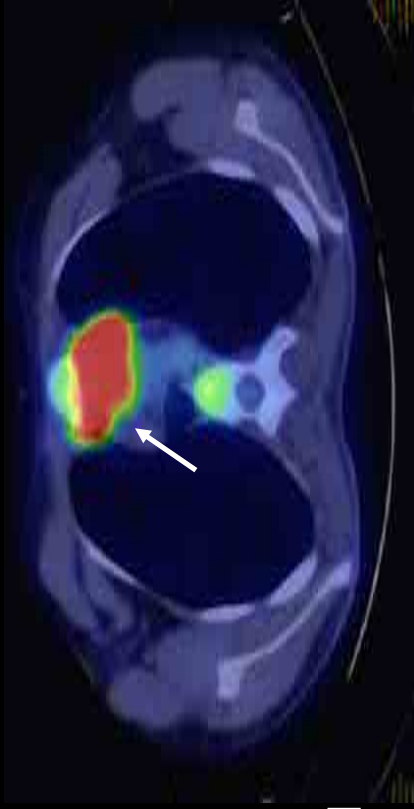
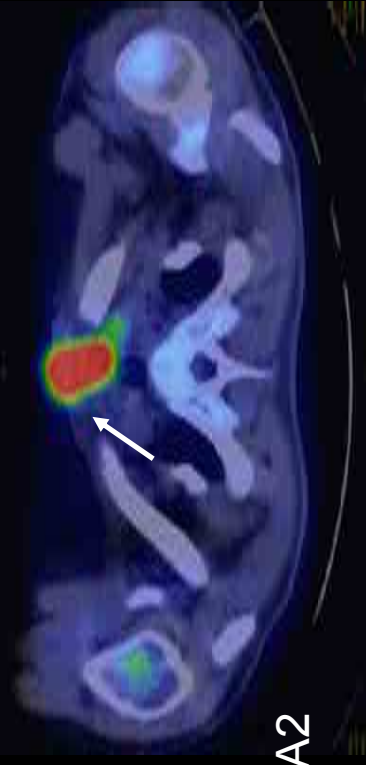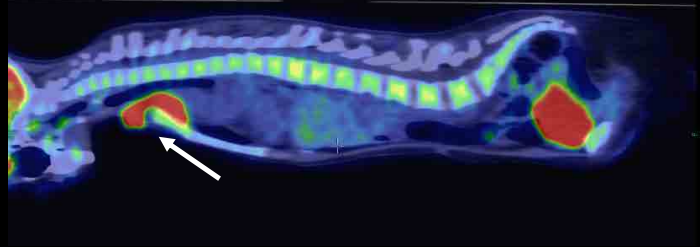
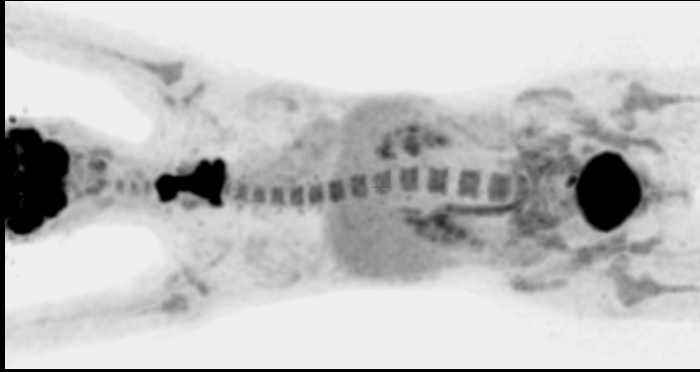
Impression: Jugular and mediastinal/thymic HD lymphoma manifestation.

Follow-up

Treatment: ChTxRT with curative intent.

Consequences of the current PET/CT examination reported here

No change in treatment plan.



Hodgkin's lymphoma

34 y/o F patient with soft tissue mass in the jugular region. Biopsy confirmed HD. FDG-PET/CT for initial staging (A) shows enlarged thymus with high FDG uptake (A2), enlarged FDG-avid LNs in the jugulum (A1) and diffuse bone marrow hypermetabolism.

15.7. CASE NO. LY 7

Study type:	Oncology	Clinical indication:	Lymphoma
Clinical indication for PET/CT:	DLBCL, initial staging, therapy monitoring, restaging		
Keywords:	Lymphoma Therapy response		
PET/CT system:	Philips 64 TF	Tracer:	FDG
Uptake:	57 min	Dose:	233 MBq
Range:	WB	Blood glucose:	5.1 mmol/L
No. beds:	9	Min/bed:	1
Tube loading:	120 mAs	Tube voltage:	100 kVp

Short clinical history

A 53 year old female patient with history of NHL diagnosed 10 years ago, initially treated with ChTx and ASCT. She had a first relapse after 7 years, which was treated with additional ChTx and RTx to the cervical region achieving a CMR. She had a second relapse 10 years after the initial diagnosis. FDG–PET/CT scan was requested for restaging purposes and for therapy monitoring.

PET/CT findings

- (A) FDG–PET/CT for restaging showed multiple FDG avid LNs, splenic lesions, liver lesions as well as FDG avid osseous and lung lesions. Patient was treated with ChTx (R-Hyper-CVAD).
- (B) FDG–PET/CT performed for early assessment of response to therapy demonstrates PMR after 2 cycles of ChTx with a residual FDG avid lesion at the pancreatic head. Otherwise good therapy response.
- (C) FDG–PET/CT for therapy monitoring after 4 cycles of ChTx demonstrated disseminated FDG avid retroperitoneal, mediastinal, osseous and hepatic lesions.

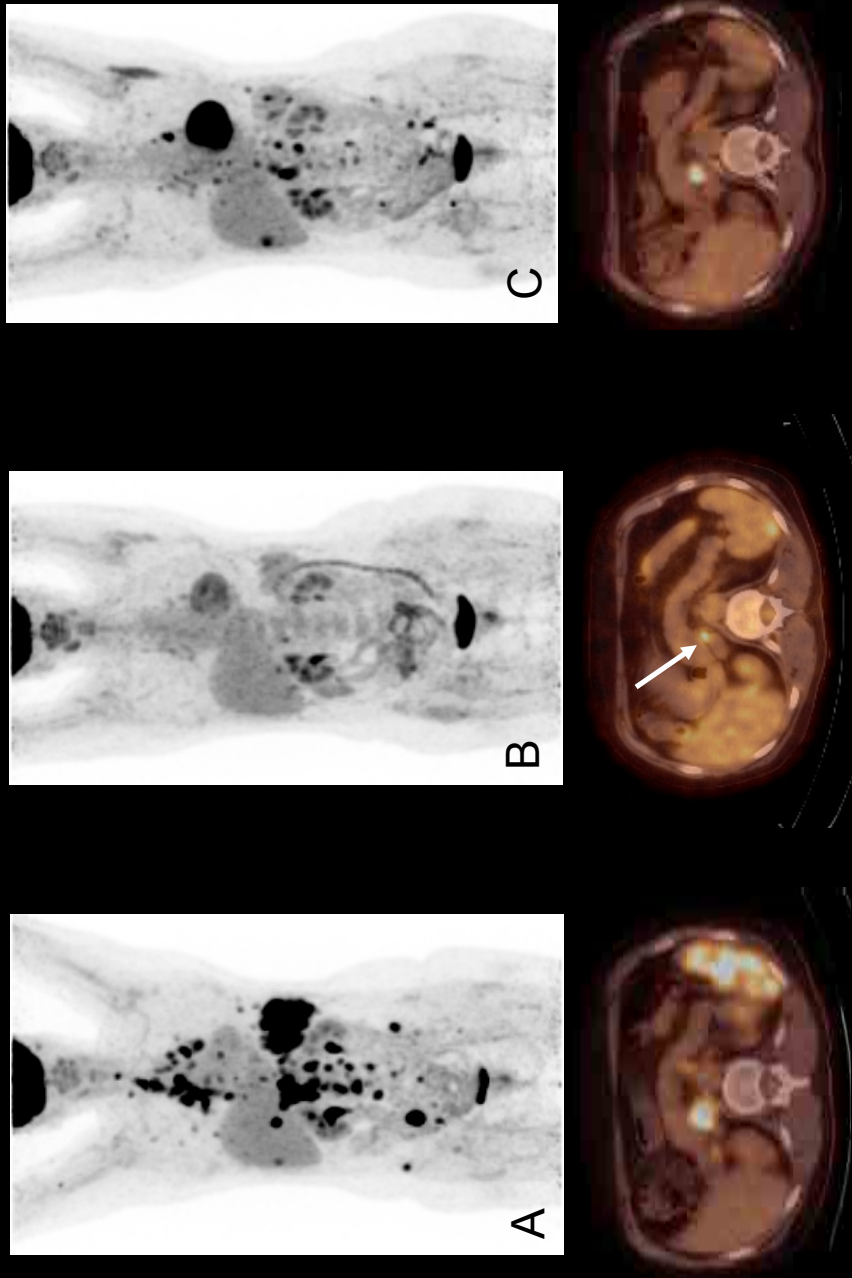
Impression: Diffuse recurrence with supra and infradiaphragmatic, splenic, hepatic, osseous and pulmonary lymphoma manifestations, PMR after therapy and early progressive disease under ongoing therapy.

Follow-up

Treatment: ChTx with curative intent.

Consequences of the current PET/CT examination reported here

No change in treatment plan after first follow-up PET/CT. Change in treatment plan for R-IGEV after final PET/CT.



Diffuse large B-cell lymphoma

53 y/o F patient diagnosed with DLBCL.

(A) FDG–PET/CT requested for staging shows stage IV disease. Treated with ChTx.

(B) FDG–PET/CT requested for therapy monitoring (s/p 2 cycles ChTx, +1 mo) suggests PMR. Small retroperitoneal focus of moderately increased FDG uptake is also seen (arrow).

(C) FDG–PET/CT requested for restaging (s/p 4 cycles ChTx, +3 mo) indicates progressive disease.

15.8. CASE NO. LY 8

Study type:	Oncology	Clinical indication:	Lymphoma
Clinical indication for PET/CT:	NHL, initial staging		
Keywords:	Lymphoma		
PET/CT system:	Philips 64 TF	Tracer:	FDG
Uptake:	58 min	Dose:	289 MBq
Range:	WB	Blood glucose:	4.6 mmol/L
No. beds:	10	Min/bed:	1
Tube loading:	120 mAs	Tube voltage:	100 kVp

Short clinical history

An 18 year old male patient presenting weight loss, cough, palpable and enlarged nodules in the neck and chest. Chest X ray showed an enlarged mediastinum. FDG–PET/CT was requested for initial staging.

PET/CT findings

FDG–PET/CT requested for initial staging showed FDG avid enlarged LNs on both side of the neck, in the mediastinum, in both axilla and the subpectoral region. Right-sided pleural effusion. Slight diffuse bone marrow hypermetabolism, no focal osseous FDG avidity.

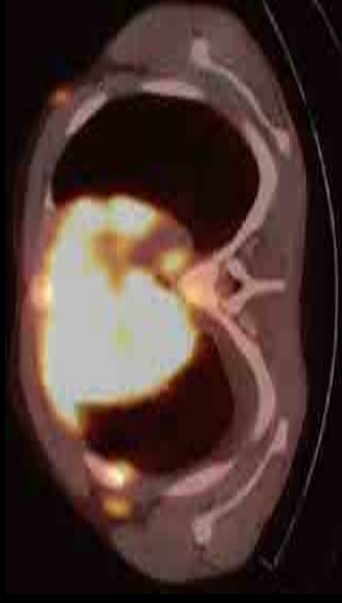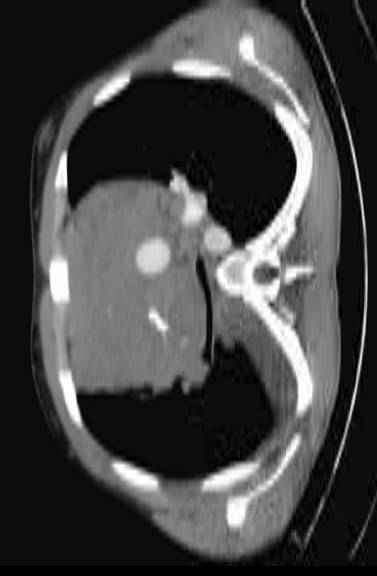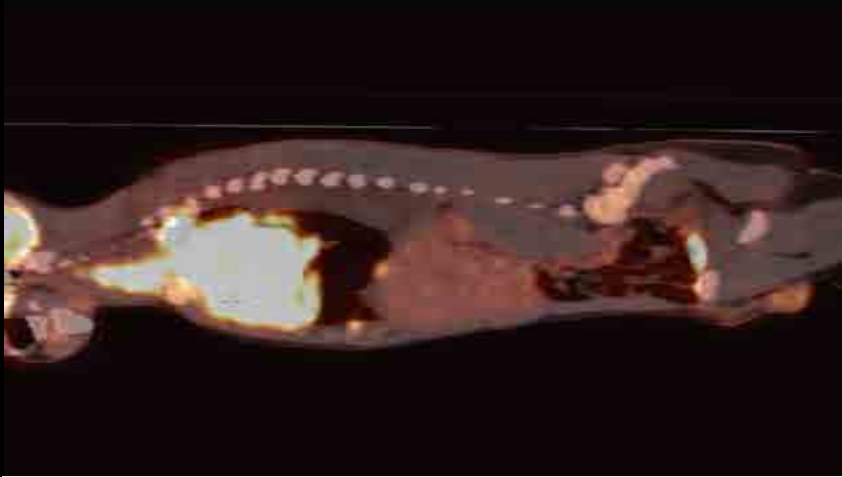
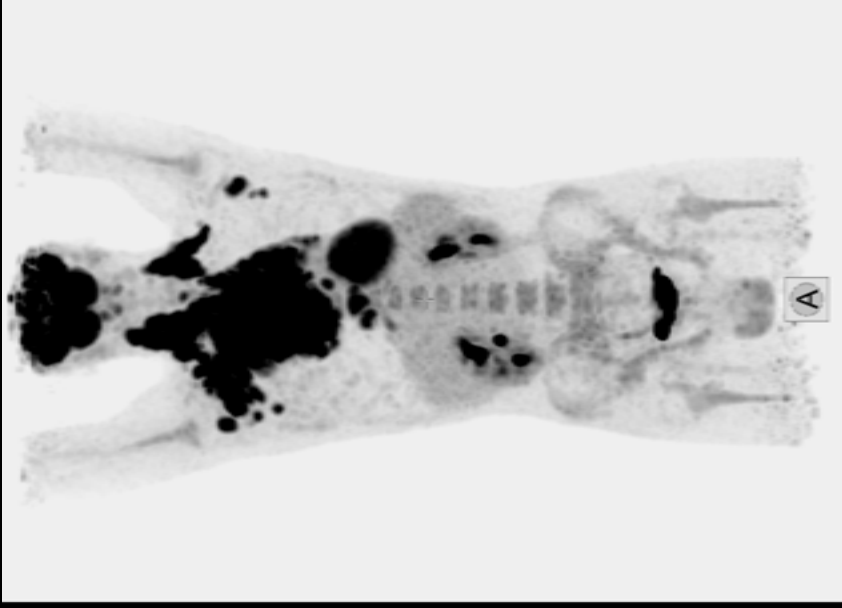
Impression: NHL with supradiaphragmatic lymphoma manifestations, no bone marrow involvement. No other lymphoma manifestations.

Follow-up

Treatment: ChTx with curative intent.

Consequences of the current PET/CT examination reported here

No change in treatment plan.



Non-Hodgkin's lymphoma

18 y/o M patient with cough and asphyxia. CECT shows mediastinal soft tissue mass with right-sided hydrothorax. Biopsy proved NHL.

FDG-PET/CT requested for initial staging shows bulky FDG avid tumour mass in the mediastinum, supradiaphragmatic LN involvement, as well as hypermetabolic activity in the spleen and bone marrow. No infradiaphragmatic FDG avid LNs.

15.9. CASE NO. LY 9

Study type:	Oncology	Clinical indication:	Lymphoma
Clinical indication for PET/CT:	DLBCL, initial staging		
Keywords:	Lymphoma		
PET/CT system:	GE Discovery VCT	Tracer:	FDG
Uptake:	58 min	Dose:	335 MBq
Range:	WB	Blood glucose:	6.5 mmol/L
No. beds:	7	Min/bed:	1
Tube loading:	140 mAs	Tube voltage:	80 kVp

Short clinical history

A 21 year old male patient with DLBCL. Patient was primarily referred for MRI based on thoracic spine pain. A tumour mass in Th1 was detected. FDG–PET/CT for initial staging.

PET/CT findings

FDG–PET/CT requested for initial staging shows multiple, FDG avid bone lesions of the thoracic spine, upper extremities as well as in the ribs. Partial destruction of Th1 and Th2 is detected, FDG avid soft tissue tumour mass invading the spinal canal.

Follow-up biopsy: DLBCL. Treated with ChTx.

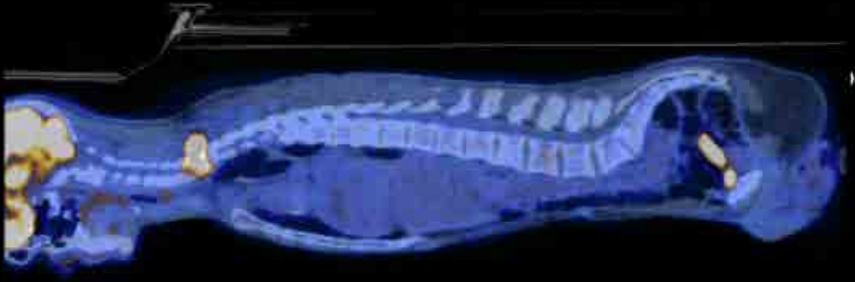
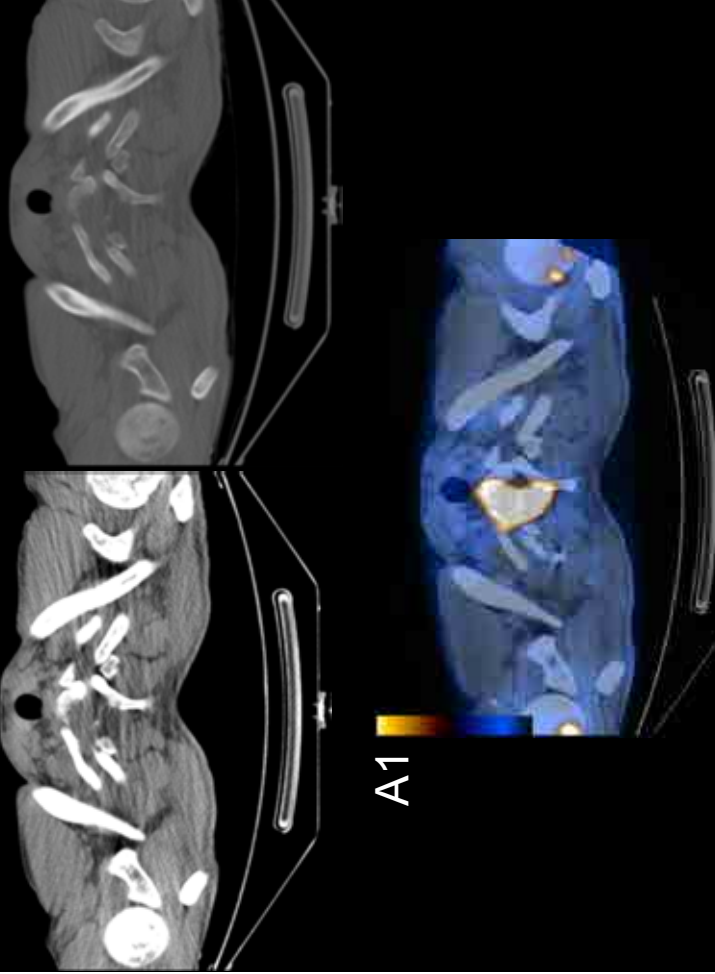
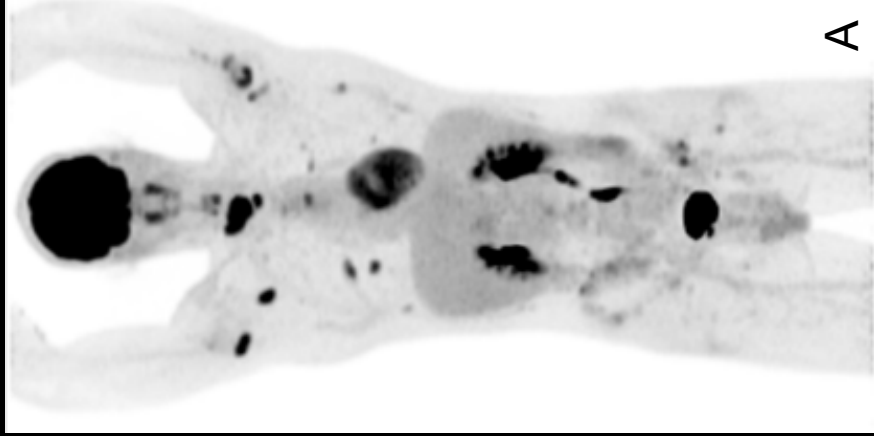
Impression: DLBCL with primarily osseous lymphoma manifestations invading the spinal canal.

Follow-up

Treatment: ChTx with curative intent.

Consequences of the current PET/CT examination reported here

Upstage of disease and change in treatment plan (additional intrathecal ChTx).



Diffuse large B-cell lymphoma

21 y/o M patient with primary diagnosis of DLBCL.

FDG-PET/CT (A) requested for initial staging shows multiple osseous lesions in the thoracic spine, upper extremities as well as in the ribs. Lymphoma manifestations are seen also in the left lower extremity and in the pelvis. Partial destruction of Th1 and Th2 (A1) is detected as well as large parts of lymphoma manifestation invading the spinal canal.

15.10. CASE NO. LY 10

Study type:	Oncology	Clinical indication:	Lymphoma
Clinical indication for PET/CT:	DLBCL, restaging		
Keywords:	Lymphoma Therapy response Thymous rebound		
PET/CT system:	GE Discovery 690 TF	Tracer:	FDG
Uptake:	87 min	Dose:	307 MBq
Range:	WB	Blood glucose:	6.0 mmol/L
No. beds:	7	Min/bed:	2
Tube loading:	140 mAs	Tube voltage:	80 kVp

Short clinical history

A 21 year old male patient with DLBCL. Mainly osseous lymphoma manifestation undergoing general ChTx and intrathecal ChTx based on spinal canal involvement. FDG–PET/CT was requested for therapy monitoring and post-therapy follow-up.

PET/CT findings

FDG–PET/CT requested for therapy monitoring during ChTx showed no increased FDG uptake of the thymus.

FDG–PET/CT requested for post-therapy follow-up showed slightly increased FDG uptake of the thymus and a slightly increased density on the CT as well. Clinically the patient is well, no signs of recurrence.

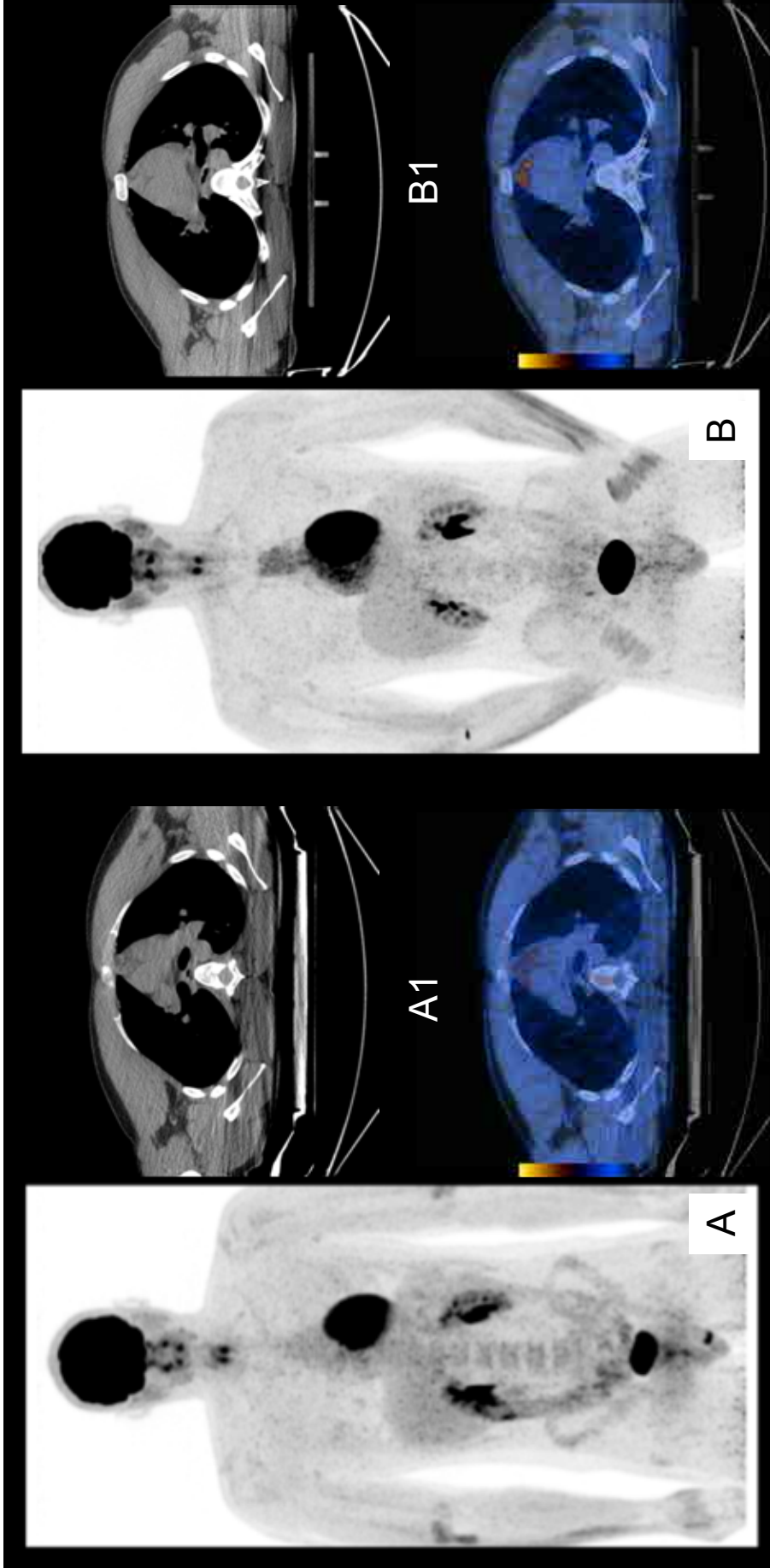
Impression: Typical aspect of a thymus rebound after ChTx.

Follow-up

Observation.

Consequences of the current PET/CT examination reported here

No change in treatment plan.



Diffuse large B-cell lymphoma

21 y/o man diagnosed with DLBCL. S/p initiation of ChTx.

(A) FDG–PET/CT requested for therapy monitoring shows CMR.

(B) FDG–PET/CT requested for restaging shows mildly increased FDG uptake in the thymus (B1 vs. A1), corresponding to a slightly increased density on CT, indicative of thymus rebound.

15.11. CASE NO. LY 11

Study type:	Oncology	Clinical indication:	Lymphoma
Clinical indication for PET/CT:	Mantle cell lymphoma, initial staging		
Keywords:	Lymphoma		
PET/CT system:	GE Discovery 690 TF	Tracer:	FDG
Uptake:	84 min	Dose:	307 MBq
Range:	WB	Blood glucose:	5.0 mmol/L
No. beds:	7	Min/bed:	2
Tube loading:	140 mAs	Tube voltage:	80 kVp

Short clinical history

A 61 year old male patient referred to the hospital with severe diarrhoea. Biopsy taken during colonoscopy revealed infiltration of the bowel wall with mantle cell lymphoma (recurrence, primary tumour 5 years ago). FDG–PET/CT was requested for restaging purposes.

PET/CT findings

FDG–PET/CT for restaging showed increased FDG uptake of the descending colon as well as in parts of the small bowel and the proximal ascending colon. The descending colon showed a thickened bowel wall. In addition, diffuse FDG uptake of the spleen. No extra-abdominal lymphoma involvement.

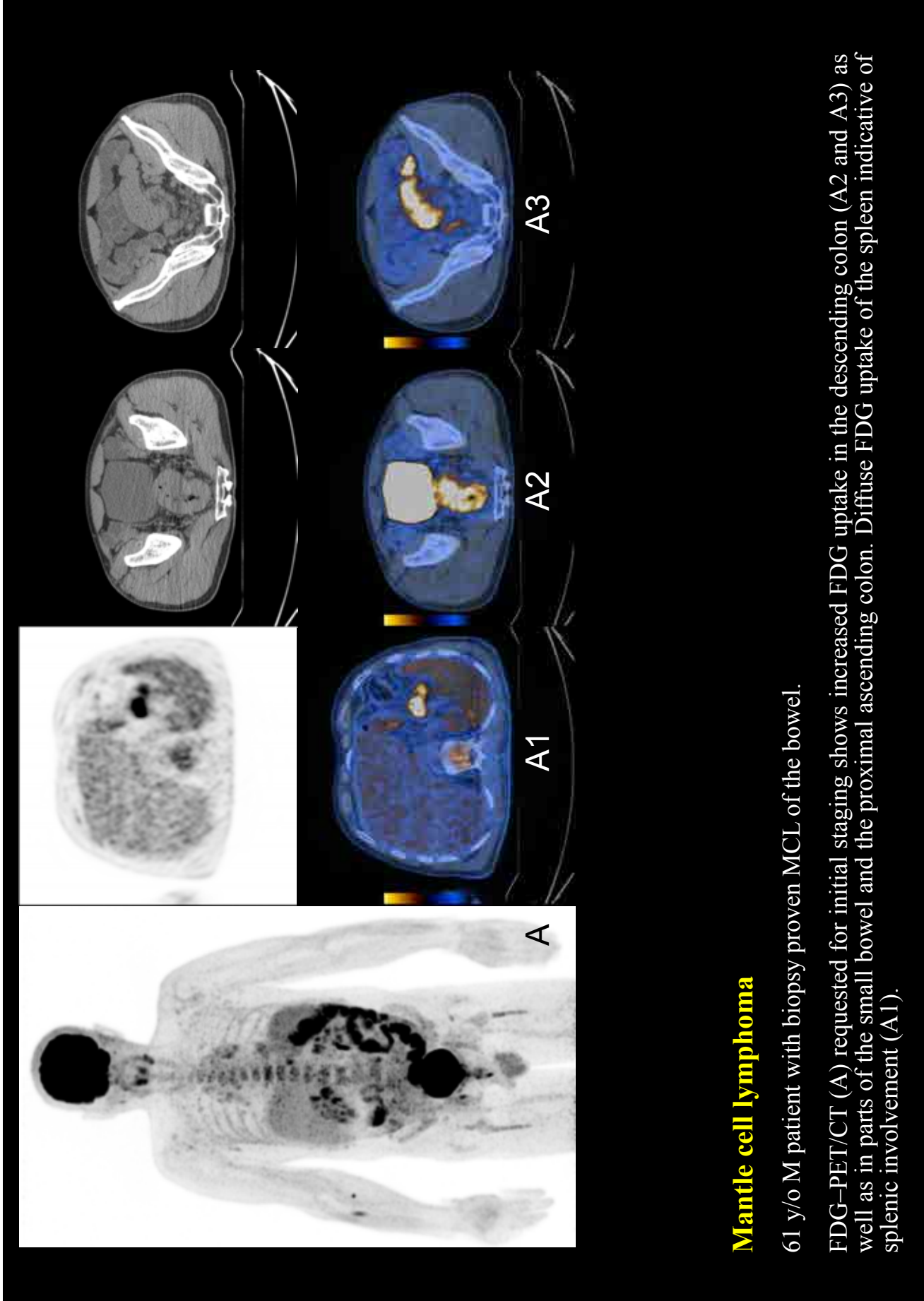
Impression: Mantle cell lymphoma recurrence of the small bowel and bowel, additional spleen involvement.

Follow-up

Treatment: ChTx with curative intent.

Consequences of the current PET/CT examination reported here

Upstage of disease and change in treatment plan (splenic involvement).



Mantle cell lymphoma

61 y/o M patient with biopsy proven MCL of the bowel.

FDG-PET/CT (A) requested for initial staging shows increased FDG uptake in the descending colon (A2 and A3) as well as in parts of the small bowel and the proximal ascending colon. Diffuse FDG uptake of the spleen indicative of splenic involvement (A1).

16. MELANOMA

16.1. CASE NO. ME 1

Study type:	Oncology	Clinical indication:	Melanoma
Clinical indication for PET/CT:	Malignant melanoma		
Keywords:	Malignant melanoma Osseous metastases		
PET/CT system:	GE Discovery VCT	Tracer:	FDG
Uptake:	87 min	Dose:	320 MBq
Range:	WB	Blood glucose:	4.3 mmol/L
No. beds:	7	Min/bed:	2
Tube loading:	140 mAs	Tube voltage:	80 kVp

Short clinical history

A 50 year old female patient with complete resection of a malignant cutaneous melanoma of the right shoulder. Primary diagnosis was 5 years ago. AJCC stage IV, Breslow 6 mm, Clark Level III-IV. Follow-up examinations since primary diagnosis were negative. Currently, left ankle pain. MRI of the left ankle was performed indicating metastases. FDG-PET/CT scan was requested for restaging.

PET/CT findings

FDG-PET/CT for restaging shows a lobulated, sclerotic lesion of the distal left tibia with high FDG uptake.

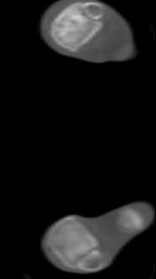

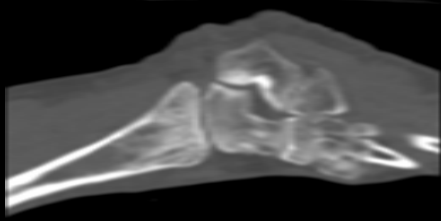
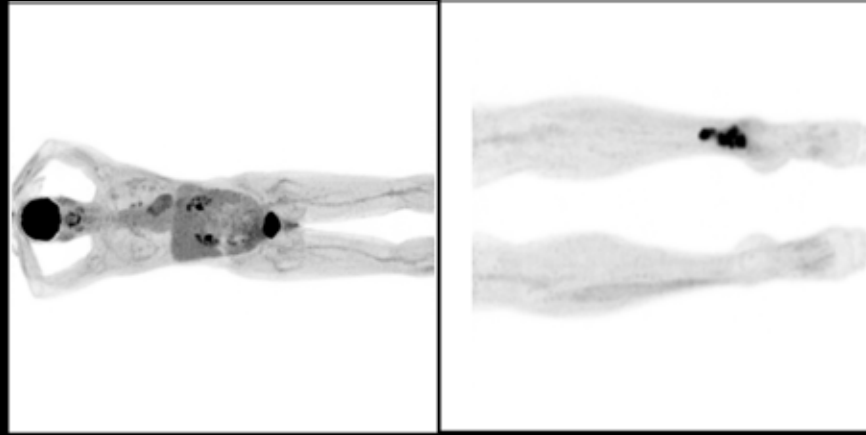
Impression: Differential diagnosis includes malignant primary bone lesions and melanoma metastases. Biopsy proved metastases of a malignant melanoma.

Follow-up

Treatment: RTx with curative intent.

Consequences of the current PET/CT examination reported here

No change in treatment plan.



Malignant melanoma

50 y/o F patient with resected cutaneous melanoma of the left shoulder diagnosed 5 years ago.

FDG-PET/CT requested for restaging shows a lobulated, sclerotic lesion of the distal left tibia with high FDG uptake.

16.2. CASE NO. ME 2

Study type:	Oncology	Clinical indication:	Melanoma
Clinical indication for PET/CT:	Malignant melanoma		
Keywords:	Malignant melanoma Therapy response LN metastases		
PET/CT system:	Philips Gemini TF 64	Tracer:	FDG
Uptake:	87 min	Dose:	370 MBq
Range:	WB	Blood glucose:	5.3 mmol/L
No. beds:	7	Min/bed:	1.5
Tube loading:	200 mAs	Tube voltage:	120 kVp

Short clinical history

A 47 year old male patient with malignant melanoma diagnosed 3 years ago (right leg, Breslow 3.3 mm, Clark VI + sentinel LN metastases). Chest X ray, abdomen and inguinal ultrasound at primary staging were negative. FDG–PET/CT scan was requested for follow-up and therapy monitoring.

PET/CT findings

FDG–PET/CT requested for restaging showed FDG uptake in two right inguinal LNs.

Treatment with LAD and ChTx.

FDG–PET/CT requested for therapy follow-up showed new right inguinal and retroperitoneal LNs.

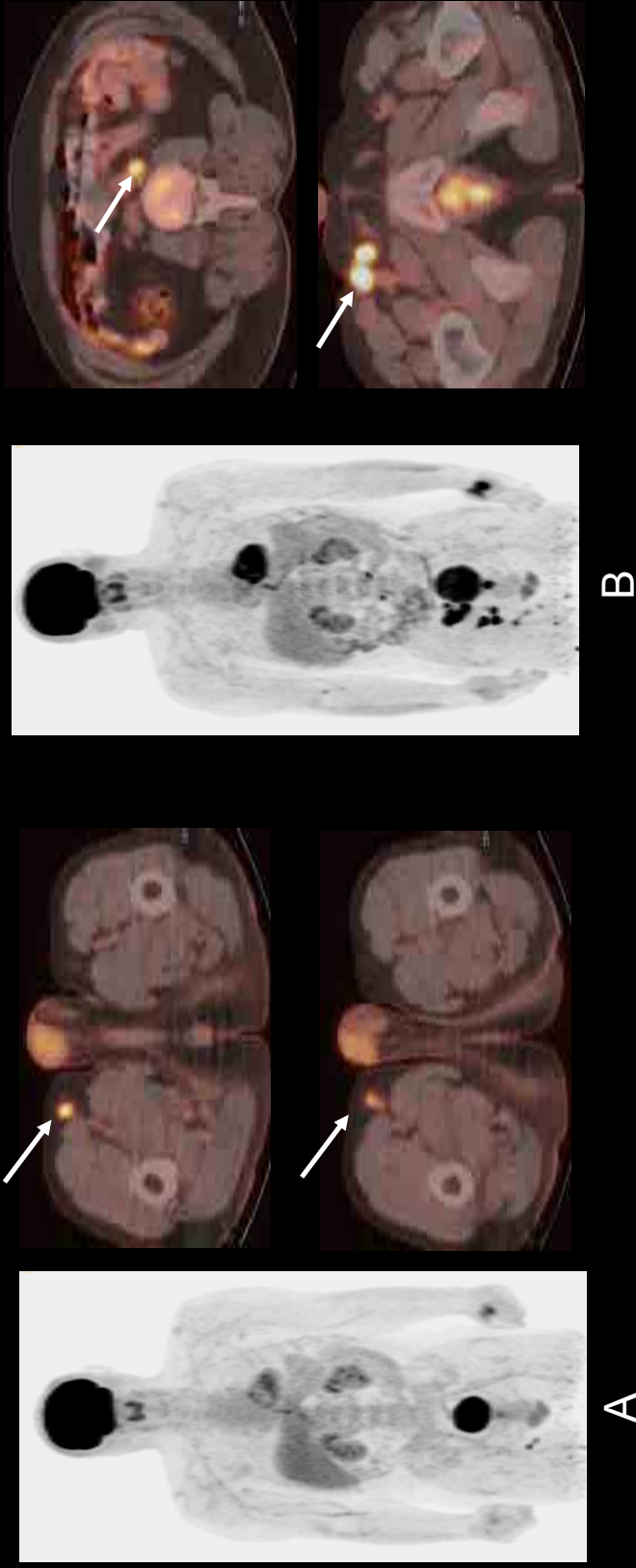
Impression: Right-sided inguinal LN metastases and progressive disease under therapy.

Follow-up

Treatment: ChTx with palliative intent.

Consequences of the current PET/CT examination reported here

Upstage of disease and change in treatment plan.



Malignant melanoma

47 y/o M patient with malignant melanoma s/p surgery (right upper leg, melanoma medullare, Breslow 3.3 mm, Clark VI + sentinel LN metastasis).

(A) FDG-PET/CT requested for restaging (+6 mo) shows focal FDG uptake in two right LNs. Treated with lymphadenectomy and ChTx.

(B) FDG-PET/CT requested for therapy follow-up (+11 mo) shows new right inguinal and abdominal LN metastasis indicative of progressive disease.

16.3. CASE NO. ME 3

Study type:	Oncology	Clinical indication:	Melanoma
Clinical indication for PET/CT:	Malignant melanoma		
Keywords:	Melanoma LN metastases Adrenal gland metastases		
PET/CT system:	Philips Gemini TF 64	Tracer:	FDG
Uptake:	77 min	Dose:	405 MBq
Range:	WB	Blood glucose:	5.8 mmol/L
No. beds:	12	Min/bed:	1.5
Tube loading:	150 mAs	Tube voltage:	120 kVp

Short clinical history

A 65 year old female patient with enlarged and palpable left inguinal LNs. Subsequent biopsy confirmed melanoma metastases. No primary tumour detected. Staging CECT showed pulmonary and hepatic lesions suspicious for metastases. FDG–PET/CT requested for completion of initial staging.

PET/CT findings

FDG–PET/CT scan requested for completion of initial staging showed FDG avid left inguinal LNs and an FDG avid mass in the right adrenal gland. No FDG avid pulmonary or hepatic lesions were detected.

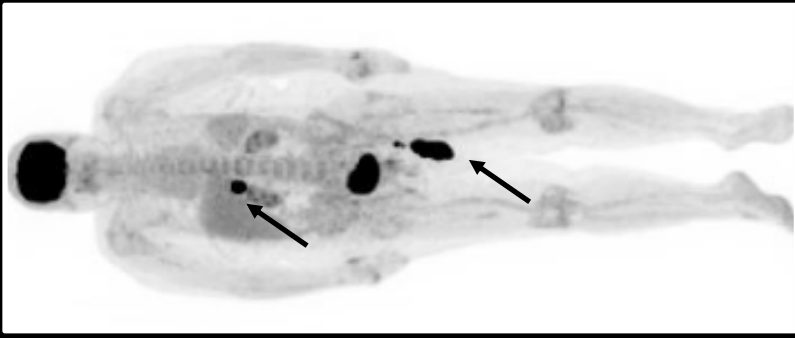Impression: Left inguinal LN and right adrenal gland metastases. No other FDG avid metastases. Pulmonary lesion as a differential diagnosis is benign or can be a secondary lung tumour. Hepatic lesions could be hemangiomas or cysts.

Follow-up

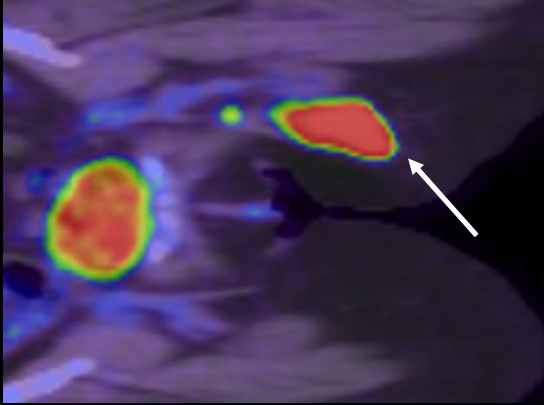
Treatment: ChTx with palliative intent.

Consequences of the current PET/CT examination reported here

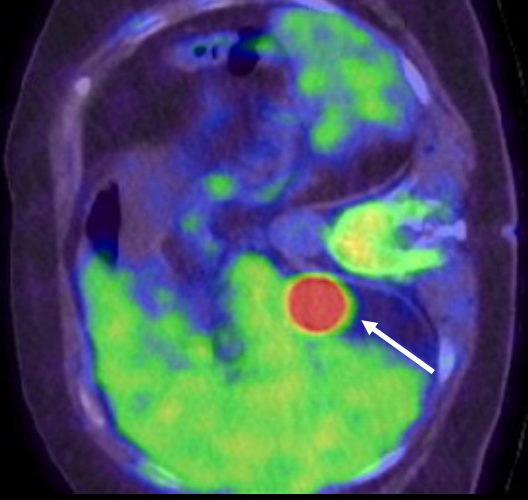
No change in treatment plan.



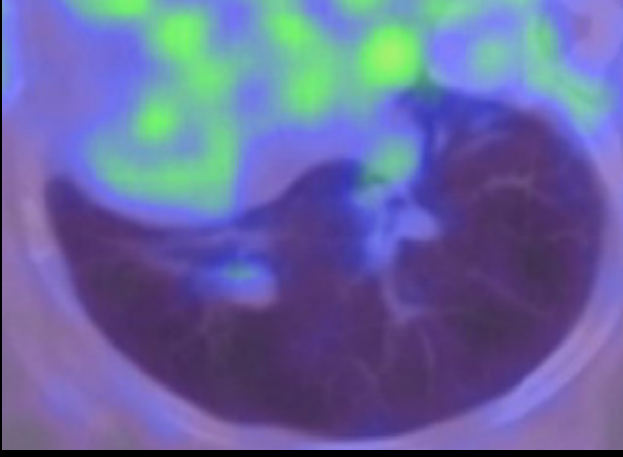
A



A1



A2



A3

Malignant melanoma

65 y/o F patient with left inguinal enlarged LN metastasis from melanoma (biopsy confirmed). CECT suspicious for additional pulmonary and hepatic metastases.

FDG-PET/CT for initial staging (A) shows left inguinal metastatic LN (A1) and right adrenal gland metastasis (A2). No evidence of FDG avid pulmonary or hepatic metastases (A3).

16.4. CASE NO. ME 4

Study type:	Oncology	Clinical indication:	Melanoma
Clinical indication for PET/CT:	Malignant melanoma		
Keywords:	Melanoma Cutaneous metastases Mediastinal metastases Muscle metastases		
PET/CT system:	Philips Gemini TF 64	Tracer:	FDG
Uptake:	58 min	Dose:	405 MBq
Range:	WB	Blood glucose:	4.1 mmol/L
No. beds:	13	Min/bed:	1.5
Tube loading:	120 mAs	Tube voltage:	150 kVp

Short clinical history

A 51 year old female patient with malignant melanoma in the lumbar region and inguinal LN metastases. Treated with ChTxRT. Two years later resection of a solitary pulmonary metastasis. Currently, left inguinal palpable mass. FDG–PET/CT scan was requested for restaging.

PET/CT findings

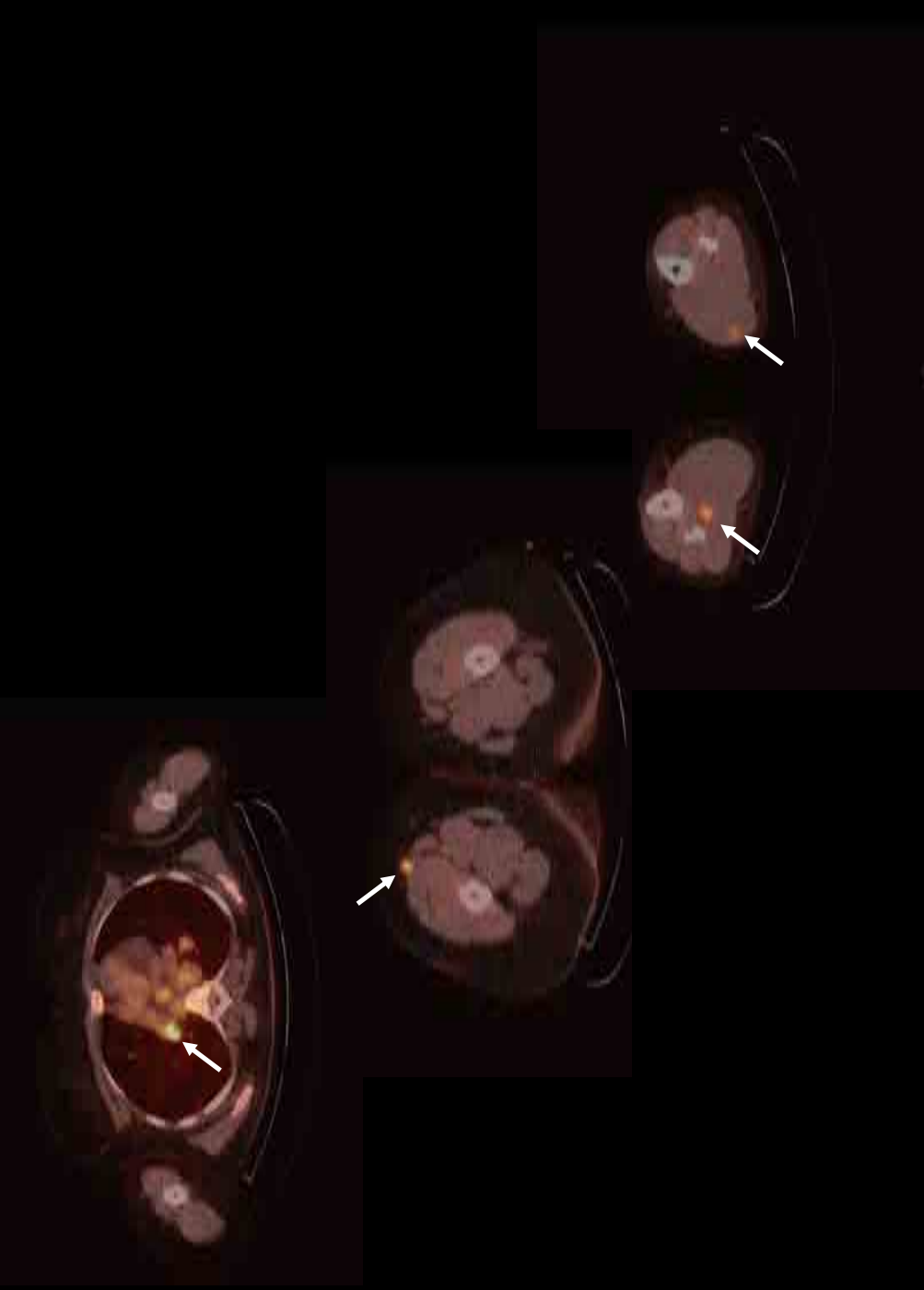
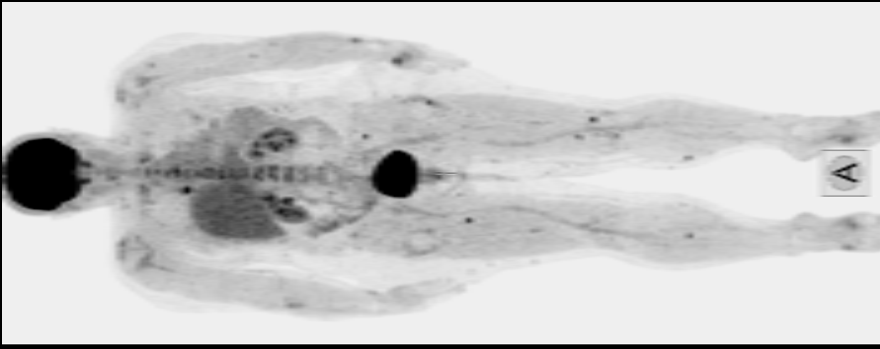
FDG–PET/CT for restaging shows multiple cutaneous, subcutaneous and soft tissue lesions with FDG activity. Enlarged hilar and mediastinal LNs with increased FDG uptake,

Follow-up

Treatment: ChTxRT with palliative intent.

Consequences of the current PET/CT examination reported here

Upstage of disease and change in treatment plan.



Malignant melanoma

51 y/o F patient diagnosed with malignant melanoma s/p ChTx and resection of recurrent solitary pulmonary metastasis 2 years later. Presents with palpable mass suspicious of recurrence.

FDG-PET/CT requested for restaging shows multiple cutaneous, subcutaneous and soft tissue foci with high FDG uptake as well as right hilar metastatic LN.

16.5. CASE NO. ME 5

Study type:	Oncology	Clinical indication:	Melanoma
Clinical indication for PET/CT:	Malignant melanoma		
Keywords:	Malignant melanoma Liver metastases Multiple metastases Therapy response		
PET/CT system:	Philips Gemini TF 64	Tracer:	FDG
Uptake:	58 min	Dose:	260 MBq
Range:	WB	Blood glucose:	4.8 mmol/L
No. beds:	9	Min/bed:	1
Tube loading:	100 mAs	Tube voltage:	120 kVp

Short clinical history

A 62 year old female patient with malignant melanoma at the left pre-auricular region with submandibular LN metastases (Clark Level IV) 2 years ago (A). Patient underwent radical neck dissection, total parotidectomy, submandibular gland resection as well as ChTxRT. FDG–PET/CT scan was requested for restaging.

PET/CT findings

FDG–PET/CT requested for restaging shows multiple FDG avid liver lesions (partly centrally necrotic), lung lesions and retroperitoneal/mesenterial lesions.

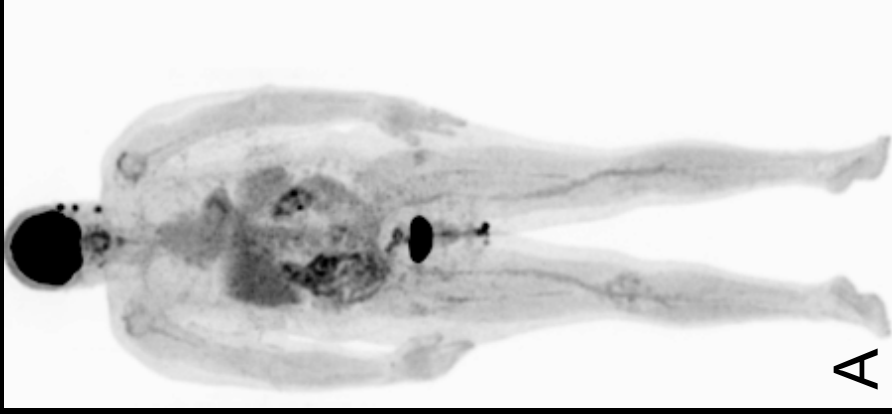Impression: Metastatic disease in the lungs, liver and retroperitoneal/mesenteric LN metastases.

Follow-up

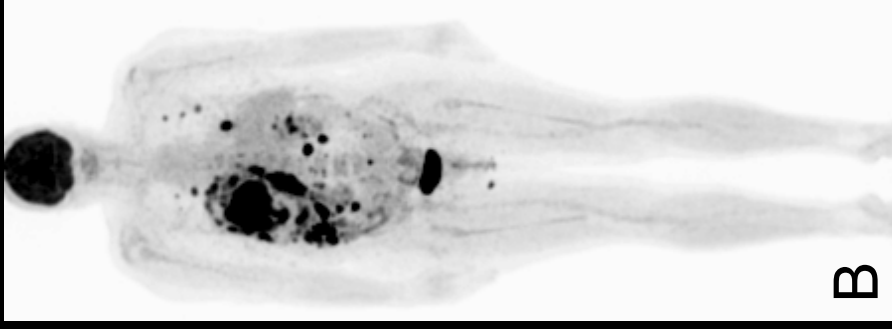
Treatment: ChTx with palliative intent.

Consequences of the current PET/CT examination reported here

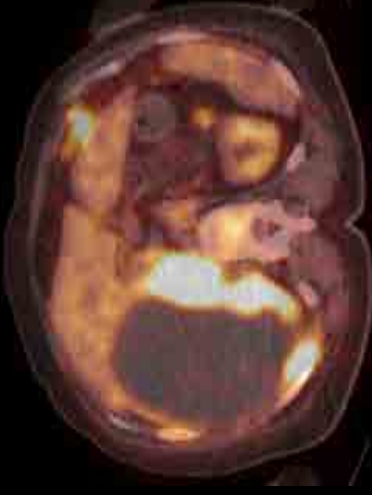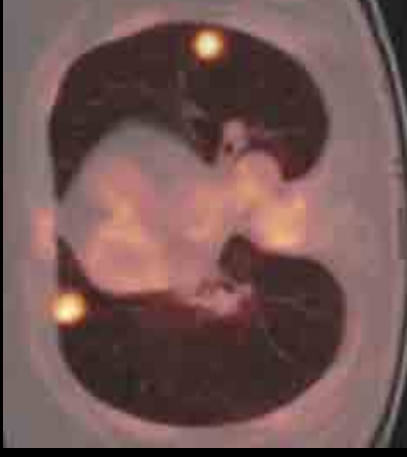
Upstage of disease and change in treatment plan.



A



B



Malignant melanoma

62 y/o F patient with malignant melanoma.

(A) FDG-PET/CT requested for initial staging shows malignant disease in the left submandibular and pre-auricular region. Treated with resection and ChTxRT.

(B) FDG-PET/CT for restaging (+1 y) shows disease progression with metastatic disease to the liver, lungs and mesenteric LNs.

16.6. CASE NO. ME 6

Study type:	Oncology	Clinical indication:	Melanoma
Clinical indication for PET/CT:	Malignant melanoma		
Keywords:	Melanoma Cutaneous metastasis		
PET/CT system:	Philips Gemini TF 64	Tracer:	FDG
Uptake:	62 min	Dose:	336 MBq
Range:	WB	Blood glucose:	4.8 mmol/L
No. beds:	19	Min/bed:	1
Tube loading:	50 mAs	Tube voltage:	120 kVp

Short clinical history

A 54 year old female patient with history of breast cancer and metastatic malignant melanoma (face). S/p surgery of breast cancer and of the melanoma primary tumour several years ago. SPN removed from the left upper lobe of the lung (metastatic). Currently, rising tumour markers and left ankle pain. FDG–PET/CT for restaging.

PET/CT findings

(A) FDG–PET/CT requested for restaging shows inhomogenous sclerotic lesion with high FDG uptake in the left posterior calcaneus. Enlarged and FDG avid LN is detected in the left popliteal region.

Treatment with ChTx.

(B) FDG–PET/CT requested for therapy monitoring shows progressive disease with multiple new subcutaneous lesions.

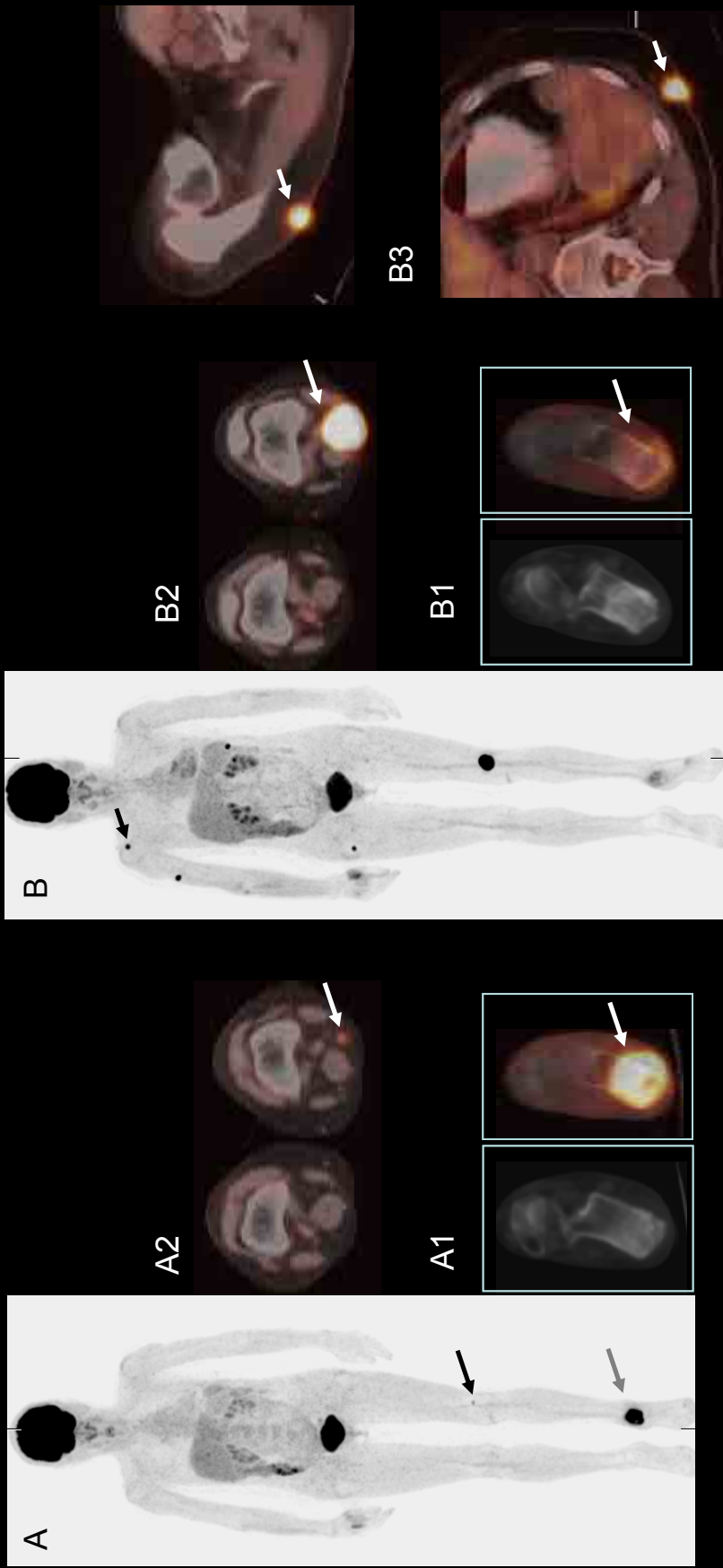
Impression: Osseous metastases in the left calcaneus and popliteal LN metastases. Progression post-therapy with new subcutaneous metastases.

Follow-up

Treatment: ChTx with palliative intent.

Consequences of the current PET/CT examination reported here

Change in treatment plan.



Malignant melanoma

54 y/o F patient with a history of breast cancer and metastatic malignant melanoma. S/p surgery of breast cancer and of the melanoma primary tumour several years ago. S/p SPN resection. FDG-PET/CT requested for restaging.

(A) FDG-PET/CT for restaging shows inhomogenous sclerotic lesion with ring-like FDG accumulation in the left ankle (A1) as well as enlarged LN in the left popliteal region (A2). Treated with ChTx.

(B) FDG-PET/CT for restaging (s/p ChTx, +7 mo) shows progressive disease (B2) with multiple new FDG avid satellite lesions (B3).

17. MISCELLANEOUS: PROSTATE

17.1. CASE NO. MISC PROST 1

Study type:	Oncology	Clinical indication:	Prostate cancer
Clinical indication for PET/CT:	Restaging		
Keywords:	Prostate cancer Local recurrence ¹⁸ F-choline		
PET/CT system:	GE Discovery 690 TOF	Tracer:	¹⁸ F-choline
Uptake:	120 min	Dose:	201 MBq
Range:	WB	Blood glucose:	4.5 mmol/L
No. beds:	7	Min/bed:	2
Tube loading:	120 mAs	Tube voltage:	80 kVp

Short clinical history

A 75 year old male patient with primary prostate cancer diagnosed in 2001, pT3 pN0 cM0 G3, Gleason 3 + 4 = 7. Treated with radical prostatovesiculectomy. Hormonal therapy (Zoladex/Casodex) until June 2011. S/p subcapsular orchiectomy in March 2012. Currently, rising PSA (3.4 ng/mL). Bone scan showed no suspicious osseous lesions.

PET/CT findings

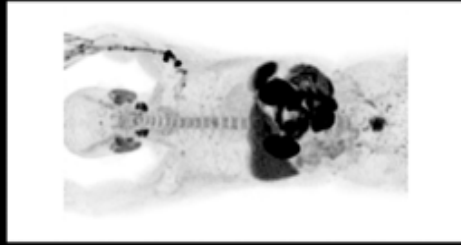
¹⁸F-choline–PET/CT shows a mass posterior to the bladder wall with high choline uptake in the early phase. The bladder is not filled with urine in the early phase. In the late phase, the suspicious lesion is partly masked by the now filled bladder but still detectable morphologically and metabolically. The LN in the left inguinal region shows a decreasing uptake in the late phase — therefore not suspicious for malignancy.

Follow-up

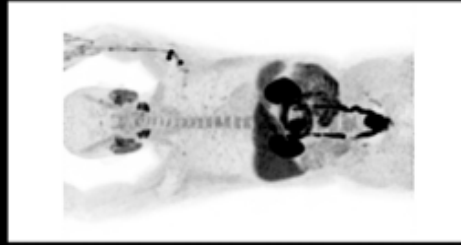
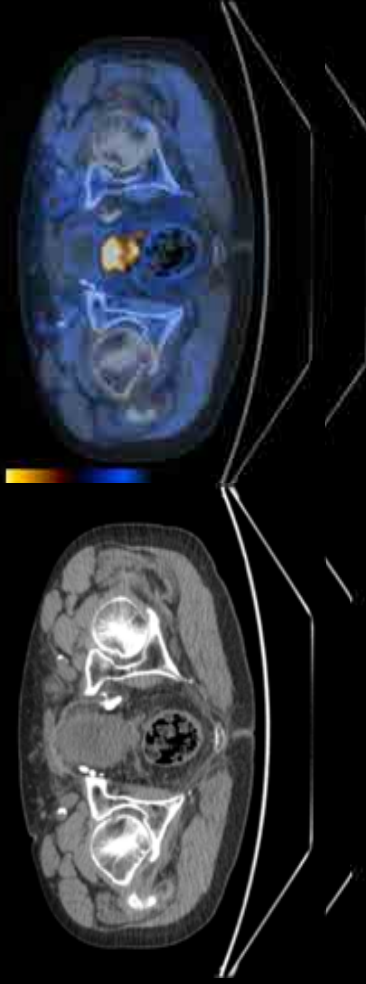
Treatment: Surgery with palliative intent.

Consequences of the current PET/CT examination reported here

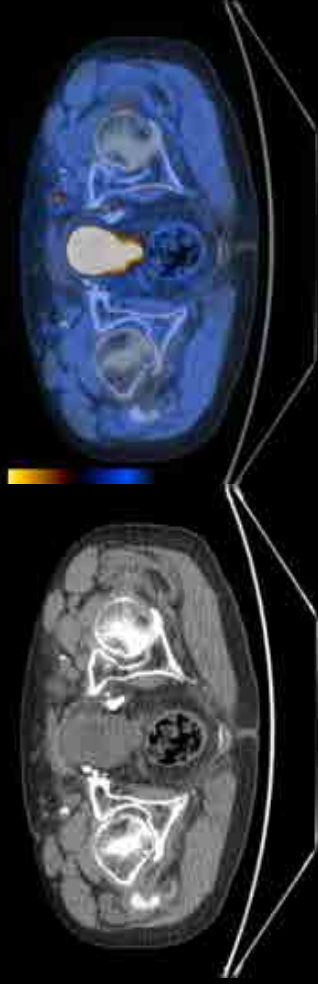
Upstage of disease and change in treatment plan.



A



B



Prostate cancer

75 y/o M patient with suspected prostate cancer recurrence. ^{18}F -choline-PET/CT requested for restaging.

PET/CT shows a mass posterior to the bladder wall with high choline uptake in the early phase (A). In the late phase (B), the suspicious lesion is partly masked by the filled bladder.

17.2. CASE NO. MISC PROST 2

Study type:	Oncology	Clinical indication:	Prostate cancer
Clinical indication for PET/CT:	Restaging		
Keywords:	Prostate cancer Liver metastases Local recurrence ¹⁸ F-choline		
PET/CT system:	GE Discovery 690 TOF	Tracer:	¹⁸ F-choline
Uptake:	120 min	Dose:	222 MBq
Range:	WB	Blood glucose:	4.8 mmol/L
No. beds:	7	Min/bed:	2
Tube loading:	120 mAs	Tube voltage:	80 kVp

Short clinical history

A 69 year old male patient with prostate cancer, with first diagnosis in 2008, pT3 pN1 cM0, Gleason 4 + 4 = 8. Treated with hormonal therapy. S/p resection and radiotherapy of metastases of the corpus spongiosum. Currently, detection of new metastases in pelvic MRI. No other tumour lesions detectable.

PET/CT findings

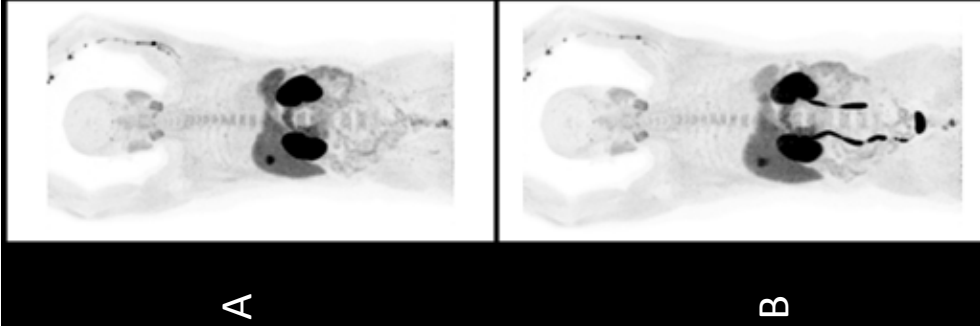
¹⁸F-choline–PET/CT shows a mass in the posterior part of the pars membranacea/corpus spongiosum with high choline uptake. In addition, a hypodense lesion with high choline uptake is visible in the liver (segment VII). Differential diagnosis: prostate cancer metastases to the liver or primary liver tumour (e.g. HCC). HCC may show high choline uptake. However, there are no signs of liver cirrhosis detectable.

Follow-up

Treatment: Surgery and RTx with palliative intent.

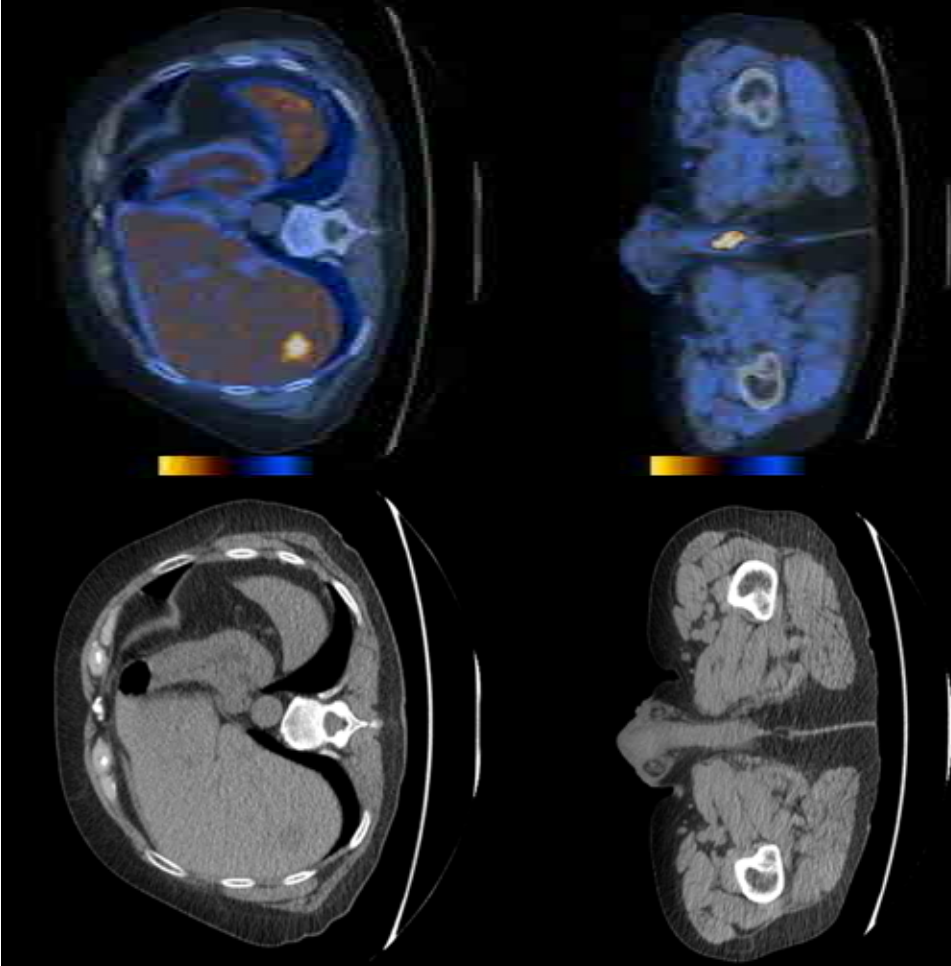
Consequences of the current PET/CT examination reported here

Upstage of disease and change in treatment plan.



A

B



Prostate cancer

69 y/o M patient with suspected prostate cancer recurrence.

^{18}F -choline-PET/CT shows a mass in the posterior part of the pars membranacea/corpus spongiosum with high choline uptake in the early phase (A). In the late phase (B), a hypodense lesion with high choline uptake is visible in the liver (segment VII).

17.3. CASE NO. MISC PROST 3

Study type:	Oncology	Clinical indication:	Prostate cancer
Clinical indication for PET/CT:	Restaging		
Keywords:	Prostate cancer Local recurrence Osseous metastases ¹⁸ F-choline		
PET/CT system:	GE Discovery 690 TOF	Tracer:	¹⁸ F-choline
Uptake:	120 min	Dose:	201 MBq
Range:	WB	Blood glucose:	6.9 mmol/L
No. beds:	7	Min/bed:	2
Tube loading:	120 mAs	Tube voltage:	80 kVp

Short clinical history

A 78 year old male patient with adenocarcinoma (Gleason 4 + 3 = 7) of the right prostate. Secondary resistance to hormonal therapy for 2 years. Bicalutamide additional to hormonal therapy.

PET/CT findings

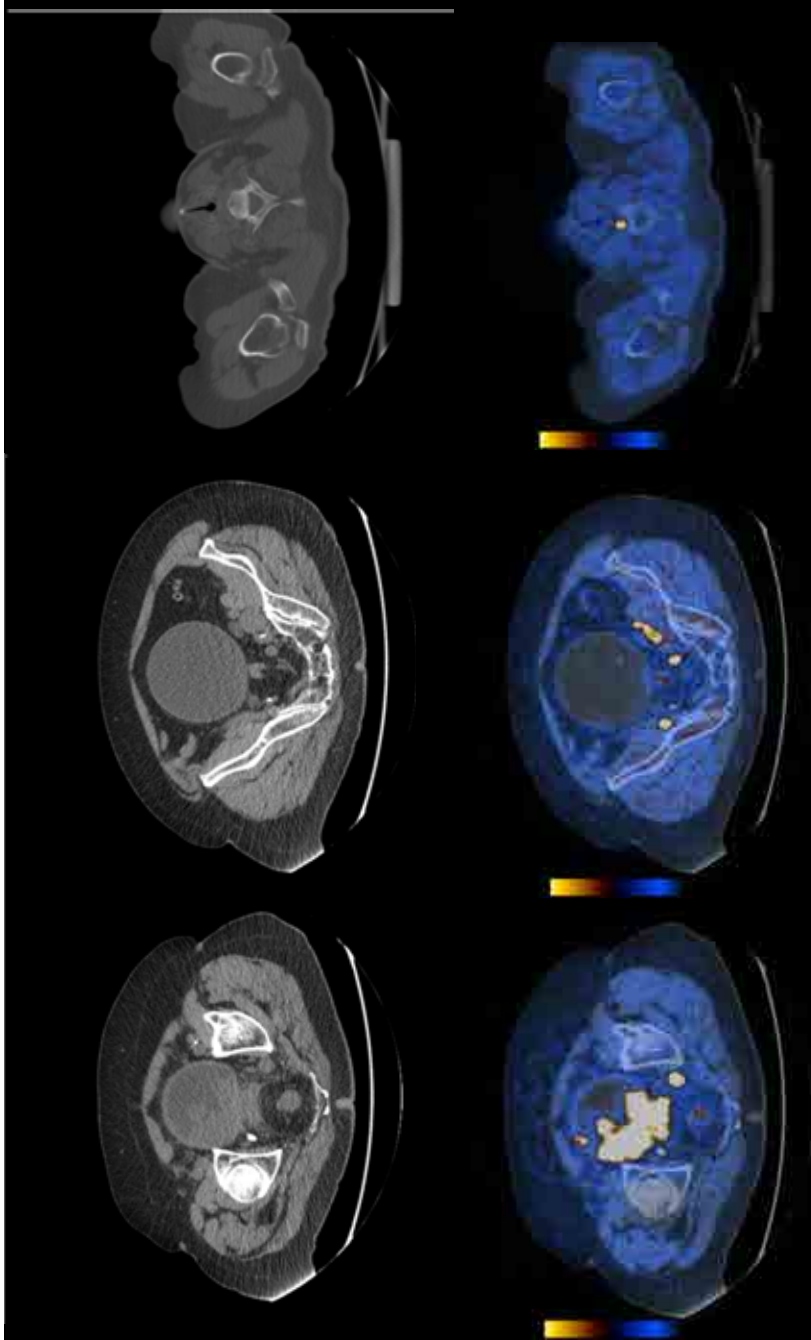
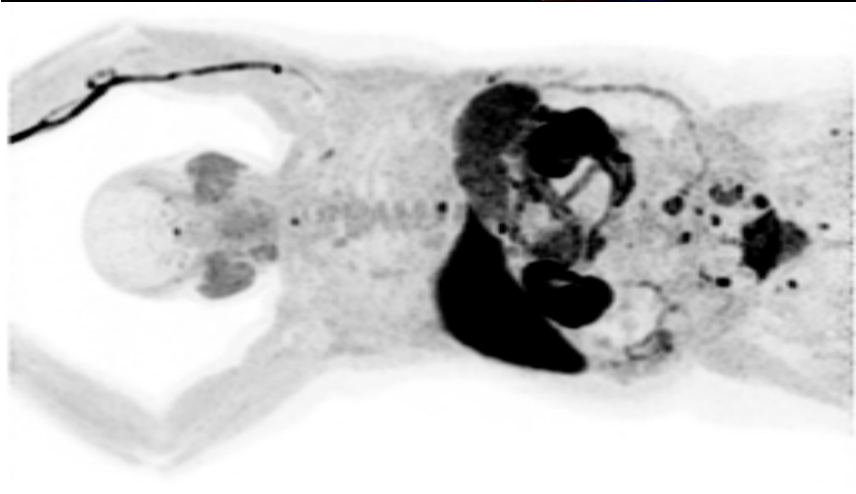
¹⁸F-choline–PET/CT shows the large primary prostate cancer with infiltration of the posterior and right lateral wall of the bladder, LN metastases on the left side and several osseous metastases of the pelvis as well as the spine (e.g. C7).

Follow-up

Treatment: ChTxRT with palliative intent.

Consequences of the current PET/CT examination reported here

Upstage of disease and change in treatment plan.



Prostate cancer

78 y/o M patient with prostate cancer. Adenocarcinoma of the prostate, secondary resistance to hormonal therapy for 2 years. Bicalutamide additional to hormonal therapy. ^{18}F -choline-PET/CT shows the large primary prostate cancer with infiltration of the posterior and right lateral wall of the bladder, LN metastases on the left side and several osseous metastases (e.g. C7/third column).

17.4. CASE NO. MISC PROST 4

Study type:	Oncology	Clinical indication:	Prostate cancer
Clinical indication for PET/CT:	Restaging		
Keywords:	Prostate cancer Local recurrence Osseous metastases ¹⁸ F-choline		
PET/CT system:	GE Discovery 690 TOF	Tracer:	¹⁸ F-choline
Uptake:	120 min	Dose:	189 MBq
Range:	WB	Blood glucose:	6.1 mmol/L
No. beds:	7	Min/bed:	2
Tube loading:	120 mAs	Tube voltage:	80 kVp

Short clinical history

A 69 year old male patient with prostate cancer; first diagnosis was 22 years ago, cT2-3 N0 M0 G3 (Gleason 7), PSA at first diagnosis 5.8 ng/mL. S/p neo-adjuvant LHRH therapy, s/p RTx of the prostate bed, s/p Zoladex/Casodex therapy. PSA rising under therapy. Casodex withdrawal without significant PSA drop. Currently, increasing PSA without therapy.

PET/CT findings

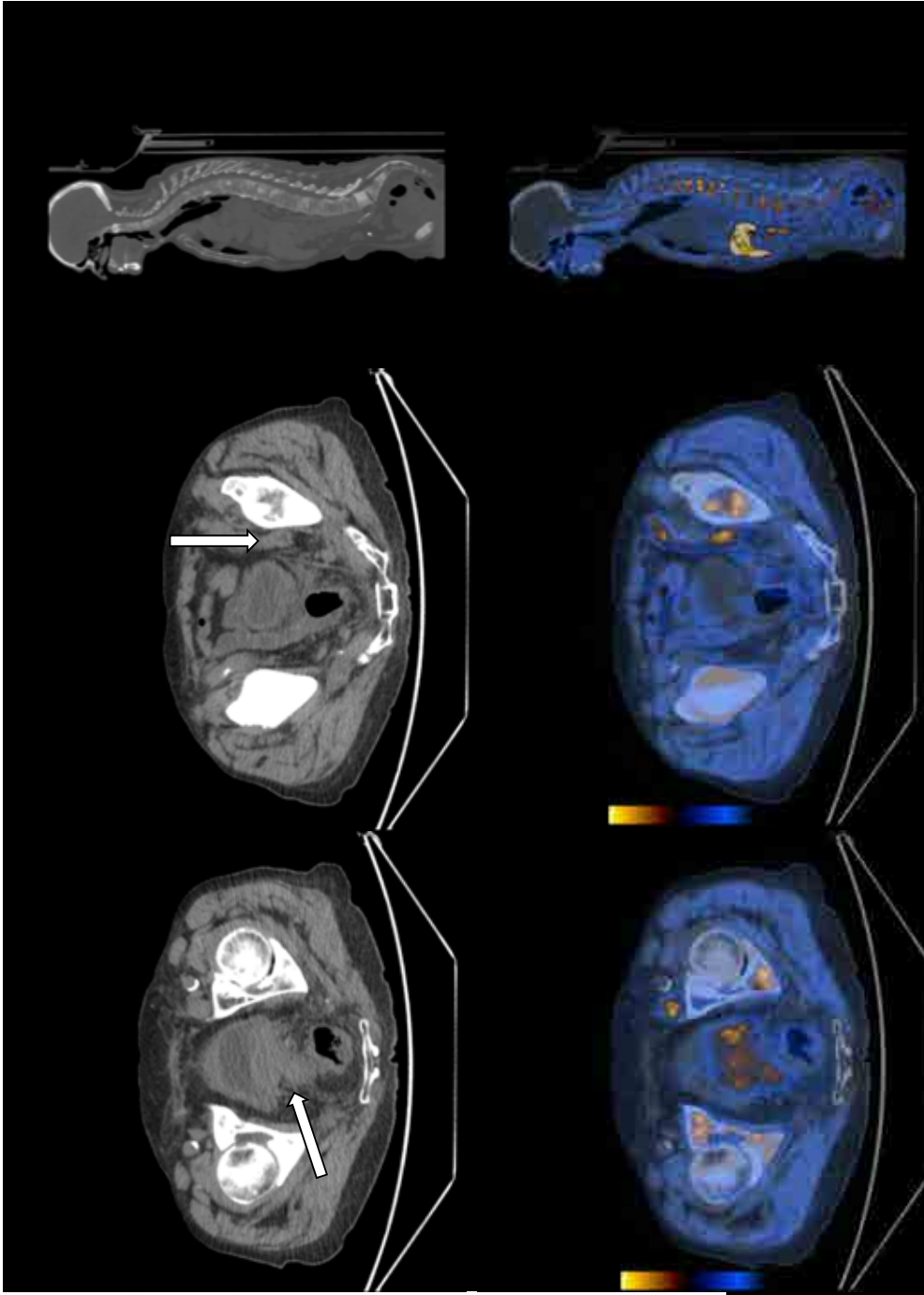

¹⁸F-choline–PET/CT (late phase) shows a large local recurrence (known from previous PET/CT) in the prostate bed with infiltration of the posterior wall of the bladder. In addition, several pathologically enlarged LN metastases at the left side of the small pelvis as well as multiple, sclerotic bone metastases of the pelvis and the spine.

Follow-up

Treatment: ChTx with palliative intent.

Consequences of the current PET/CT examination reported here

Upstage of disease and change in treatment plan.



Prostate cancer

69 y/o M patient with prostate cancer recurrence. First diagnosis of prostate cancer 22 years ago. S/p neo-adjuvant LHRH therapy, s/p RTx, s/p Zoladex/Casodex therapy. PSA rising under therapy. ^{18}F -choline-PET/CT shows known local recurrence (arrow, 2nd column) and multiple bone metastases and additional LN metastases (arrow, 3rd column) and progressive osseous metastases.

18. MISCELLANEOUS: BRAIN

18.1. CASE NO. MISC BRAIN 1

Study type:	Oncology	Clinical indication:	Brain tumour
Clinical indication for PET/CT:	Restaging, suspected recurrence		
Keywords:	Brain tumour Methionine		
PET/CT system:	Philips Gemini TF 64	Tracer:	¹¹ C-MET
Uptake:	10 min	Dose:	282 MBq
Range:	Brain	Blood glucose:	5.0 mmol/L
No. beds:	1	Min/bed:	20
Tube loading:	120 mAs	Tube voltage:	300 kVp

Short clinical history

A 13 year old male patient with acute neurological symptoms. MRI of the brain revealed hydrocephalus caused by a tectal tumour. He was treated with RTx. Two years after the RTx control MRI showed left periventricular mass with high signal intensity but no contrast enhancement. ¹¹C-MET-PET/CT was performed to restage tumour recurrence.

PET/CT findings

¹¹C-MET-PET/CT revealed high density periventricular tissue mass with abnormal methionine uptake and also a focus of increased uptake in the pineal gland.

Impression: Tumour recurrence in the left periventricular region and in the pineal gland.

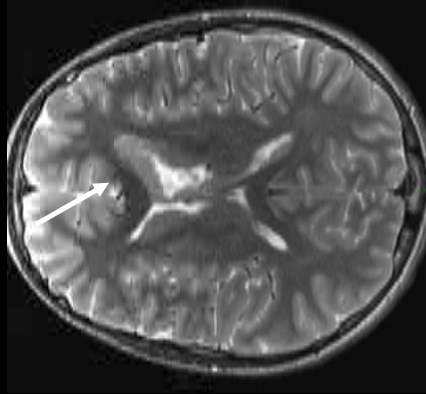
Follow-up

Tissue biopsy was performed proving recurrence.

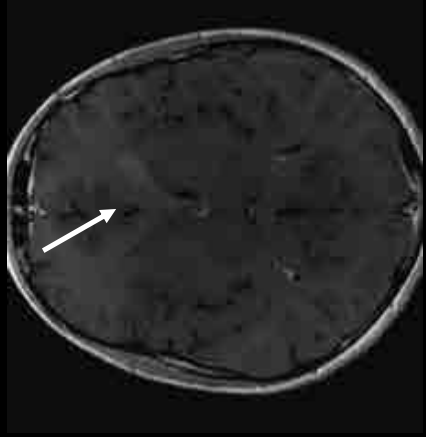
Subsequent treatment: ChTx with curative intent.

Consequences of the current PET/CT examination reported here

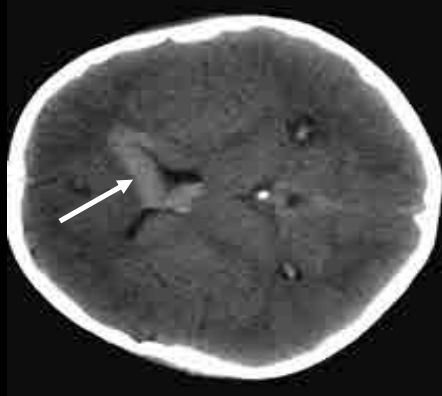Upstage of disease and change in treatment plan.



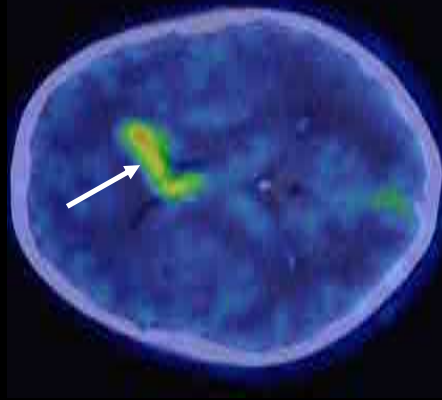
T2w MRI



Gd-MRI



CT



MET-PET/CT

Brain tumour

13 y/o M patient with previous tectal tumour (histology unknown) treated with RTx. Presented with diplopia and headache after 2 years. MRI shows left periventricular abnormal signal intensity without contrast enhancement.

^{11}C -MET-PET/CT requested for restaging shows tumour recurrence in the same region.

Stereotactic biopsy proved germinoma. Patient sent for ChTx.

18.2. CASE NO. MISC BRAIN 2

Study type:	Oncology	Clinical indication:	Brain tumour
Clinical indication for PET/CT:	Restaging, suspected recurrence		
Keywords:	Brain tumour Methionine		
PET/CT system:	Philips Gemini TF 64	Tracer:	¹¹ C-MET
Uptake:	10 min	Dose:	370 MBq
Range:	Brain	Blood glucose:	4.8 mmol/L
No. beds:	1	Min/bed:	20
Tube loading:	120 mAs	Tube voltage:	300 kVp

Short clinical history

A 20 year old female patient with s/p surgery of a right frontal grade II astrocytoma 13 months ago. MR shows hypointense lesion in the surgical bed with no enhancement. Clinically, the patient suffers from psychiatric problems and headache.

PET/CT findings

Focal high methionine uptake in the right parasagittal region and focal high FDG accumulation in the same focus.

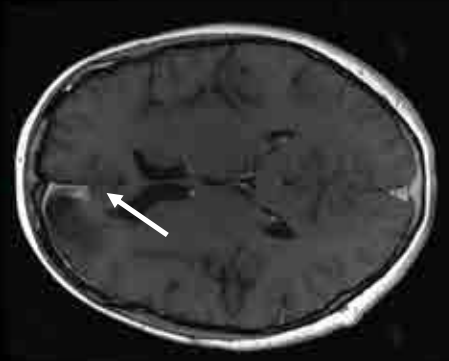Impression: Recurrent tumour, high grade viable tumour tissue in the surgical bed.

Follow-up

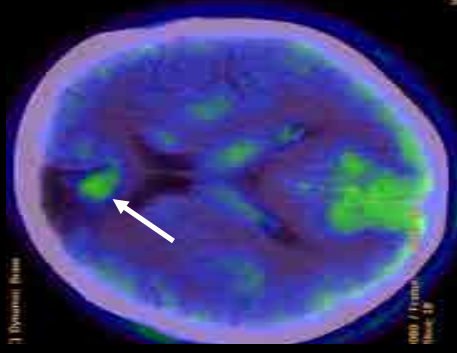
Treatment: Surgery with curative intent.

Consequences of the current PET/CT examination reported here

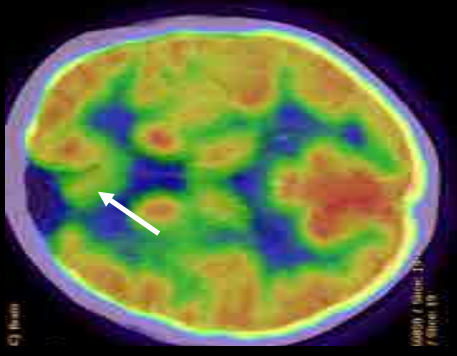
Upstage of disease and change in treatment strategy.



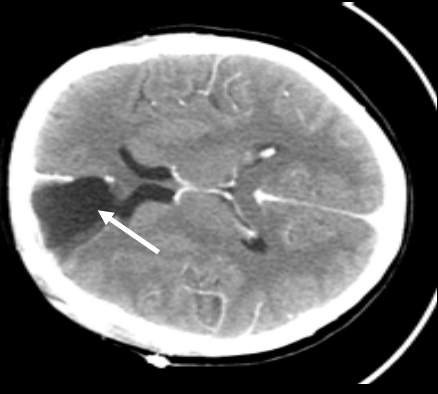Gd-MR



MET-PET/CT



FDG-PET/CT



CECT

Pre-op

Post-op

Astrocytoma

20 y/o F patient s/p resection of right frontal astrocytoma WHO II. Gd-MR: enhancement in the resection cavity. PET/CT requested for staging.

¹¹C-MET-PET/CT shows tumour recurrence in surgical bed. FDG-PET/CT shows high grade viable tumour tissue.

Lesion was removed by the neurosurgeon. Histopathology confirmed astrocytoma grade III.

19. MISCELLANEOUS: NEUROENDOCRINE TUMOUR (DOPA AND DOTA)

19.1. CASE NO. MISC NET 1

Study type:	Oncology	Clinical indication:	NET
Clinical indication for PET/CT:	Initial staging		
Keywords:	NET DOTA-TATE		
PET/CT system:	GE Discovery 690 TOF	Tracer:	⁶⁸ Ga DOTA-TATE
Uptake:	67 min	Dose:	121 MBq
Range:	WB	Blood glucose:	4.5 mmol/L
No. beds:	7	Min/bed:	2
Tube loading:	120 mAs	Tube voltage:	80 kVp

Short clinical history

A 46 year old male patient with increasing liver enzymes and bowel discomfort. The CT and MRI performed at another institution showed multiple liver metastases. Biopsy confirmed an NET. The primary tumour was not detected.

PET/CT findings

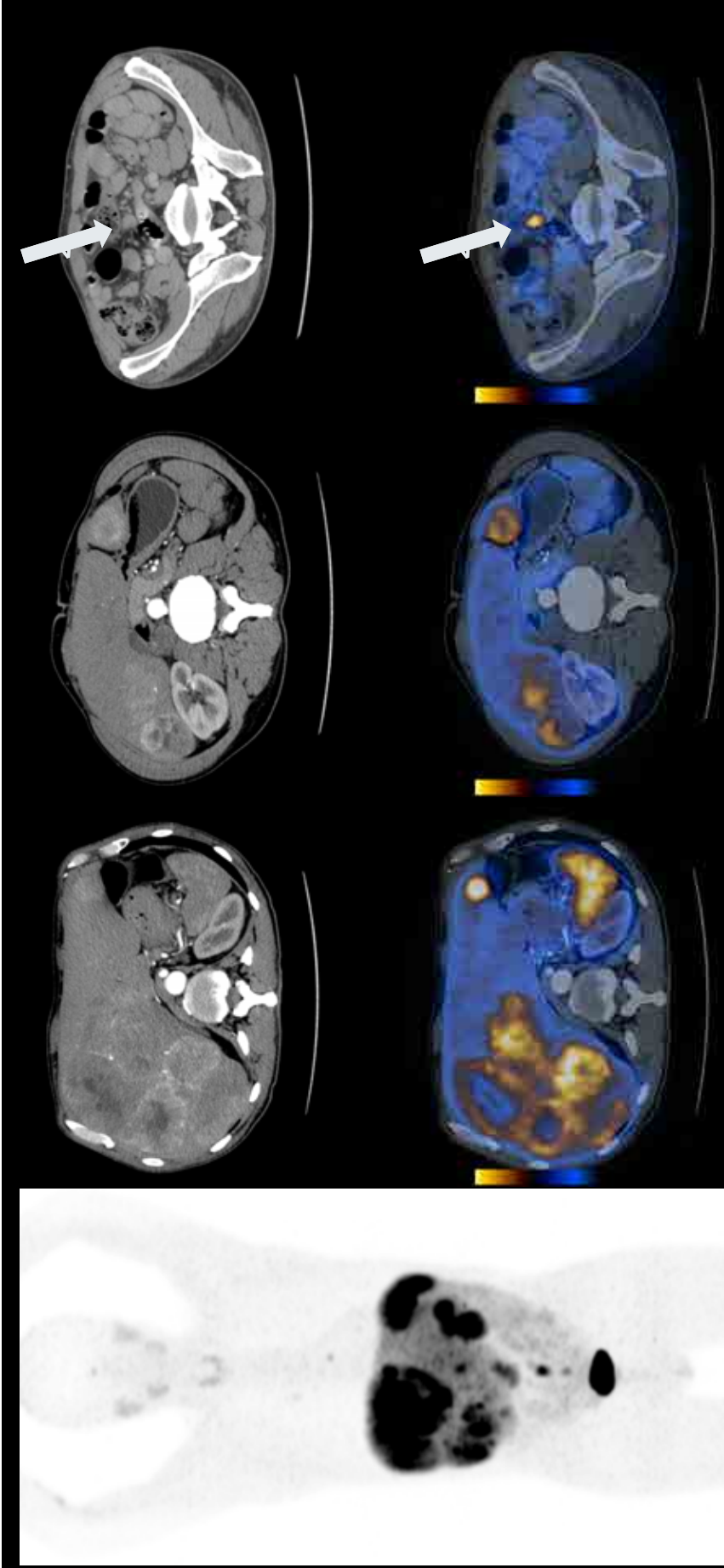
DOTA-TATE–PET/CT with arterial and portal venous contrast media phase shows typical, arterial contrast enhancing, disseminated liver large lesions with SSTR-2 positivity. Furthermore, there was a small, contrast enhancing lesion found in the lower abdomen in the ileum (arrow), again with SSTR positivity. DOTA-TATE–PET/CT, therefore, was able to identify the primary tumour.

Follow-up

Treatment: Surgery and adjuvant ChTx with palliative intent.

Consequences of the current PET/CT examination reported here

Upstage of disease and change in treatment plan.



Neuroendocrine tumour

46 y/o M patient with initial diagnosis of multiple liver metastases of an NET. DOTA-TATE-PET/CT requested for staging shows typical arterial contrast enhancing, disseminated large liver lesions. Furthermore, there was a small, contrast enhancing lesion found in the lower abdomen in the ileum (arrow), suspected of being the primary tumour.

19.2. CASE NO. MISC NET 2

Study type:	Oncology	Clinical indication:	NET
Clinical indication for PET/CT:	Initial staging		
Keywords:	NET DOTA-TATE		
PET/CT system:	GE Discovery 690 TOF	Tracer:	⁶⁸ Ga DOTA-TATE
Uptake:	67 min	Dose:	105 MBq
Range:	WB	Blood glucose:	4.2 mmol/L
No. beds:	7	Min/bed:	2
Tube loading:	120 mAs	Tube voltage:	80 kVp

Short clinical history

A 73 year old female patient underwent endoscopic evaluation due to some abdominal discomfort. A small tumour at the caecum/distal ileum was incidentally detected. The biopsy confirmed an NET.

PET/CT findings

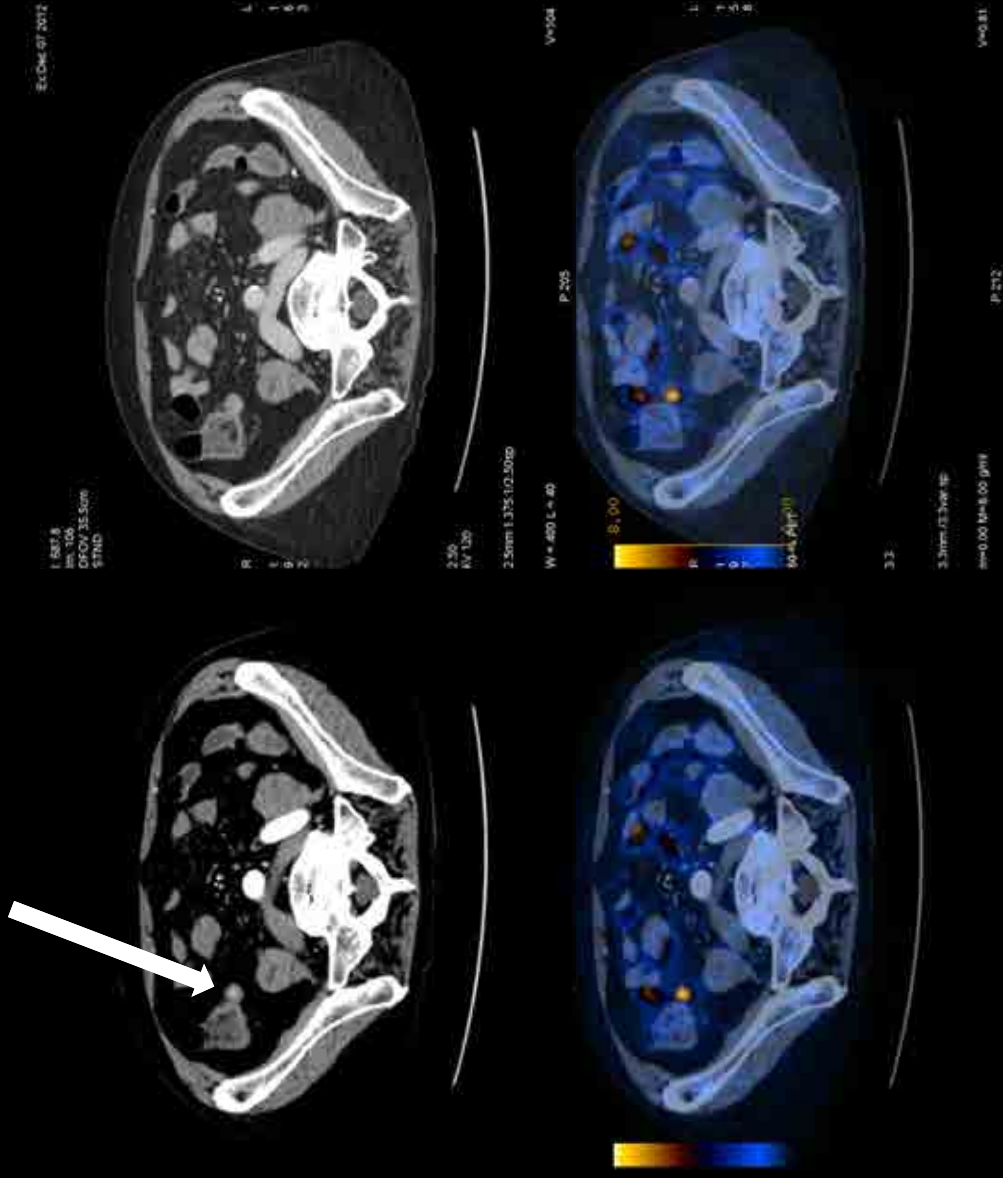
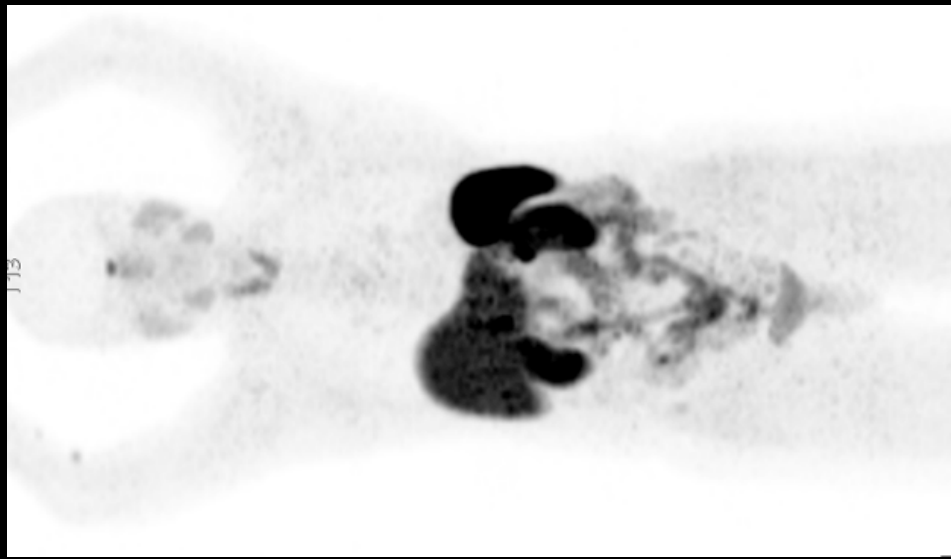
DOTA-TATE–PET/CT with arterial and portal venous contrast media phase shows the primary NET of the caecum detected incidentally during endoscopy. No specific neuroendocrine symptoms. DOTA-TATE–PET/CT shows an arterial enhanced small lesions of the terminal ileum/caecum with SSTR-2 positivity. No other lesions or metastases detected.

Follow-up

Treatment: Surgery with curative intent.

Consequences of the current PET/CT examination reported here

No change in treatment plan.



Neuroendocrine tumour

73 y/o F patient with suspicion of an NET. DOTA-TATE-PET/CT detected the primary tumour of the caecum incidentally seen during endoscopy. No specific clinical symptoms. The lesion shows arterial and portal venous contrast enhancement (arrow) and SSTR-2 positivity. No other lesions/metastases.

20. MISCELLANEOUS: IODINE-124

20.1. CASE NO. MISC I-124 1

Study type:	Oncology	Clinical indication:	Thyroid cancer
Clinical indication for PET/CT:	Dosimetry, staging		
Keywords:	DTC Dosimetry Iodine avidity		
PET/CT system:	Siemens Biograph Duo	Tracer:	¹²⁴ I
Uptake:	240 min	Dose:	21 MBq
Range:	WB	Blood glucose:	4.3 mmol/L
No. beds:	8	Min/bed:	2
Tube loading:	140 mAs	Tube voltage:	80 kVp

Short clinical history

A 77 year old male patient with advanced DTC (pT4 pN1 M1) s/p thyroidectomy.

PET/CT findings

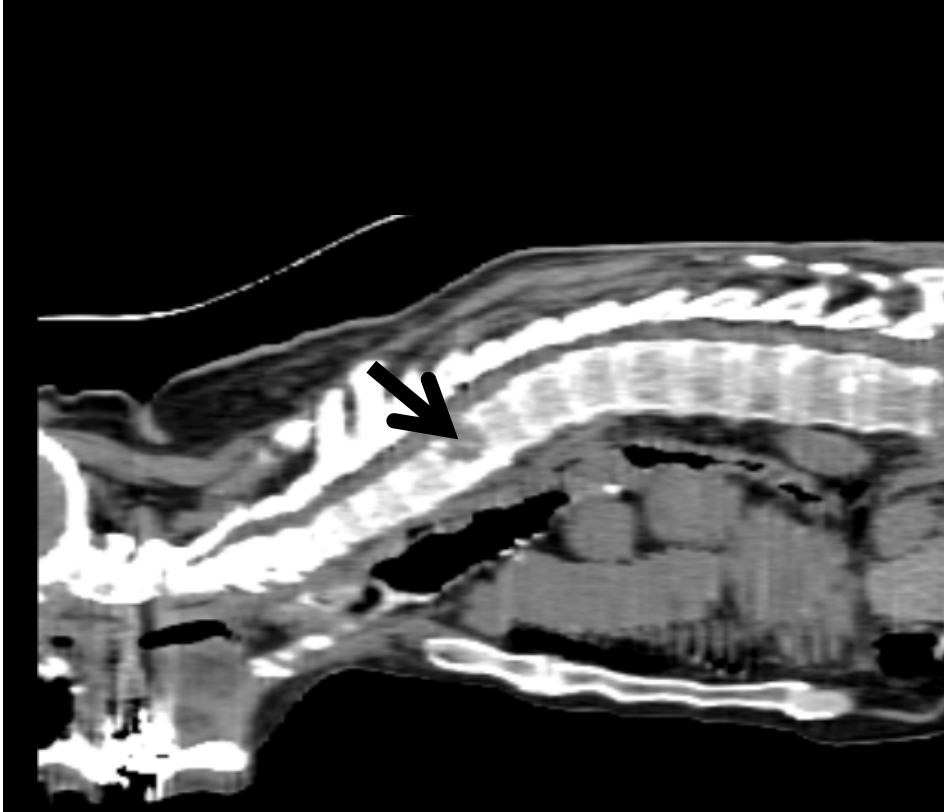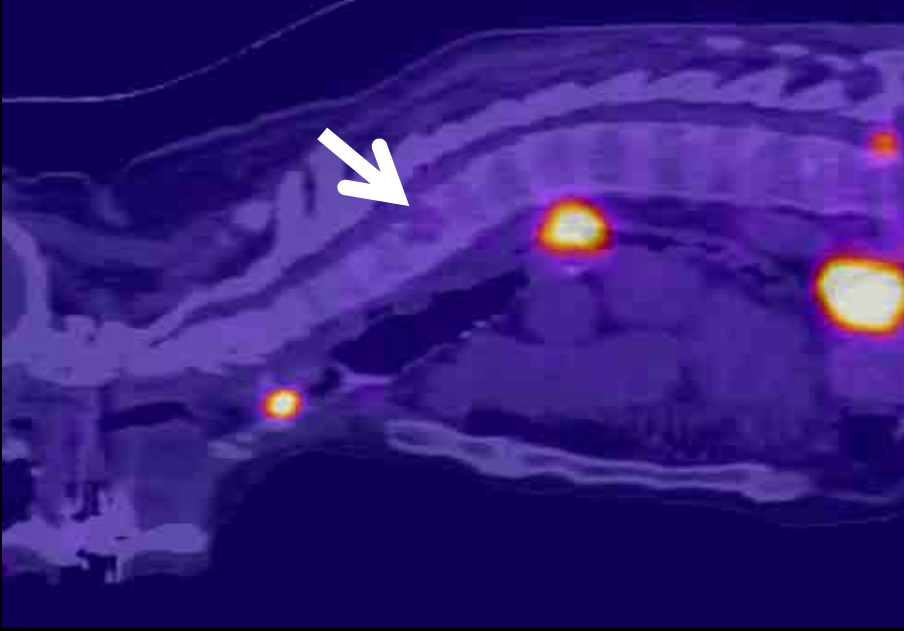
¹²⁴I-PET/CT for staging and dosimetry prior to first ¹³¹I treatment showed advanced DTC with multiple iodine avid metastases. Those metastases were initially planned to be treated with 15 GBq of ¹³¹I. The iodine negative vertebral metastasis needed external RTx.

Follow-up

Treatment: ¹³¹I treatment and RTx with palliative intent.

Consequences of the current PET/CT examination reported here

Change in treatment plan.



Differentiated thyroid cancer

77 y/o M patient with advanced DTC (pT4 pN1 M1) s/p thyroidectomy. ^{124}I -PET/CT requested for staging and dosimetry prior to first ^{131}I treatment.

PET/CT shows advanced DTC with multiple iodine avid metastases (e.g. treatable with ^{131}I) and an iodine negative vertebral metastasis (arrow) at risk for fracture.

20.2. CASE NO. MISC I-124 2

Study type:	Oncology	Clinical indication:	Thyroid cancer
Clinical indication for PET/CT:	Restaging		
Keywords:	Thyroid cancer Iodine avidity		
PET/CT system:	Siemens Biograph Duo	Tracer:	^{124}I
Uptake:	240 min	Dose:	22 MBq
Range:	WB	Blood glucose:	7.1 mmol/L
No. beds:	8	Min/bed:	2
Tube loading:	140 mAs	Tube voltage:	80 kVp

Short clinical history

A 67 year old male patient with advanced DTC (pT3 pN1 M0) s/p thyroidectomy and three ^{131}I treatments with a cumulative dose of 20 GBq ^{131}I .

PET/CT findings

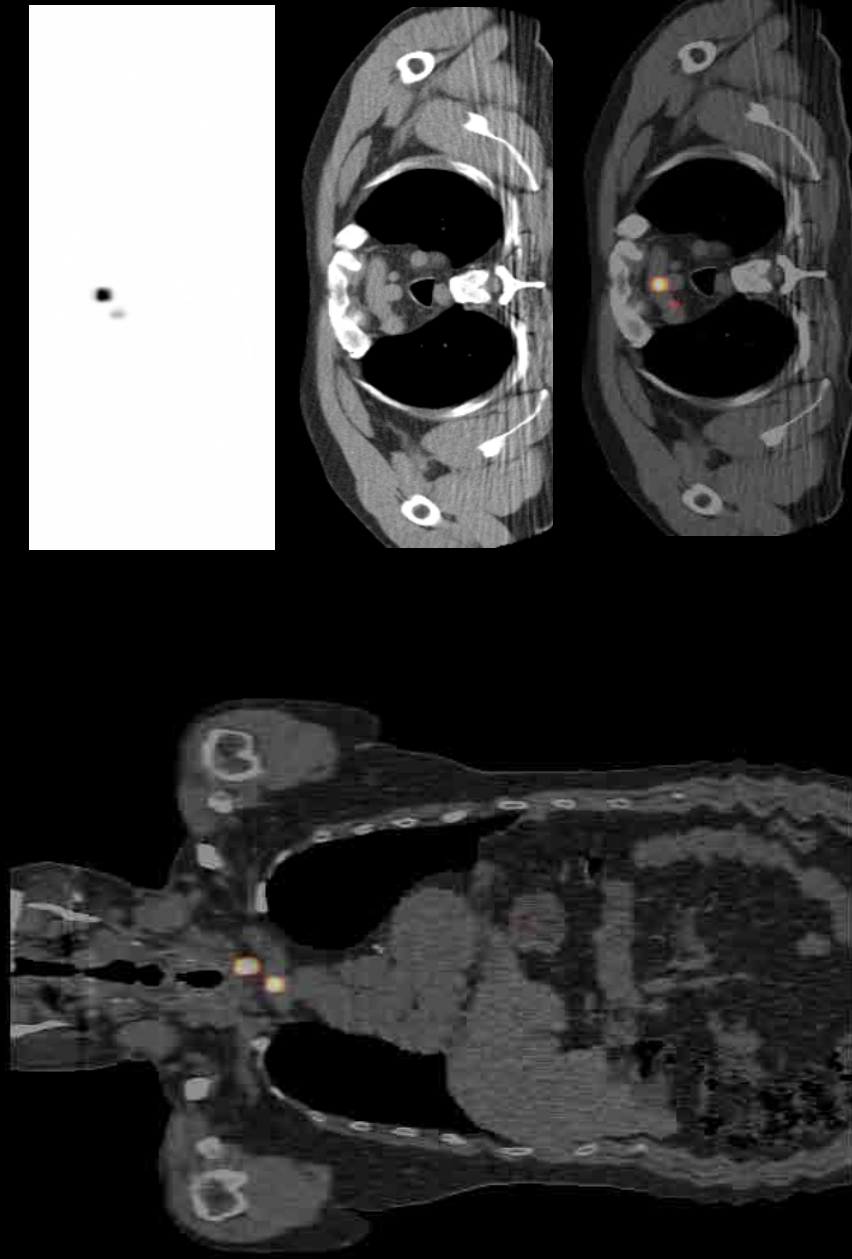
^{124}I -PET/CT after 1 year for restaging in high risk patient showing three mediastinal iodine avid metastases at the aortic arch. Dosimetry failed to prove that an adequate radiation dose could be delivered to the lesion with ^{131}I . Therefore, surgical management was chosen. Histology showed two DTC metastases. Tumour markers decreased significantly post-therapy.

Follow-up

Treatment: Surgery with curative intent.

Consequences of the current PET/CT examination reported here

Change in treatment plan.



Differentiated thyroid cancer

67 y/o M patient with advanced DTC (pT3 pN1 M0) s/p thyroidectomy and three ^{131}I treatments with a cumulative dose of 20 GBq.

^{124}I -PET/CT requested after 1 year for restaging in high risk patient showing three mediastinal iodine avid metastases at the aortic arch.

21. PAEDIATRICS

21.1. CASE NO. PAED 1

Study type:	Oncology	Clinical indication:	Sarcoma
Clinical indication for PET/CT:	Initial staging		
Keywords:	Paediatric oncology Sarcoma		
PET/CT system:	GE Discovery	Tracer:	FDG
Uptake:	71 min	Dose:	325 MBq
Range:	WB	Blood glucose:	5.0 mmol/L
No. beds:	6	Min/bed:	1
Tube loading:	70 mAs	Tube voltage:	100 kVp

Short clinical history

A 14 year old male patient with newly diagnosed Ewing's sarcoma of the sacrum. Pulmonary metastasis known. FDG-PET/CT was requested for initial staging.

PET/CT findings

FDG-PET/CT shows heterogeneous uptake in a partially destructive sacral mass and soft tissue avidity anterior to this mass. In addition, diffuse metastatic disease in the chest with anterior mediastinal mass. Moderate right-sided pleural effusion with low grade FDG avidity.

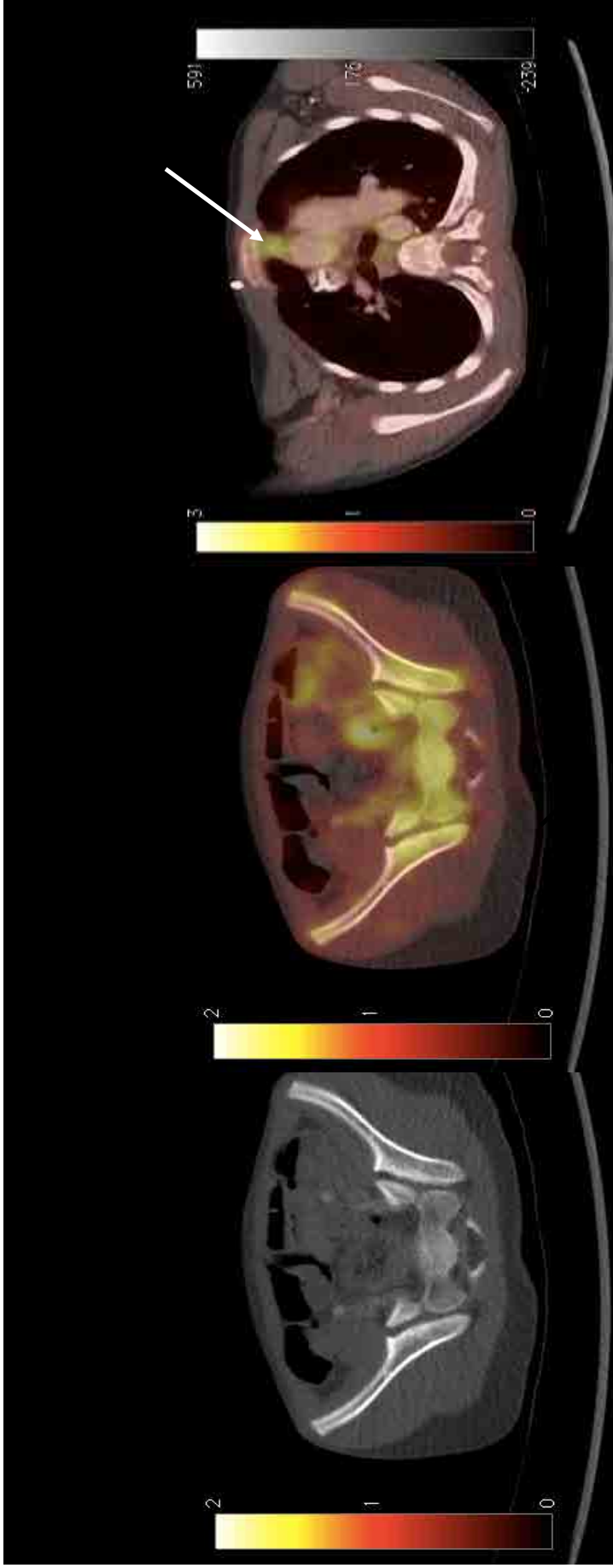
Impression: Sacral mass and soft tissue FDG avid lesion. FDG avid mediastinal, pulmonary and pleural metastatic disease.

Follow-up

Tissue biopsy and subsequent treatment. ChTx with palliative intent.

Consequences of the current PET/CT examination reported here

No change in treatment plan.



Ewing's Sarcoma

14 y/o M patient with newly diagnosed metastatic solid tumour representing Ewing's sarcoma of the sacrum with pulmonary metastatic disease. FDG-PET/CT requested for initial staging.

Heterogeneous FDG uptake in partially destructive sacral mass with anterior soft tissue component. Metastatic chest disease with anterior mediastinal mass.

21.2. CASE NO. PAED 2

Study type:	Oncology	Clinical indication:	Neuroblastoma
Clinical indication for PET/CT:	Initial staging		
Keywords:	Paediatric oncology Neuroblastoma Multiple metastases		
PET/CT system:	GE Discovery	Tracer:	FDG
Uptake:	71 min	Dose:	311 MBq
Range:	WB	Blood glucose:	5.3 mmol/L
No. beds:	6	Min/bed:	1
Tube loading:	80 mAs	Tube voltage:	120 kVp

Short clinical history

A 14 year old female patient with a biopsy proven SBRCT with osseous and soft tissue abnormalities. FDG–PET/CT scan was requested for initial staging.

PET/CT findings

FDG–PET/CT shows multiple sites of abnormal activity. Focal abnormality in the right forearm, known osseous abnormality around the olecranon and proximal ulna. LN involvement in medial right arm towards axilla. Large soft tissue mass arising from the lateral aspect of the right kidney. Additional FDG avid masses in the left kidney and next to the right kidney. Small right normal size iliac LN with low grade FDG avidity.

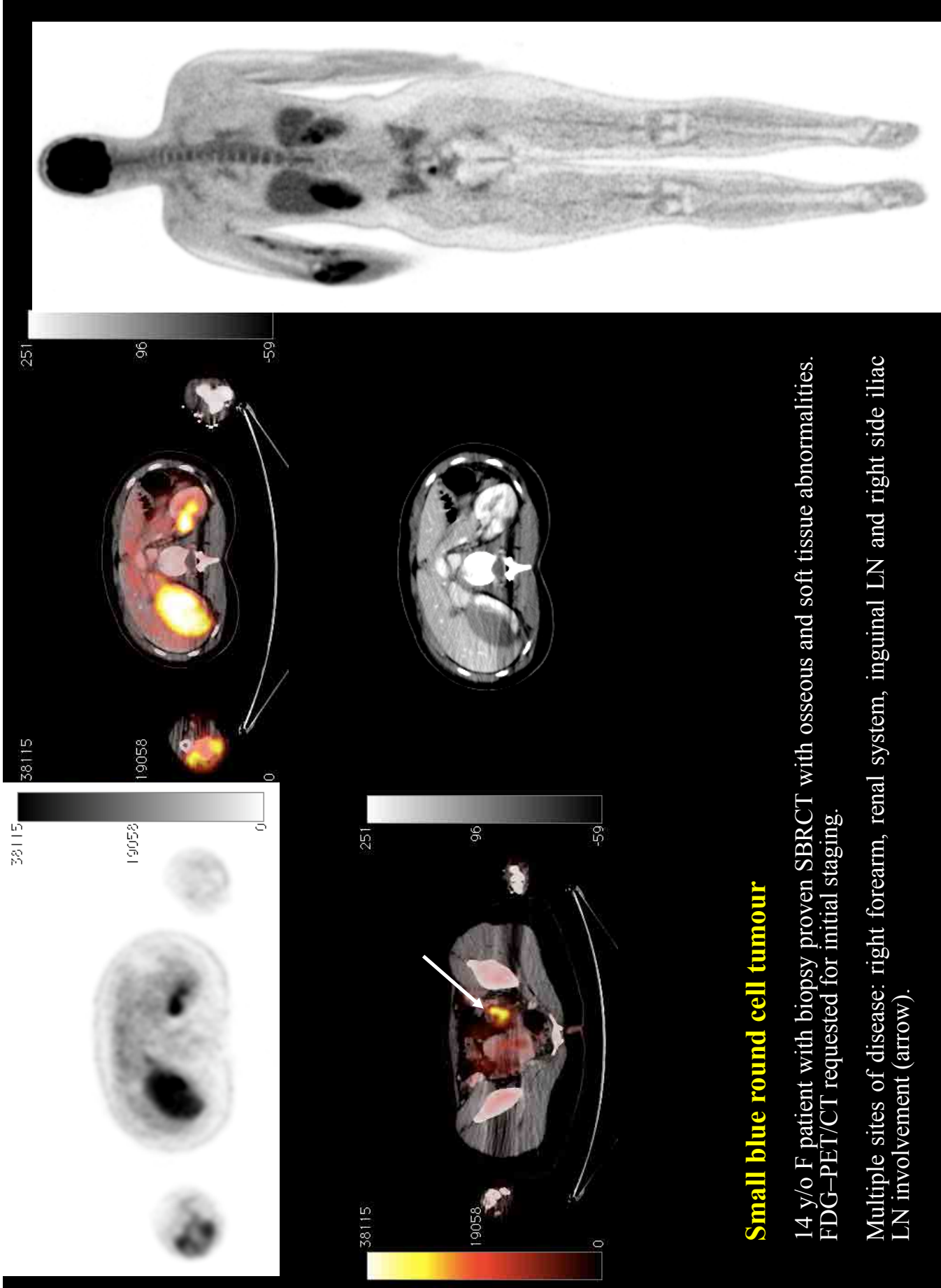
Impression: Multiple sites of disease involving right kidney, osseous lesions and the right forearm and LN involvement.

Follow-up

Tissue biopsy and subsequent treatment. ChTx with curative intent.

Consequences of the current PET/CT examination reported here

No change in treatment plan.



Small blue round cell tumour

14 y/o F patient with biopsy proven SBRCT with osseous and soft tissue abnormalities. FDG-PET/CT requested for initial staging.

Multiple sites of disease: right forearm, renal system, inguinal LN and right side iliac LN involvement (arrow).

21.3. CASE NO. PAED 3

Study type:	Oncology	Clinical indication:	Hepatoblastoma
Clinical indication for PET/CT:	Initial staging		
Keywords:	Paediatric oncology Hepatoblastoma Multiple metastases		
PET/CT system:	GE Discovery	Tracer:	FDG
Uptake:	76 min	Dose:	418 MBq
Range:	WB	Blood glucose:	4.8 mmol/L
No. beds:	7	Min/bed:	1
Tube loading:	60 mAs	Tube voltage:	80 kVp

Short clinical history

A 14 year old female patient with hepatoblastoma. An FDG–PET/CT scan was requested for initial staging.

PET/CT findings

FDG–PET/CT shows diffuse widespread abnormal FDG avidity involving multiple liver segments. Some photopenia in the central part of the right lobe of the liver corresponding to tumour necrosis. Most hypermetabolic regions correspond to morphologically detectable lesions on the CT image.

Diffuse abnormal osseous involvement in the mid/lower thoracic and lower lumbosacral spine with altered bone density on the CT image. Hypermetabolic abnormal FDG positive lesions seen also diffusely in the lung corresponding to pulmonary nodules. Several soft tissue FDG avid lesions. Few areas in the brain show mild prominent FDG activity (right parietal and left frontal).

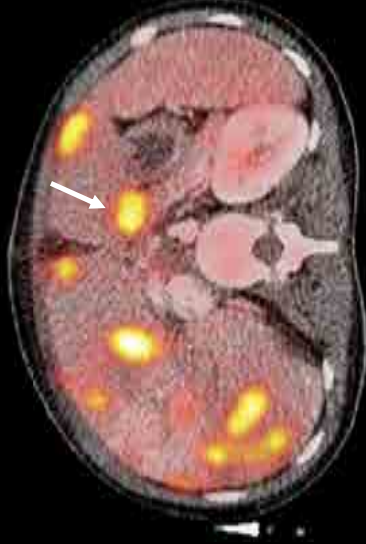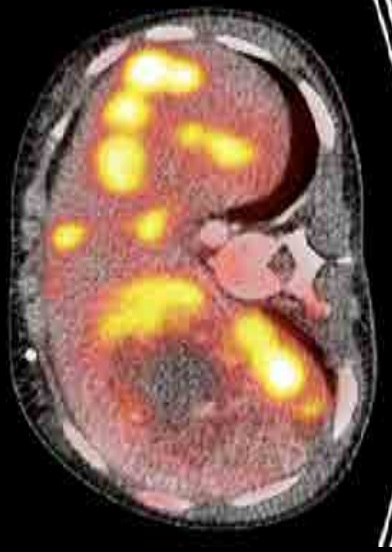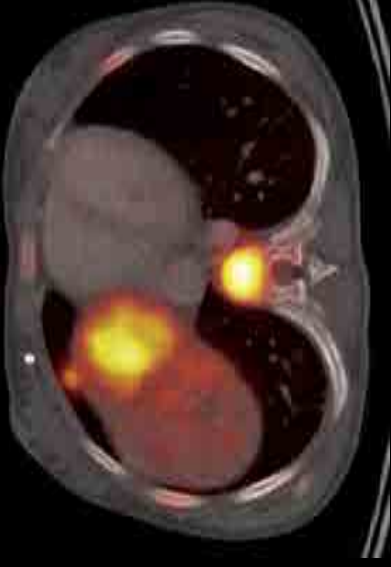
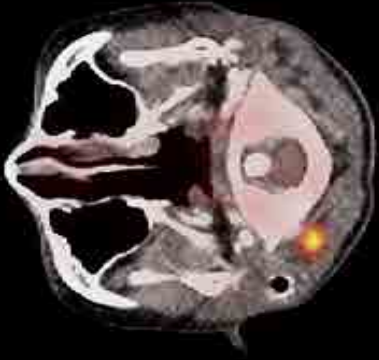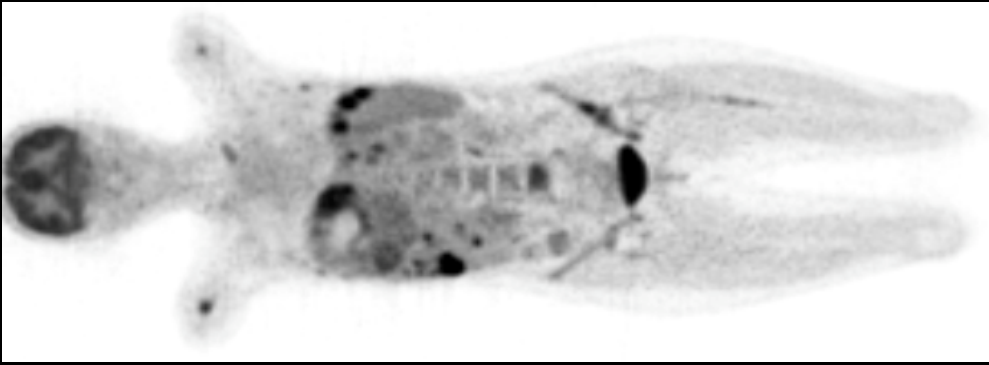
Impression: Diffusely metastasised hepatoblastoma.

Follow-up

Tissue biopsy and subsequent treatment. ChTx with curative intent.

Consequences of the current PET/CT examination reported here

No change in treatment plan.



Hepatoblastoma

14 y/o F patient with hepatoblastoma. FDG-PET/CT requested for initial staging.

Extensive hypermetabolic foci of disease in the liver, thoracic and lumbar spine, subcutaneous right occipital area and in the pancreas (arrow).

21.4. CASE NO. PAED 4

Study type:	Oncology	Clinical indication:	Neuroblastoma
Clinical indication for PET/CT:	Initial staging		
Keywords:	Paediatric oncology Neuroblastoma		
PET/CT system:	GE Discovery	Tracer:	FDG
Uptake:	60 min	Dose:	119 MBq
Range:	WB	Blood glucose:	4.8 mmol/L
No. beds:	6	Min/bed:	1
Tube loading:	60 mAs	Tube voltage:	80 kVp

Short clinical history

A 6 year old male patient with neuroblastoma stage IV. MIBG-SPECT requested 1 month earlier, shows focal uptake in the right ileum.

PET/CT findings

FDG–PET/CT for confirmation assessment shows focal abnormal FDG avidity in the right iliac bone with a size larger than that on MIBG. One prominent LN with FDG accumulation in the right posterior jugular area of the upper neck. No abnormal FDG activity within the adrenal or lungs.

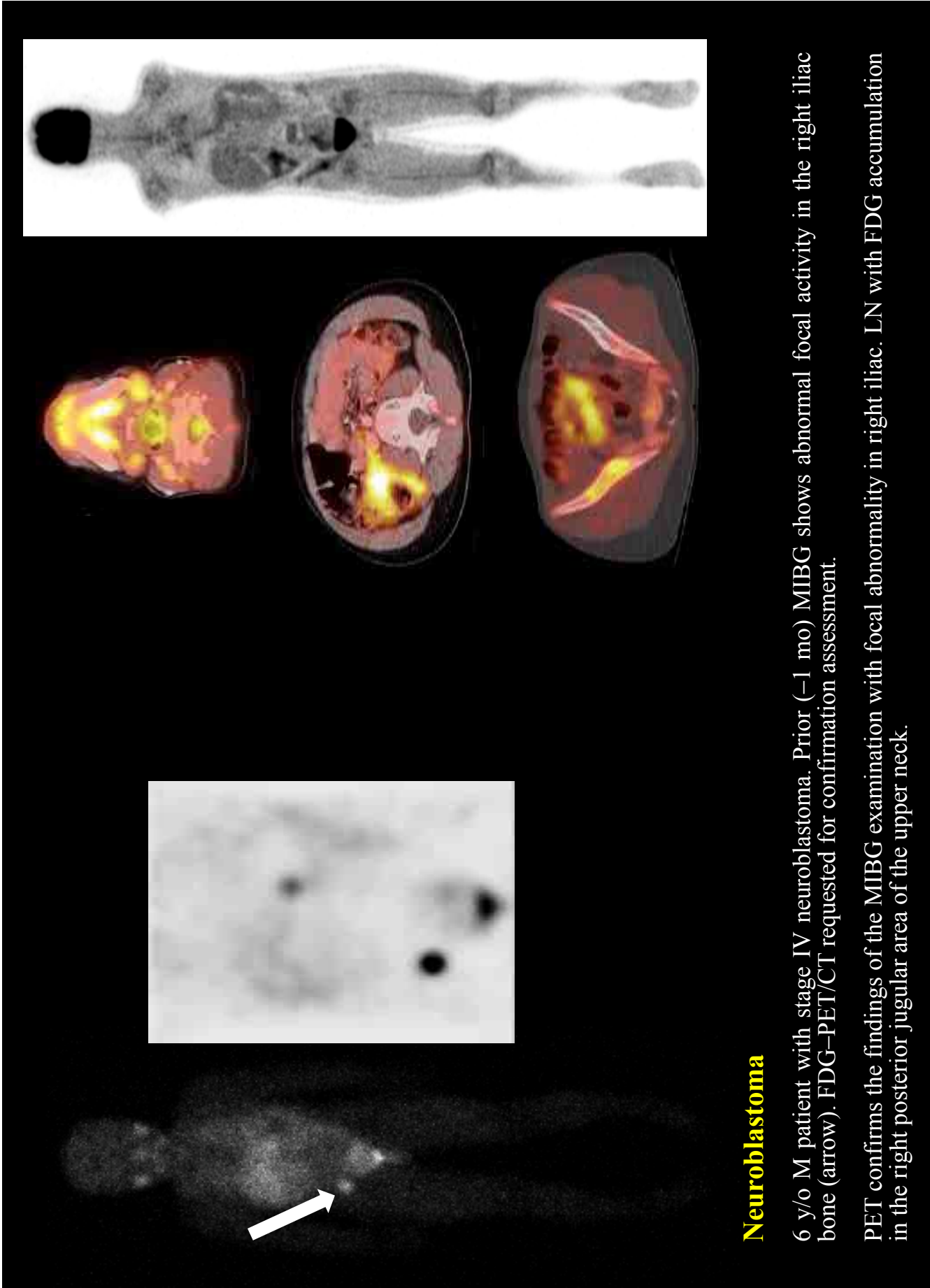
Impression: Evidence of disease progression.

Follow-up

Surgery and ChTxRT with curative intent.

Consequences of the current PET/CT examination reported here

Upstage of disease and change in treatment plan.



Neuroblastoma

6 y/o M patient with stage IV neuroblastoma. Prior (-1 mo) MIBG shows abnormal focal activity in the right iliac bone (arrow). FDG-PET/CT requested for confirmation assessment.

PET confirms the findings of the MIBG examination with focal abnormality in right iliac. LN with FDG accumulation in the right posterior jugular area of the upper neck.

21.5. CASE NO. PAED 5

Study type:	Oncology	Clinical indication:	Lymphoma
Clinical indication for PET/CT:	Initial staging		
Keywords:	Paediatric oncology Lymphoma Brain manifestation		
PET/CT system:	GE Discovery	Tracer:	FDG
Uptake:	60 min	Dose:	119 MBq
Range:	WB	Blood glucose:	4.8 mmol/L
No. beds:	4	Min/bed:	1
Tube loading:	100 mAs	Tube voltage:	100 kVp

Short clinical history

A 30 month old female patient with suspected lymphoma. An FDG–PET/CT scan was requested for staging purposes.

PET/CT findings

FDG–PET/CT shows large FDG avid soft tissue mass originating from and focally infiltrating the right calvarial frontal bone associated with a large soft tissue mass. Additional sites of abnormal FDG accumulation associated with bone destruction of the skull base and numerous small foci of permeative bone destruction. Elsewhere, additional abnormal FDG accumulation involving multiple other osseous sites. Slightly inhomogeneous FDG accumulation in the spleen.

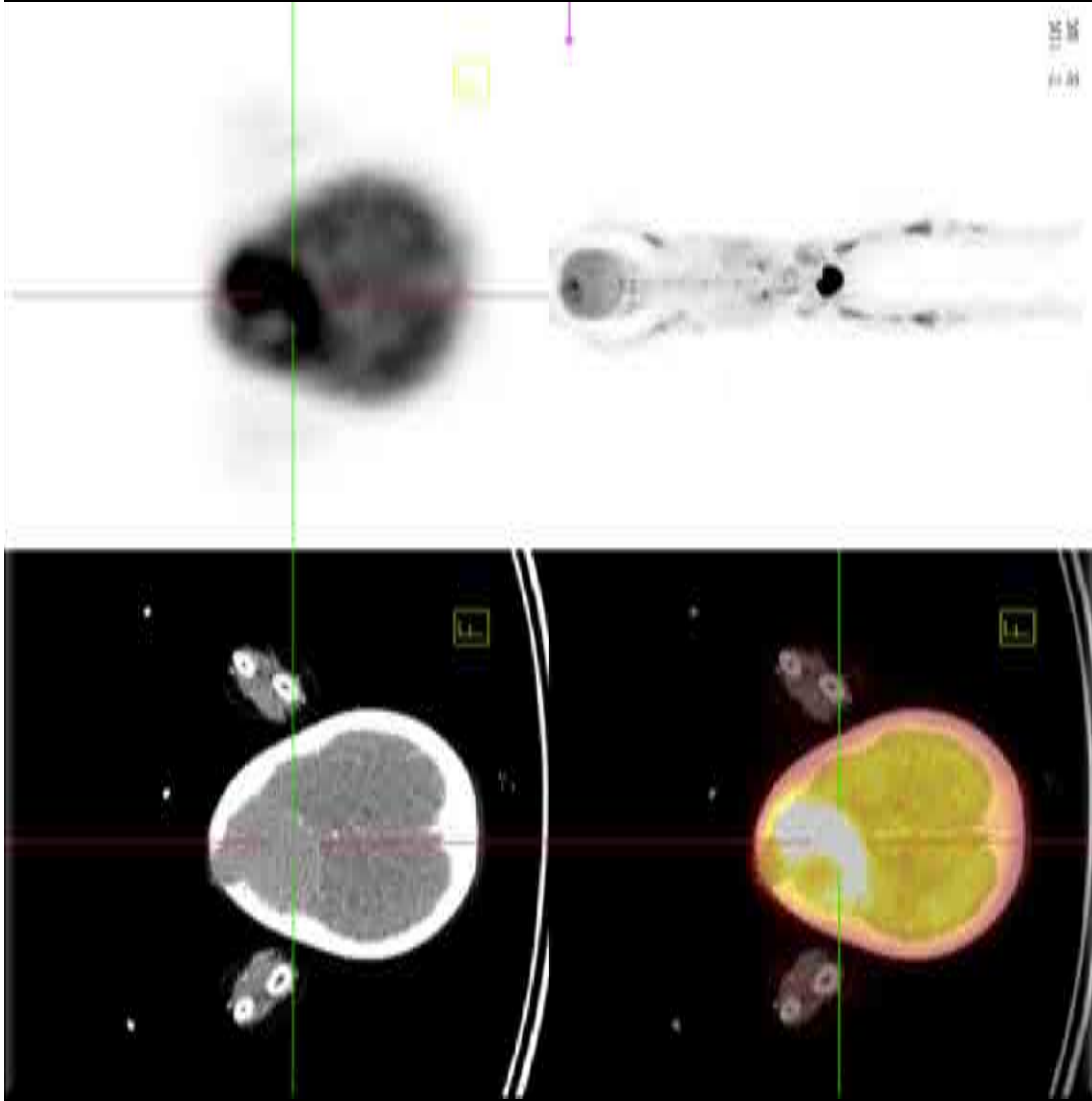
Impression: Multiple osseous, hepatic and splenic lymphoma manifestations as well as frontal brain manifestation.

Follow-up

ChTxRT with curative intent.

Consequences of the current PET/CT examination reported here

Upstage of disease and change in treatment plan.



Lymphoma

30 mo F patient with suspected lymphoma. FDG–PET/CT requested for staging.

Numerous sites of intense FDG accumulation associated with permeative bone destruction. Additional FDG avid soft tissue mass arising from the right calvarial frontal bone up to a depth of 3 cm intracranially. Brain MRI follow-up.

21.6. CASE NO. PAED 6

Study type:	Oncology	Clinical indication:	LCH
Clinical indication for PET/CT:	Suspected recurrence		
Keywords:	Paediatric oncology LCH		
PET/CT system:	GE Discovery	Tracer:	FDG
Uptake:	58 min	Dose:	56 MBq
Range:	WB	Blood glucose:	4.8 mmol/L
No. beds:	4	Min/bed:	1
Tube loading:	60 mAs	Tube voltage:	80 kVp

Short clinical history

A 2 year old female patient with relapse/refractory LCH. An FDG–PET/CT scan was requested for restaging purposes.

PET/CT findings

Intense FDG accumulation with osseous destruction centred at base of left pterygoid plates with associated soft tissue mass with elevated FDG accumulation. Milder degree of FDG accumulation in known left frontal and high right parietal skull vault lesions. Mild FDG uptake in the left neck LNs. Slightly increased activity in L1, Th10 and Th8 vertebrae.

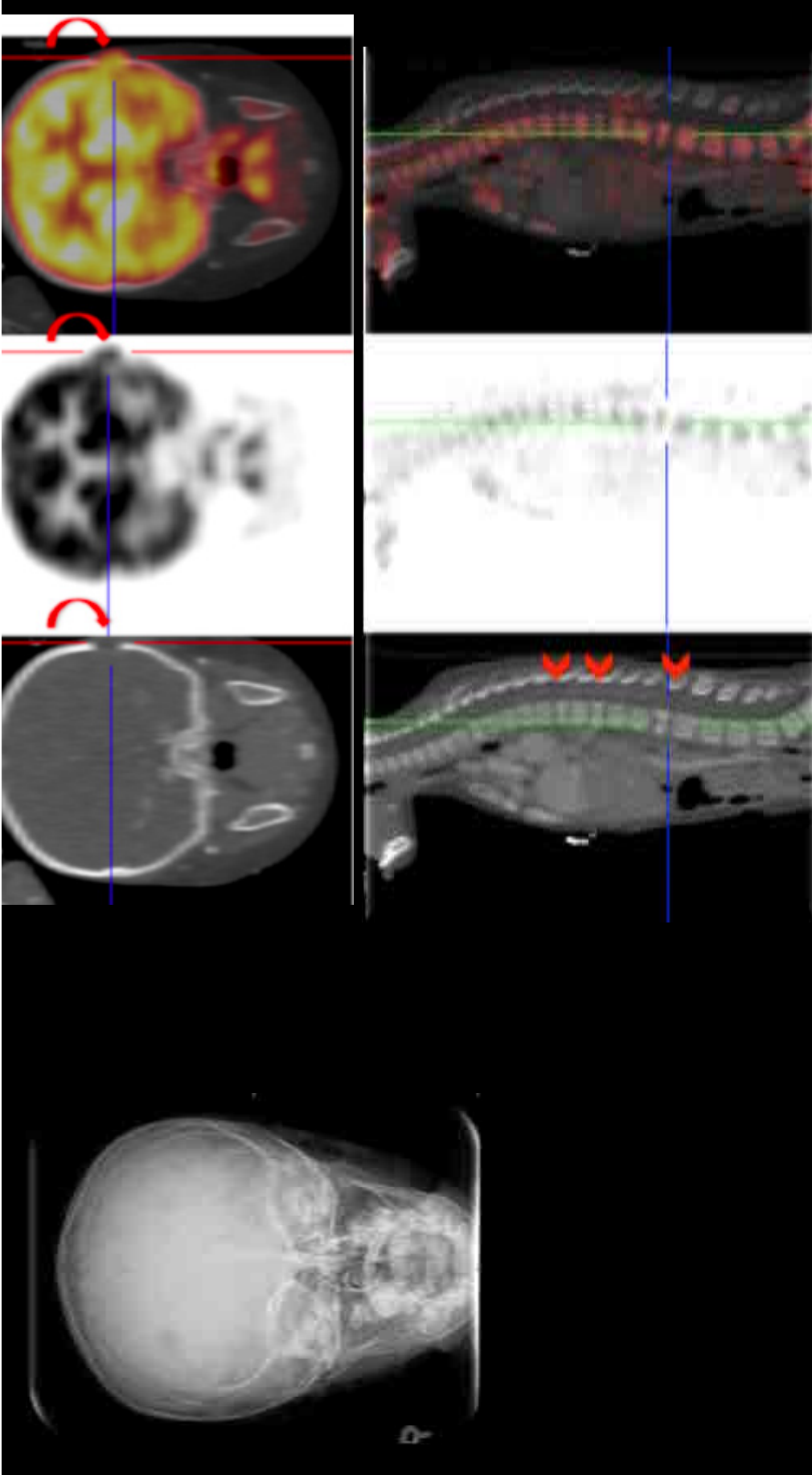
Impression: Multiple metabolically active destructive skull lesions. Numerous lytic lesions throughout the skeleton. Bilateral mildly hypermetabolic lymphadenopathy.

Follow-up

ChTxRT with curative intent.

Consequences of the current PET/CT examination reported here

Unknown.



Langerhans cell histiocytosis

2 y/o F patient with refractory LCH. FDG-PET/CT requested for restaging.

Metabolically active, destructive skull lesions. LN involvement in the neck.

Numerous lytic lesions throughout the skeleton.

21.7. CASE NO. PAED 7

Study type:	Oncology	Clinical indication:	Adrenocortical cancer
Clinical indication for PET/CT:	Initial staging		
Keywords:	Paediatric oncology Multiple metastases Adrenocortical cancer		
PET/CT system:	GE Discovery	Tracer:	FDG
Uptake:	60 min	Dose:	292 MBq
Range:	WB	Blood glucose:	5.3 mmol/L
No. beds:	6	Min/bed:	1
Tube loading:	60 mAs	Tube voltage:	80 kVp

Short clinical history

A 10 year old female patient with newly diagnosed adrenocortical cancer with liver and pulmonary metastases. An FDG–PET/CT scan was requested for staging purposes.

PET/CT findings

Extensive FDG avidity seen in the left side of the abdomen correlating with a left adrenal mass (irregular FDG uptake with a central absence of uptake), extending from the left upper quadrant to the level of the left pelvis, 20 cm in length. In addition, multiple FDG avid lesions seen within the liver (mainly right lobe) and lungs.

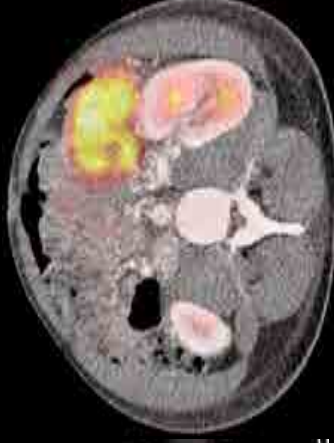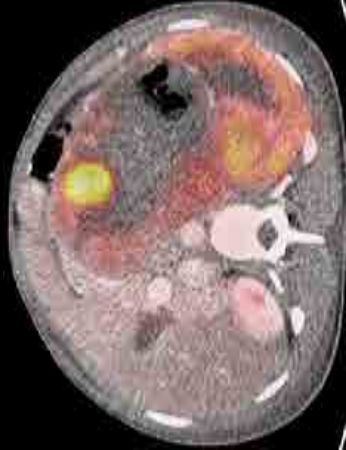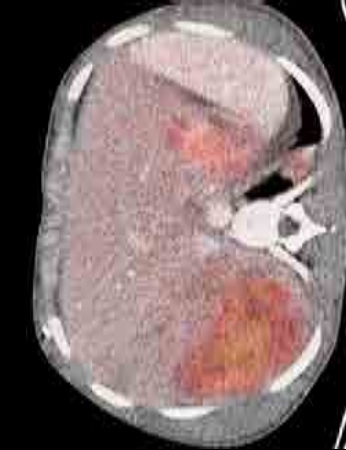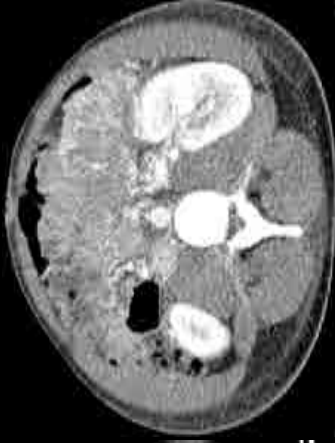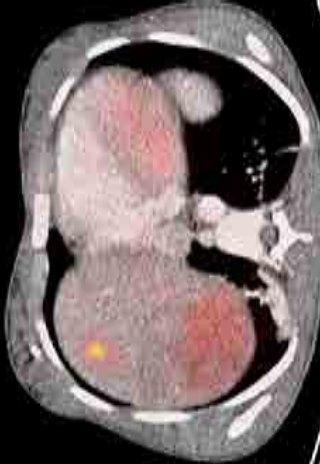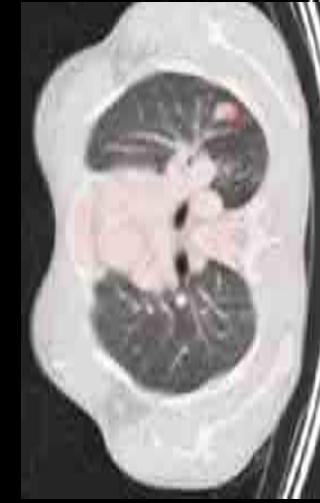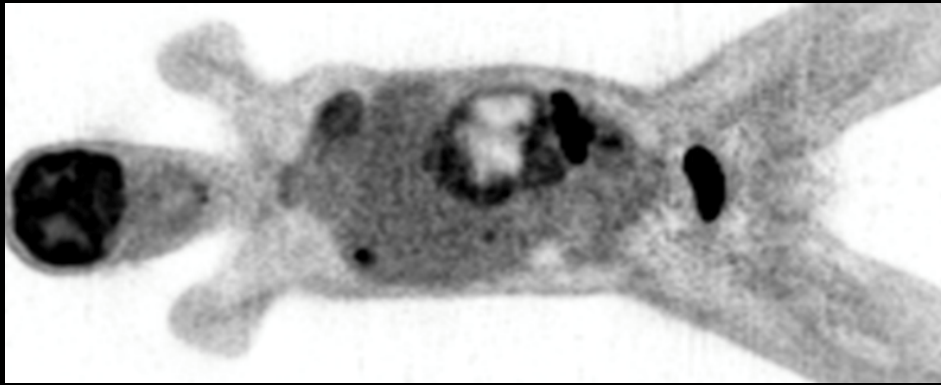
Impression: Extensive lobulated mixed FDG avid mass corresponding to left adrenal mass displacing most of the abdominal viscera and multiple distant metastases.

Follow-up

ChTxRT with curative intent.

Consequences of the current PET/CT examination reported here

Upstage of disease and change in treatment plan.



Adrenocortical cancer

10 y/o F patient with newly diagnosed adrenocortical cancer. FDG-PET/CT requested for staging.

Extensive lobulated mixed FDG avid mass corresponding to left adrenal mass displacing most of the abdominal viscera and multiple distant metastases to the lungs and liver.

21.8. CASE NO. PAED 8

Study type:	Oncology	Clinical indication:	Sarcoma
Clinical indication for PET/CT:	Initial staging		
Keywords:	Paediatric oncology Sarcoma Staging		
PET/CT system:	GE Discovery	Tracer:	FDG
Uptake:	60 min	Dose:	354 MBq
Range:	WB	Blood glucose:	5.0 mmol/L
No. beds:	10	Min/bed:	1
Tube loading:	40 mAs	Tube voltage:	80 kVp

Short clinical history

A 16 year old female patient with sarcoma at the distal right femur. An FDG–PET/CT scan was requested for staging purposes.

PET/CT findings

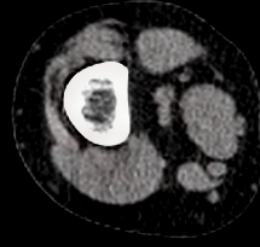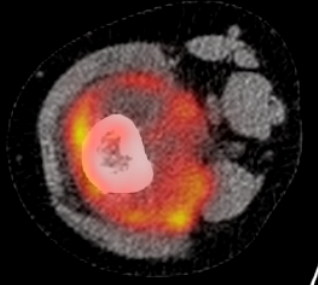
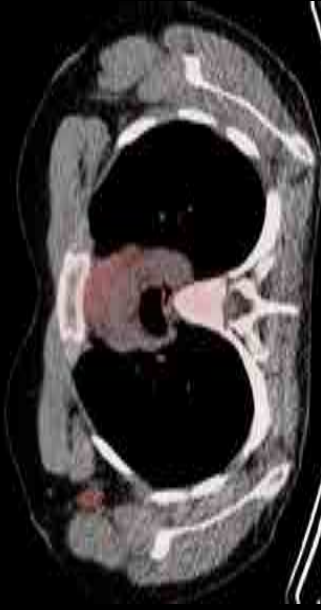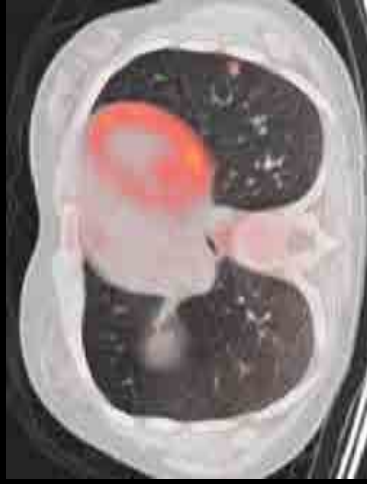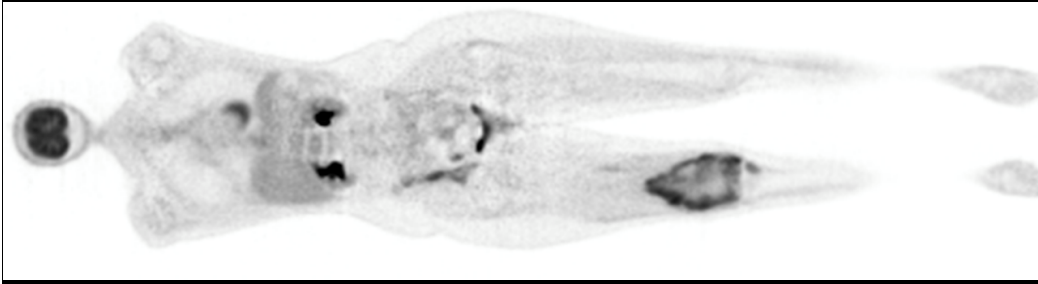
Multiple abnormal FDG avid distal right femoral tumour with avid metastatic disease involving numerous osseous sites, LNs and pulmonary lesions. Probably Ewing's Sarcoma.

Follow-up

Surgery and ChTxRT with palliative intent.

Consequences of the current PET/CT examination reported here

Upstage of disease and change in treatment plan.



Sarcoma

16 y/o girl with sarcoma of the distal right femur. FDG-PET/CT requested for staging.

FDG avid distal right femoral tumour with avid metastatic disease involving numerous osseous sites, LNs and pulmonary nodules.

21.9. CASE NO. PAED 9

Study type:	Oncology	Clinical indication:	PTLD
Clinical indication for PET/CT:	Initial staging		
Keywords:	Paediatric oncology Sarcoma		
PET/CT system:	GE Discovery	Tracer:	FDG
Uptake:	60 min	Dose:	354 MBq
Range:	WB	Blood glucose:	5.0 mmol/L
No. beds:	10	Min/bed:	1
Tube loading:	40 mAs	Tube voltage:	80 kVp

Short clinical history

A 16 year old male patient with sarcoma at the distal right femur. An FDG–PET/CT scan was requested for staging.

PET/CT findings

Multiple abnormal FDG avid metastases. Most FDG avid region of radiotracer uptake is within the distal right femur (distal femur and surrounding soft tissue). Numerous additional osseous sites of radiotracer uptake identified: tibial and pelvic. Three FDG avid LNs and numerous pulmonary nodules.

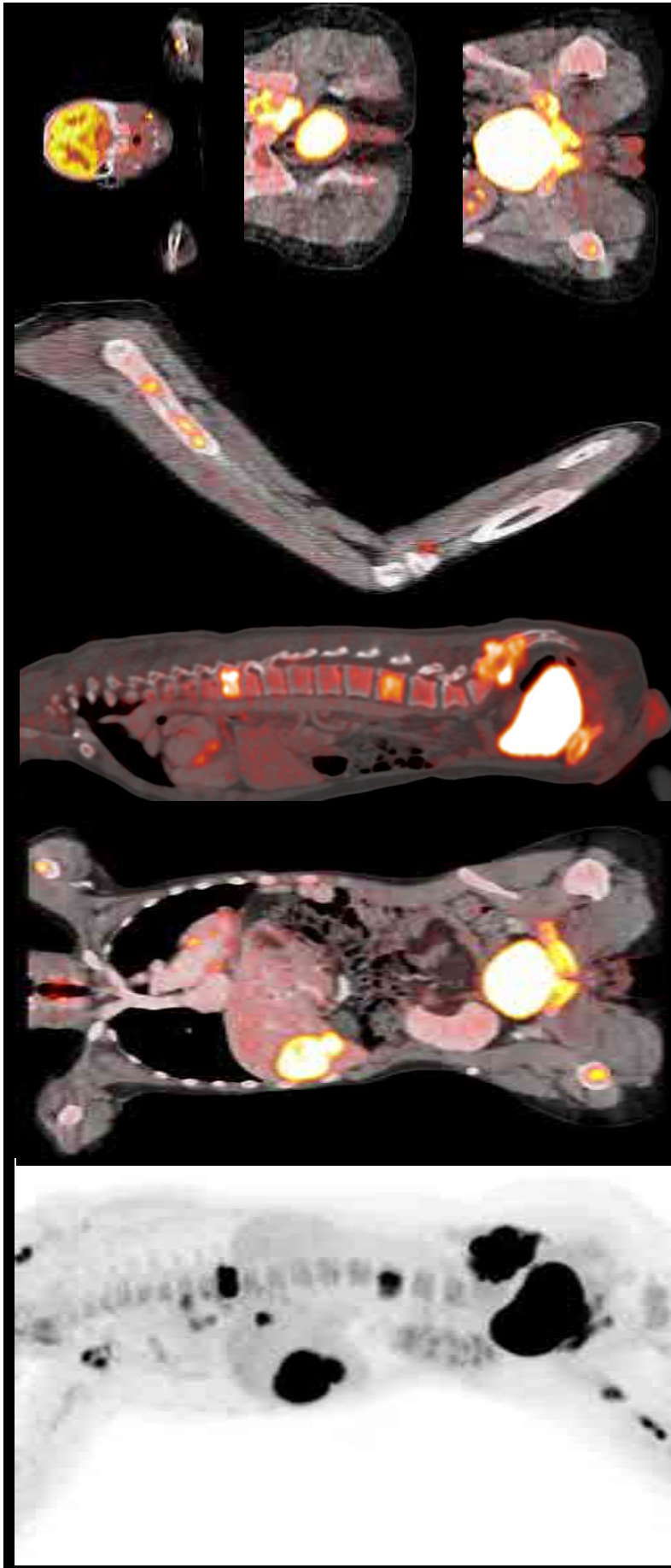
Impression: FDG avid distal right femoral tumour with avid metastatic disease involving numerous osseous sites, LNs and pulmonary lesions. Probably Ewing’s sarcoma.

Follow-up

Surgery and ChTxRT with palliative intent.

Consequences of the current PET/CT examination reported here

Upstage of disease and change in treatment plan.



Lymphoma/Post-transplant lymphoproliferative disease

16 y/o M patient with renal Tx presents with weight loss and pain. Sacral mass on MRI. FDG-PET/CT requested for staging.

Extensive FDG soft tissue mass in left iliac fossa and presacral area with extensive osseous involvement. Additional involvement of the liver. Uptake pattern consistent with lymphoma on a background of PTLTD.

21.10. CASE NO. PAED 10

Study type:	Oncology	Clinical indication:	Sarcoma
Clinical indication for PET/CT:	Initial staging		
Keywords:	Paediatric oncology Multiple metastases Sarcoma		
PET/CT system:	GE Discovery	Tracer:	FDG
Uptake:	69 min	Dose:	298 MBq
Range:	WB	Blood glucose:	5.6 mmol/L
No. beds:	12	Min/bed:	1
Tube loading:	80 mAs	Tube voltage:	120 kVp

Short clinical history

A 16 year old female patient with newly diagnosed rhabdomyosarcoma and cord compression. An FDG–PET/CT scan was requested for staging.

PET/CT findings

Multiple foci of FDG avidity can be seen associated with LNs (neck, chest, abdomen and pelvis). Abnormal soft tissue mass with increased FDG avidity in paravertebral location at multiple levels in the thoracic region. Heterogeneous FDG avidity in the majority of osseous structures, including the proximal humeri, scapulae, majority of the spine, pelvis, femora and proximal tibia.

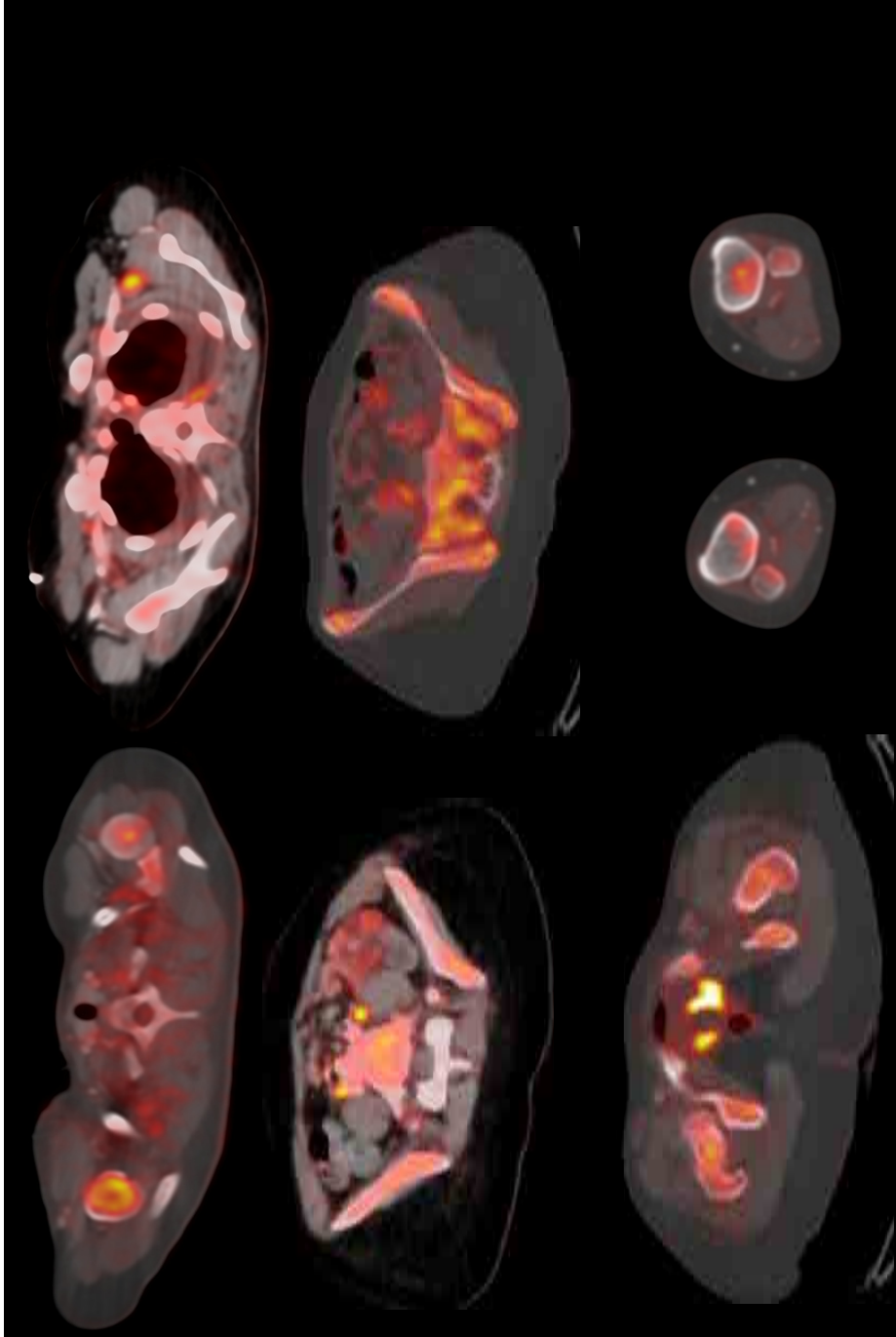
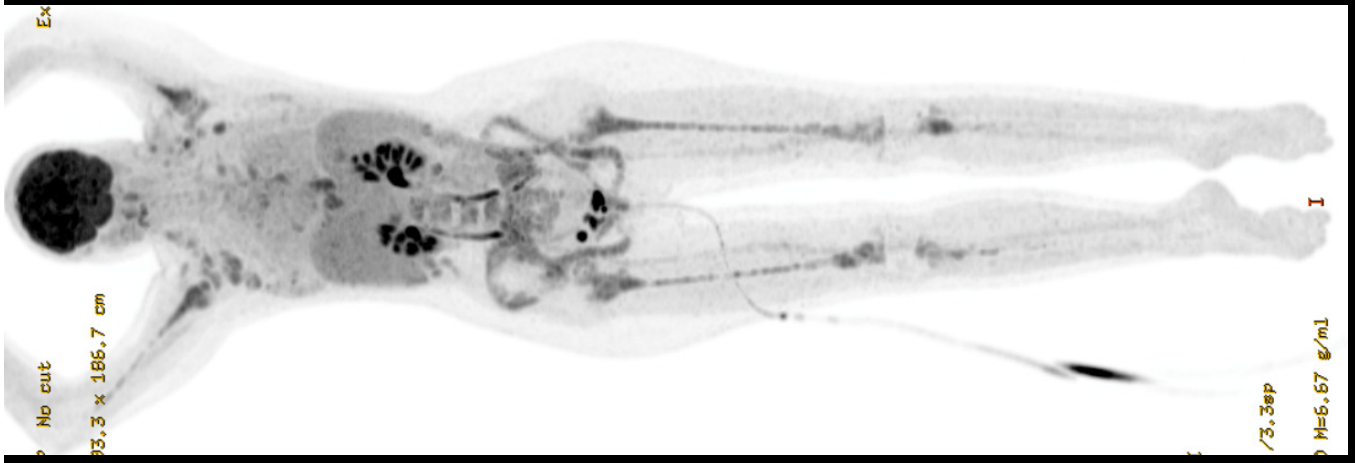
Impression: Multiple LNs within neck, chest and abdomen with increased FDG avidity. Bone marrow appears diffusely involved. No primary lesion is noted. Large bilateral pleural effusion.

Follow-up

ChTxRT with palliative intent.

Consequences of the current PET/CT examination reported here

Upstage of disease and change in treatment plan.



Rhabdomyosarcoma

16 y/o F patient with newly diagnosed alveolar rhabdomyosarcoma and cord compression. FDG-PET/CT requested for staging.

Multiple LNs in the neck, chest and abdomen with increased FDG avidity. Diffuse FDG uptake in bone marrow.

Study type:	Oncology	Clinical indication:	Sarcoma
Clinical indication for PET/CT:	Restaging		
Keywords:	Paediatric oncology Osseous metastases LN metastases Sarcoma Treatment response		
PET/CT system:	GE Discovery	Tracer:	FDG
Uptake:	64 min	Dose:	298 MBq
Range:	WB	Blood glucose:	5.6 mmol/L
No. beds:	12	Min/bed:	1
Tube loading:	80 mAs	Tube voltage:	100 kVp

Short clinical history

A 12 year old female patient with liposarcoma of the left chest s/p 7 cycles ChTx and resection. CT shows residual mass. FDG–PET/CT scan requested for restaging.

PET/CT findings

Soft tissue mass extending from left hilum to left main pulmonary artery into the lower chest with increased FDG avidity. In addition, two adjacent areas show increased FDG uptake, corresponding to soft tissue masses.

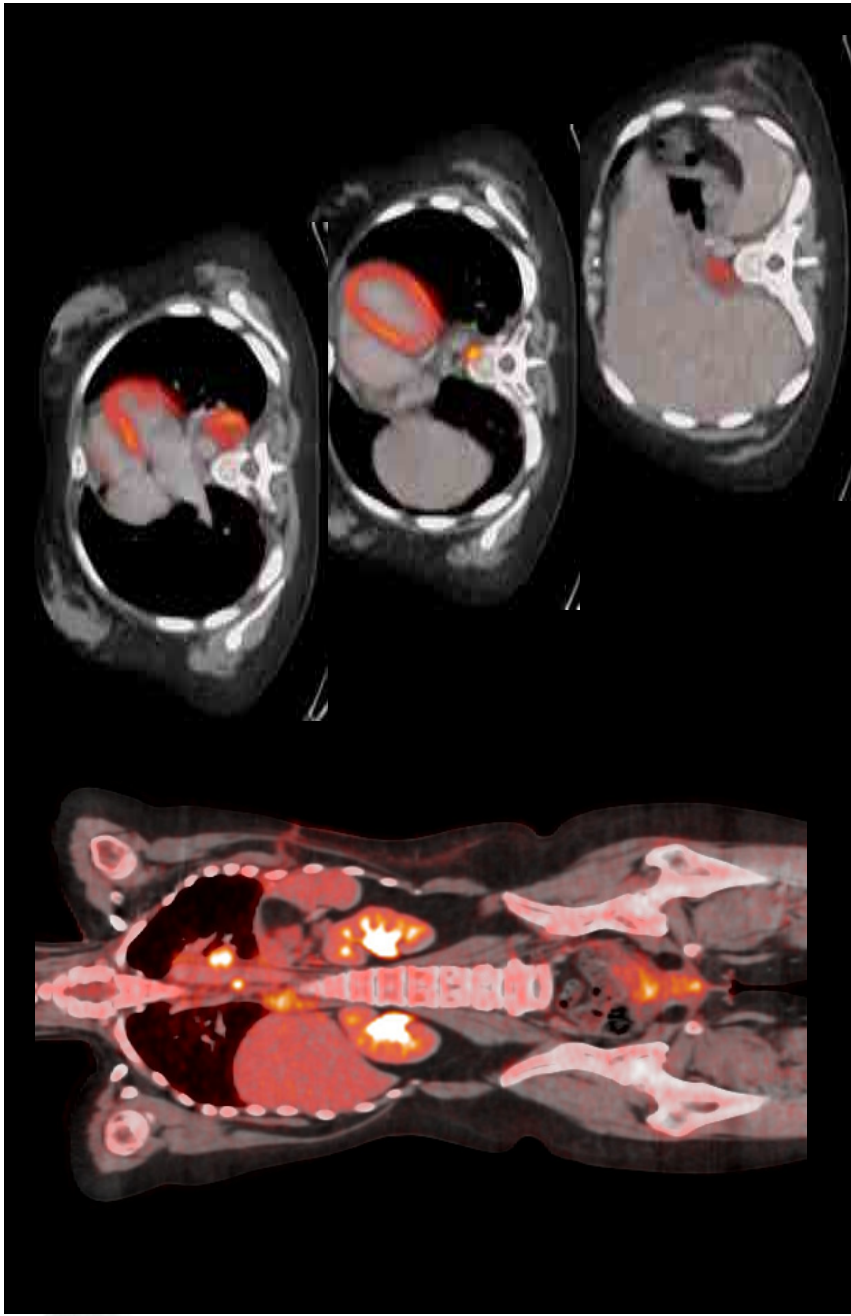
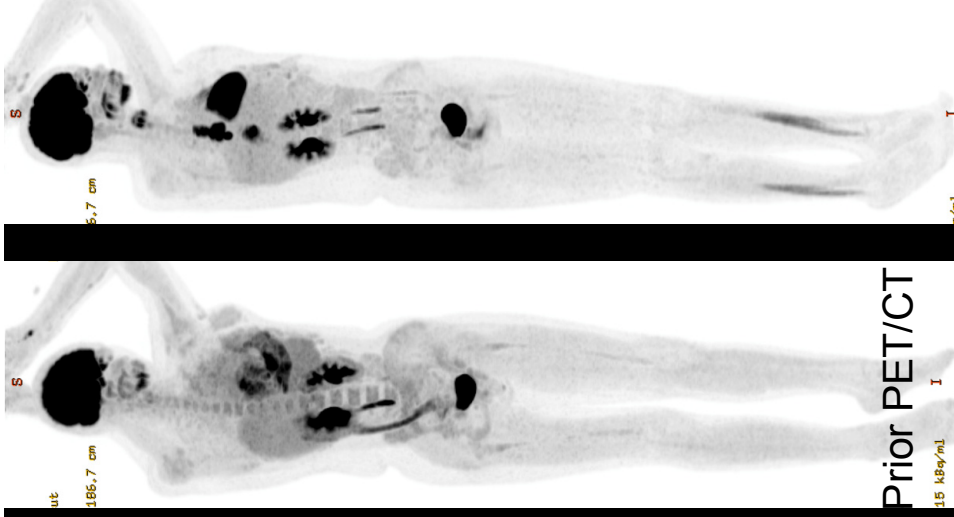
Impression: Disease progression in residual masses and new metastases in retrocrural location and lower thorax.

Follow-up

ChTxRT with palliative intent.

Consequences of the current PET/CT examination reported here

Upstage of disease and change in treatment plan.



Liposarcoma

12 y/o F patient with liposarcoma of the left chest s/p 7 cycles ChTx and resection. CT shows residual mass. FDG-PET/CT requested for restaging.

Prior PET/CT (-4 mo): FDG avidity in posteromedial aspect of the left chest. Follow-up PET/CT shows new soft tissue disease in retrocrural location and lower mid-thorax likely due to disease progression.

ABBREVIATIONS

ACC	adenoid cystic carcinoma
AJCC	American Joint Committee on Cancer
ALND	axillary lymph node dissection
ASCT	autologous stem cell transplant
¹¹ C-MET	¹¹ C-methionine
CA	cancer
CCC	cholangiocellular carcinoma
CEA	carcinoembryonic antigen
CECT	contrast enhanced computed tomography
ChTx	chemotherapy treatment
CMR	complete metabolic response
COPD	chronic obstructive pulmonary disease
CT	computed tomography
CUP	cancer of unknown primary
DCIS	ductal carcinoma in situ
DLBCL	diffuse large B cell lymphoma
DSA	digital subtraction angiography
DTC	differentiated thyroid cancer
ELF ChTx	etoposide, leucovorin and fluorouracil chemotherapy treatment
ENT	ear, nose and throat
F	female
FDG	¹⁸ F-fluorodeoxyglucose
FNAC	fine needle aspiration cytology
GIST	gastrointestinal stromal tumour
HCC	hepatocellular carcinoma
HD	Hodgkin's disease
HER2	human epidermal growth factor receptor type 2
IDC	invasive ductal carcinoma
IV	intravenous
LAD	lymphadenectomy
LCH	Langerhans cell histiocytosis
LHRH	luteinizing hormone-releasing hormone
LN	lymph node
M	male
MCL	mantle cell lymphoma
MIBG	metaiodobenzylguanidine
mo	month
MRI	magnetic resonance imaging
NET	neuroendocrine tumour
NHL	non-Hodgkin's lymphoma
NSCLC	non-small cell lung cancer
PET	positron emission tomography
pi	post-injection
PMR	partial metabolic response
PR	partial response
PSA	prostate-specific antigen
PTLD	post-transplant lymphoproliferative disease
PTX	pneumothorax
R-CHOP	rituximab, cyclophosphamide, doxorubicin (hydroxydaunorubicin), vincristine (Oncovin) and prednisone (chemotherapy regimen)

R-Hyper-CVAD	rituximab hyper central venous access devices
R-IGEV	rituximab, ifosfamide, gemcitabine and vinorelbine (chemotherapy regimen)
RTx	radiation therapy treatment
SBRCT	small, blue, round cell tumour
SCC	squamous cell carcinoma
s/p	status post
SPN	solitary pulmonary nodule
SSTR	somatostatin receptor
TBB	transbronchial biopsy
TBLB	transbronchial lung biopsy
Tg	thyroglobulin
TLB	thoracoscopic lung biopsy
TOF	time of flight
Tx	treatment
WB	whole body
WHO II	World Health Organization grade 2
w/o	without
y	year
y/o	year old

CONTRIBUTORS TO DRAFTING AND REVIEW

Barta, Z.	Institute of Nuclear Medicine, University of Debrecen, Hungary
Beyer, T.	University of Duisburg-Essen, Germany
El-Haj, N.	International Atomic Energy Agency
Freudenberg, L.S.	University of Duisburg-Essen, Germany
Núñez Miller, R.	International Atomic Energy Agency
Paez, D.	International Atomic Energy Agency
Veit-Haibach, P.	Nuclear Medicine, University Hospital Zurich, Switzerland



IAEA

International Atomic Energy Agency

No. 24

ORDERING LOCALLY

In the following countries, IAEA priced publications may be purchased from the sources listed below or from major local booksellers.

Orders for unpriced publications should be made directly to the IAEA. The contact details are given at the end of this list.

BELGIUM

Jean de Lannoy

Avenue du Roi 202, 1190 Brussels, BELGIUM

Telephone: +32 2 5384 308 • Fax: +32 2 5380 841

Email: jean.de.lannoy@euronet.be • Web site: <http://www.jean-de-lannoy.be>

CANADA

Renouf Publishing Co. Ltd.

22-1010 Polytek Street, Ottawa, ON K1J 9J1, CANADA

Telephone: +1 613 745 2665 • Fax: +1 643 745 7660

Email: order@renoufbooks.com • Web site: <http://www.renoufbooks.com>

Bernan Associates

4501 Forbes Blvd., Suite 200, Lanham, MD 20706-4391, USA

Telephone: +1 800 865 3457 • Fax: +1 800 865 3450

Email: orders@bernan.com • Web site: <http://www.bernan.com>

CZECH REPUBLIC

Suweco CZ, s.r.o.

SESTUPNÁ 153/11, 162 00 Prague 6, CZECH REPUBLIC

Telephone: +420 242 459 205 • Fax: +420 284 821 646

Email: nakup@suweco.cz • Web site: <http://www.suweco.cz>

FRANCE

Form-Edit

5 rue Janssen, PO Box 25, 75921 Paris CEDEX, FRANCE

Telephone: +33 1 42 01 49 49 • Fax: +33 1 42 01 90 90

Email: fabien.boucard@formedit.fr • Web site: <http://www.formedit.fr>

Lavoisier SAS

14 rue de Provigny, 94236 Cachan CEDEX, FRANCE

Telephone: +33 1 47 40 67 00 • Fax: +33 1 47 40 67 02

Email: livres@lavoisier.fr • Web site: <http://www.lavoisier.fr>

L'Appel du livre

99 rue de Charonne, 75011 Paris, FRANCE

Telephone: +33 1 43 07 43 43 • Fax: +33 1 43 07 50 80

Email: livres@appeldulivre.fr • Web site: <http://www.appeldulivre.fr>

GERMANY

Goethe Buchhandlung Teubig GmbH

Schweitzer Fachinformationen

Willstätterstrasse 15, 40549 Düsseldorf, GERMANY

Telephone: +49 (0) 211 49 874 015 • Fax: +49 (0) 211 49 874 28

Email: s.dehaan@schweitzer-online.de • Web site: <http://www.goethebuch.de>

HUNGARY

Librotrade Ltd., Book Import

Pesti ut 237. 1173 Budapest, HUNGARY

Telephone: +36 1 254-0-269 • Fax: +36 1 254-0-274

Email: books@librotrade.hu • Web site: <http://www.librotrade.hu>

INDIA

Allied Publishers

1st Floor, Dubash House, 15, J.N. Heredi Marg, Ballard Estate, Mumbai 400001, INDIA

Telephone: +91 22 4212 6930/31/69 • Fax: +91 22 2261 7928

Email: alliedpl@vsnl.com • Web site: <http://www.alliedpublishers.com>

Bookwell

3/79 Nirankari, Delhi 110009, INDIA

Telephone: +91 11 2760 1283/4536

Email: bkwell@nde.vsnl.net.in • Web site: <http://www.bookwellindia.com>

ITALY

Libreria Scientifica "AEIOU"

Via Vincenzo Maria Coronelli 6, 20146 Milan, ITALY

Telephone: +39 02 48 95 45 52 • Fax: +39 02 48 95 45 48

Email: info@libreriaaeiou.eu • Web site: <http://www.libreriaaeiou.eu>

JAPAN

Maruzen Co., Ltd.

1-9-18 Kaigan, Minato-ku, Tokyo 105-0022, JAPAN

Telephone: +81 3 6367 6047 • Fax: +81 3 6367 6160

Email: journal@maruzen.co.jp • Web site: <http://maruzen.co.jp>

RUSSIAN FEDERATION

Scientific and Engineering Centre for Nuclear and Radiation Safety

107140, Moscow, Malaya Krasnoselskaya st. 2/8, bld. 5, RUSSIAN FEDERATION

Telephone: +7 499 264 00 03 • Fax: +7 499 264 28 59

Email: secnrs@secnrs.ru • Web site: <http://www.secnrs.ru>

UNITED KINGDOM

The Stationery Office Ltd. (TSO)

St. Crispins House, Duke Street, Norwich, NR3 1PD, UNITED KINGDOM

Telephone: +44 (0) 333 202 5070

Email: customer.services@tso.co.uk • Web site: <http://www.tso.co.uk>

UNITED STATES OF AMERICA

Bernan Associates

4501 Forbes Blvd., Suite 200, Lanham, MD 20706-4391, USA

Telephone: +1 800 865 3457 • Fax: +1 800 865 3450

Email: orders@bernan.com • Web site: <http://www.bernan.com>

Renouf Publishing Co. Ltd.

812 Proctor Avenue, Ogdensburg, NY 13669-2205, USA

Telephone: +1 888 551 7470 • Fax: +1 888 551 7471

Email: orders@renoufbooks.com • Web site: <http://www.renoufbooks.com>

Orders for both priced and unpriced publications may be addressed directly to:

IAEA Publishing Section, Marketing and Sales Unit

International Atomic Energy Agency

Vienna International Centre, PO Box 100, 1400 Vienna, Austria

Telephone: +43 1 2600 22529 or 22530 • Fax: +43 1 2600 29302

Email: sales.publications@iaea.org • Web site: <http://www.iaea.org/books>



IAEA

International Atomic Energy Agency

RELATED PUBLICATIONS

QUALITY ASSURANCE FOR PET AND PET/CT SYSTEMS

IAEA Human Health Series No. 1

STI/PUB/1393 (145 pp.; 2009)

ISBN 978-92-0-103609-4

Price: €32.00

PLANNING A CLINICAL PET CENTRE

IAEA Human Health Series No. 11

STI/PUB/1457 (146 pp.; 2010)

ISBN 978-92-0-104610-9

Price: €42.00

STANDARD OPERATING PROCEDURES FOR PET/CT: A PRACTICAL APPROACH FOR USE IN ADULT ONCOLOGY

IAEA Human Health Series No. 26

STI/PUB/1616 (116 pp.; 2013)

ISBN 978-92-0-143710-5

Price: €35.00

QUANTITATIVE NUCLEAR MEDICINE IMAGING: CONCEPTS, REQUIREMENTS AND METHODS

IAEA Human Health Reports No. 9

STI/PUB/1605 (59 pp.; 2014)

ISBN 978-92-0-141510-3

Price: €33.00

Integrated positron emission tomography and computed tomography (PET/CT) has evolved since its introduction into the commercial market in 2001 into a major imaging procedure, particularly in oncological imaging. In clinical routine service, PET/CT has shown a significant impact on diagnosis, treatment planning, staging, therapy and the monitoring of treatment response, and has played an important role in the care of cancer patients. The high sensitivity from the PET component and the specificity of the CT component give this hybrid imaging modality the unique characteristics that make PET/CT one of the fastest growing imaging modalities, even 14 years after its clinical introduction.

This PET/CT atlas combines nearly one hundred comprehensive cases covering all major indications of FDG-PET/CT as well as some cases of clinically relevant special tracers. The cases provide an overview of what the specific disease can look like in PET/CT, the typical pattern of the disease's spread, as well as common pitfalls and teaching points. This PET/CT atlas will be of help to all professionals working with and interested in PET/CT imaging. It contains a variety of oncological imaging and provides clinically relevant teaching files on the effectiveness and diagnostic quality of FDG-PET/CT imaging in routine applications.

IAEA HUMAN HEALTH SERIES